



SoR

THE SOCIETY OF
RADIOGRAPHERS

BMUS

Guidelines for Professional Ultrasound Practice

Society of Radiographers and British Medical Ultrasound Society

**Ninth edition
December 2025
ISBN: 978-1-911738-25-1**

SOCIETY OF RADIOGRAPHERS (SoR) AND BRITISH MEDICAL ULTRASOUND SOCIETY (BMUS)

Guidelines for Professional Ultrasound Practice

Ninth edition, December 2025

Contents

Foreword to the December 2015 edition.....	4
Rationale and terminology used within the document.....	5
Publication history – summary	7
SECTION 1: Introduction.....	8
1.1 Explanation of the professional title ‘sonographer’	8
1.2 Registration for sonographers	10
1.2.1 Professional Standards Authority report on sonographer regulation	10
1.3 Profession vs tool	11
1.4 Screening examinations using ultrasound	12
SECTION 2: Governance and safety	15
2.1 Code of Practice for Sonographers	15
2.2 Professional indemnity	17
2.3 Medico-legal issues	17
2.4 Clinical governance	18
2.5 The 6 Cs, patient identification, communication and consent	20
2.6 Intimate examinations and chaperones	23
2.7 Professional responsibilities and safeguarding.....	24
2.7.1 Safeguarding	24
2.7.2 Raising concerns.....	24
2.7.3 Female genital mutilation (FGM) – statutory requirements of practitioners.....	25
2.7.4 Duty of candour	25
2.7.5 Conscientious objection.....	26
2.8 Safety of medical ultrasound	26
2.9 Ultrasound equipment and quality assurance testing.....	28
2.10 Transducer and equipment cleaning and disinfection.....	28
2.10.1 Ultrasound gel.....	30
2.10.1 Ultrasound probe covers.....	31
2.11 Examination times	31
2.12 Ergonomic practice, including high body mass index (BMI)	33

2.13	Acquisition, archiving and use of ultrasound data	33
2.14	Recording of images by patients during examinations.....	35
2.15	'Have you paused and checked': posters and prompt cards	35
2.16	Independent practice.....	36
SECTION 3: Education and accreditation		39
3.1	Education and training.....	39
3.2	eLearning for Healthcare	39
3.3	Quality Standard for Imaging (QSI)	40
3.4	Continuing professional development (CPD).....	41
3.5	Levels of practice	42
3.6	Audit, learning events and learning meetings	43
3.7	Preceptorship and capability development.....	48
SECTION 4: Introduction to the ultrasound examination		49
4.1	Overview of ultrasound examination procedures	49
4.2	Vascular, echocardiography and breast examinations	50
4.3	NICE and other guidelines.....	50
4.4	Vetting, justification and authorisation of ultrasound requests.....	51
4.5	Recommendations for the production of an ultrasound report.....	53
SECTION 5: Ultrasound clinical examinations		61
5.1	Gynaecological ultrasound examinations.....	61
5.1.1	Common clinical scenarios.....	63
5.1.2	Pelvic ultrasound reporting examples	70
5.2	Abdominal ultrasound examinations	71
5.2.1	Reporting examples	72
5.2.2	The liver.....	73
5.2.2.1	Common clinical scenarios.....	74
5.2.2.2	Liver ultrasound reporting examples	77
5.2.3	The gallbladder and biliary tree	78
5.2.4	The pancreas	81
5.2.4.1	Common clinical scenarios.....	82
5.2.5	The spleen	83
5.2.5.1	Common clinical scenarios.....	84
5.2.6	Abdominal aorta	86
5.2.7	Urinary tract, scrotum and penis	88
5.2.7.1	The kidneys	88
5.2.7.1.1	Common clinical scenarios.....	90
5.2.7.1.2	Renal ultrasound reporting examples.....	92
5.2.7.2	The testes and scrotum.....	94

5.2.7.2.1	Common clinical scenarios.....	94
5.2.7.3	The penis.....	97
5.2.7.4	The prostate gland.....	97
5.2.7.4.1	Common clinical scenarios.....	98
5.2.8	The bowel.....	99
5.2.8.1	Common clinical scenarios.....	102
5.2.8.2	Bowel ultrasound reporting examples.....	103
5.2.9	Adult ‘lumps and bumps’	105
5.2.9.1	Common clinical scenarios.....	108
5.2.9.2	‘Lumps and bumps’ ultrasound reporting examples	114
5.3	Paediatric ultrasound examinations.....	115
5.3.1	Paediatric liver and biliary tree	116
5.3.2	Paediatric urinary system	119
5.3.3	Paediatric gastrointestinal tract.....	122
5.3.3.1	Common clinical scenarios.....	122
5.3.4	Paediatric neck lumps	123
5.3.5	Neonatal hip.....	124
5.3.6	Neonatal intracranial	126
5.4	Head and neck ultrasound examinations	128
5.4.1	Common clinical scenarios.....	130
5.4.2	Fine needle aspiration (FNA)/core biopsy	132
5.4.3	Head and neck ultrasound reporting examples.....	132
5.5	Musculoskeletal ultrasound examinations	134
5.5.1	Shoulder	137
5.5.2	Elbow.....	141
5.5.3	Hand and wrist	143
5.5.4	Adult hip.....	145
5.5.5	Knee	148
5.5.6	Foot and ankle.....	150
5.6	Rheumatology ultrasound examinations	152
5.6.1	Common clinical scenarios.....	156
5.6.2	Rheumatology ultrasound reporting examples	159
5.7	Obstetric ultrasound examinations.....	160
5.7.1	Early pregnancy ultrasound	161
5.7.2	First trimester screening	167
5.7.3	Second trimester ultrasound	168
5.7.4	Third trimester ultrasound.....	168
5.7.5	Postpartum ultrasound	169

5.7.6	Multiple pregnancy	169
5.7.7	Obstetric ultrasound reporting examples	172
SECTION 6: Additional procedures		174
6.1	Elastography.....	174
6.1.1	Elastography reporting examples	177
6.2	Contrast-enhanced ultrasound (CEUS)	177
6.2.1	CEUS reporting examples.....	180
6.3	Interventional and ‘extended scope’ examinations for sonographers	181
6.4	Supplying, prescribing and administering medicines	182
6.4.1	Prescribing.....	183
6.4.2	Legal mechanisms	184
6.5	Artificial intelligence.....	185
Abbreviations and acronyms.....		187
Acknowledgements		191
Document history		193
Citation.....		193
Disclaimer.....		193

Foreword to the December 2015 edition

It is my pleasure to introduce the updated ‘Guidelines for Professional Ultrasound Practice’, in the past affectionately known to sonographers as the ‘UKAS Guidelines’. The United Kingdom Association of Sonographers (UKAS) was set up to support sonographers, provide advice and practice guidance and ultimately get sonography recognised as a profession in its own right. To this day the latter still remains a challenge! However, since the last edition of the Guidelines was produced in 2008, UKAS has merged with the Society of Radiographers (SoR), so, while UKAS no longer exists, its legacy lives on in this revised document. It is a testament to the quality of the original Guidelines that some sections are relatively unchanged. The advice is as equally sound and relevant today as it was then. Guidelines, however, need to keep in step with evolving technology, changes in practice and professional progression. For this reason, it was decided to produce the revised version as a web-based document that can be regularly updated, amended and expanded as and when required.

As with all previous editions, these Guidelines are not designed to be prescriptive but to inform good practice. May they continue to be used in departments across the United Kingdom for years to come.

Wendy Williams

Member, Ultrasound Advisory Group, Society and College of Radiographers

Former UKAS committee member

December 2015

Rationale and terminology used within the document

These current Guidelines are a collaboration between the Society of Radiographers (SoR) and the British Medical Ultrasound Society (BMUS). The format of a web-based document provides easier access to relevant sections and hyperlinks, while allowing for biennial updates. Some links within the Guidelines are to members-only SoR or BMUS content and may require additional log-in.

The document has been written to complement the 2014 joint document by the Royal College of Radiologists (RCR) and the Society and College of Radiographers (SCoR), [Standards for the provision of an ultrasound service](#). It provides guidance on topics that were not included in the joint RCR/SCoR Standards document and gives further detailed advice on some areas of practice that were.

There can be overlap between the terms ‘standards’, ‘guidelines’ and ‘protocols’, and this can cause confusion. For the purposes of this document, the definitions used are the same as those in the [2014 RCR and SCoR document](#).

Standard:

A required or agreed level of quality or attainment. A standard is a way of ensuring optimum levels of care or service delivery. Standards promote the likelihood of an ultrasound examination being delivered safely and effectively, are clear about what needs to be done to comply, are informed by an evidence base and are effectively measurable.

Guideline:

A general rule, principle or piece of advice. Guidelines provide recommendations on how ultrasound examinations should be performed and are based on best available evidence. They help ultrasound practitioners in their work but they do not replace their knowledge and skills.

Protocol:

An agreement, preferably based on research, between practitioners to ensure the delivery of high-quality standardised ultrasound examinations.

These non-prescriptive Guidelines serve as recommended best-practice references. Since the inaugural UKAS Guidelines for Professional Working Practice in 1993, advances in service delivery, technology, and patient expectations have reshaped medical ultrasound. The examination-specific sections ([ref: section 5](#)),—excluding obstetrics—were compiled by the BMUS Professional Standards Group as exemplars, enabling departments to develop their own local protocols where national standards are absent. The obstetric section, curated by the SoR, reflects contemporaneous best-evidence; given the rapid evolution of obstetric guidance, users should verify the latest guidance and evidence-based recommendations before making clinical decisions that impact patient outcomes. Additional sections cover general advice on reporting and audit. Extensive hyperlinks throughout the document provide direct access to numerous relevant publications from organisations beyond the SoR and BMUS.



As this is a ‘live’ document, changes made in recent editions have been highlighted with the year e.g. **[2025]**. If updates have taken place, these have been referred to as **[updated 2025]**.



These guidelines do not and cannot cover all elements of an ultrasound examination.

The guidelines should be used to help inform local policy and protocols in conjunction with national standards, other available evidence, local needs and risk assessment.

Basic guidelines are included for obstetric ultrasound and links made to other resources. **[2021]** The national fetal anomaly screening programmes provide comprehensive information about the screening programmes offered in the UK.

Practitioners are referred to publications from other sources such as the Royal College of Obstetricians and Gynaecologists (RCOG) (especially their Green-top Guidelines), the National Institute for Health and Care Excellence (NICE), the Fetal Medicine Foundation (FMF), the Association of Early Pregnancy Units (AEPU), the British Society of Gynaecological Imaging (BSGI) and the International Society of Ultrasound in Obstetrics and Gynaecology (ISUOG).

The term 'patient' has been used throughout the document in preference to other terms such as 'client' or 'service user'.

Several professional titles are used by those who practice ultrasound, and this can lead to considerable confusion. The term 'ultrasound practitioner' is used throughout this document when appropriate to do so. This is consistent with use of this term within the 2014 RCR/SCoR document [Standards for the provision of an ultrasound service](#), which uses the following definition:

Ultrasound practitioner:

A healthcare professional who holds recognised qualifications in medical ultrasound and is able to competently perform ultrasound examinations falling within their personal scope of practice. The professional background of ultrasound practitioners can be very varied and will include radiologists, radiographers, sonographers, midwives, physiotherapists, obstetricians and clinical scientists.

A definition of 'sonographer' that was used in connection with the [Public Voluntary Register of Sonographers \(PVRs\)](#), which was administered by the College of Radiographers (CoR) until March 2021, can be found in [section 1.2](#). **[2021]** This definition makes a distinction between those ultrasound practitioners who are registered with the General Medical Council (GMC) and those who are not. These Guidelines will be of relevance to all, hence the use of the term 'ultrasound practitioner' whenever possible.

Occasionally the term 'operator' is used. This term is defined within the Glossary of the 2014 RCR/SCoR [Standards for the provision of an ultrasound service](#) document as:

A generic term used for someone who uses ultrasound equipment. It does not imply that they hold recognised ultrasound qualifications as would an ultrasound practitioner.

It is the nature of any document, whether published in a traditional format or online, that it can very quickly become out of date. It is the intention of BMUS and the SoR that this document will be regularly updated, but it is the responsibility of the ultrasound practitioner to ensure that they research and apply the most up-to-date evidence in association with the contents of this document.

At the time of publication all hyperlinks have been checked and are complete. Please report any broken links to the following contact addresses:

- <https://www.sor.org/contact-us>
- <https://www.bmus.org/contact-us/>

Comments and feedback are also very welcome and will guide us in the further development of these Guidelines.

The SoR and BMUS would like to thank all who have contributed to this new online edition of what was previously the UKAS Guidelines (please see the [Acknowledgements](#) section).

We would also like to take this opportunity to again thank all the contributors and editors of previous editions of the Guidelines who have provided us with such a firm foundation on which to build.

Publication history – summary

SoR/BMUS Guidelines for Professional Ultrasound Practice.....	December 2015	Purple cover
Revision 1	December 2016	Pink cover
Revision 2	December 2017	Light blue cover
Revision 3	December 2018	Light green cover
Revision 3, minor amendments.....	March 2019	Light green cover
Revision 4	December 2019	Yellow cover
Revision 5	December 2020	Bright blue cover
Revision 6	December 2021	Lavender cover
Revision 7	December 2022	Lime green cover
Revision 8	December 2023	Orange cover
Revision 9	December 2025	Bright pink

From 2023 this document will move from annual to biennial revision. The next review is due in 2027.

SECTION 1: Introduction

1.1 Explanation of the professional title 'sonographer'

Wherever possible, the term 'ultrasound practitioner' will be used within this document. However, a full explanation of the term 'sonographer' will be helpful for context and is important in terms of professional recognition and recommended qualifications.

Sonographers are qualified healthcare professionals who undertake, analyse, interpret, report and take responsibility for the conduct of diagnostic, screening and interventional ultrasound examinations. Their individual scope of practice can be wide and varied. Sonographers also perform advanced diagnostic and therapeutic ultrasound procedures such as biopsies and joint injections. Sonographers are either not medically qualified or hold medical qualifications but are not registered as a doctor with a licence to practise with the GMC.

Definition

The following SoR definition of 'sonographer' was used in connection with the [PVRS](#) and is now used by the [Register of Clinical Technologists \(RCT\)](#). The definition was amended in 2018 to take into account proposed changes and additional ultrasound educational pathways.

A healthcare professional who undertakes and reports diagnostic, screening or interventional ultrasound examinations. They will hold qualifications equivalent to a Postgraduate Certificate or Diploma in Medical Ultrasound, BSc (Hons) clinical ultrasound or an honours degree apprenticeship that has been accredited by the Consortium for the Accreditation of Sonographic Education (CASE). They are either not medically qualified or hold medical qualifications but are not statutorily registered with the General Medical Council. ([RCT](#))

Entry routes into sonography

In addition to university-based postgraduate and undergraduate medical ultrasound programmes, an integrated [BSc \(Hons\) degree apprenticeship](#) pathway leading to qualification as a sonographer has now been developed by the Trailblazer group and approved for delivery by the Institute for Apprenticeships and Technical Education.

[2019]

The first CASE accredited BSc (Hons) integrated apprenticeship began in March 2023.

[2025]



Individuals without a recognised qualification, including student sonographers undertaking a CASE accredited programme, leading to competence, should always be supervised by qualified staff.

[Health Education England](#) (HEE) [now NHS England] has worked with a wide range of stakeholders (including the SoR and BMUS) to develop a career framework for sonography and to establish a number of educational routes, including pathways at undergraduate level. The stakeholders also developed the capability and preceptorship framework for sonographers.

It should be noted that statutory registration as, for example, a radiographer, nurse, midwife or doctor does not in itself mean that appropriate ultrasound qualifications are held.

[2018]

The SoR produced a poster [The role of the sonographer in ultrasound screening, diagnosis and treatment](#), which can be downloaded and displayed in departments and clinics.

[2025]

Registration vs membership

Membership of professional bodies such as the SoR or scientific organisations such as BMUS is separate to registration. There is general and widespread confusion between the terms 'membership' and 'registration'.

- A sonographer can be a *member* of the SoR and/or BMUS.
- They may be *statutorily registered* with the Health and Care Professions Council (HCPC), Nursing and Midwifery Council (NMC) or other statutory regulator.
- They may be *voluntarily registered* with the [RCT](#). [updated 2020]

The title 'Dr' is not a protected one and may refer to medical or academic awards obtained in the UK or overseas. Care does need to be taken not to unintentionally mislead a patient with respect to GMC registration being held when it is not. [2018]

For those sonographers coming to work in the UK from overseas whose first language is not English, the HCPC requirements for English proficiency can be found on the [HCPC website](#). The [RCT](#) follows similar requirements with respect to English language proficiency. [updated 2020]

Accreditation

- The [CASE website](#) has a list of accredited medical ultrasound programmes. CASE accredits programmes of education, but does not accredit individual sonographers. [2018]
- The [British Society of Echocardiography \(BSE\)](#) and [College and Society for Clinical Vascular Science \(CSVs\)](#) accredit individual ultrasound practitioners working within their respective specialties. [2018]
- NHS England's [Centre for Advancing Practice](#) offers the option to apply for a digital badge to recognise practitioners who can evidence their "advancing practice education, training and experience." Refer to [section 3.4](#). [2025]
- The CoR can provide accreditation of [practice educators](#) for sonographer members (SoR member log-in required).

A sonographer should:

- i) Recognise and work within their personal scope of practice, seeking advice as necessary
- ii) Ensure that a locally agreed and written scheme of work is in place
- iii) Work with reference to national and local practice and guideline recommendations
- iv) Ensure they hold appropriate professional indemnity insurance (PII) or obtain this by virtue of their employment ([ref: section 2.2](#))

Refer to [section 2.1](#) on the code of professional conduct for sonographers.

The general standards of education and training for ultrasound practitioners are set out on page 12 of the 2014 RCR and SCoR document [Standards for the provision of an ultrasound service](#).



CASE only accredits ultrasound programmes in the UK and Republic of Ireland.
CASE does not accredit individual ultrasound practitioners.

1.2 Registration for sonographers

This section uses the professional term ‘sonographer’ instead of the generic ‘ultrasound practitioner’ and refers to the long-running campaign to have sonography recognised as a profession and for the professional title of ‘sonographer’ to be legally protected.

The majority of sonographers **are** statutorily registered, but this will depend on their professional background and is not achievable for all. Statutory registration will most likely be as a radiographer or clinical scientist with the HCPC or as a midwife or nurse with the NMC and not as a sonographer, which is not a protected title.

For many sonographers, the only register available to them was the Public Voluntary Register of Sonographers (PVRs) administered and managed by the CoR. Following a report by the [Professional Standards Authority \(PSA\)](#) in July 2019 ([ref: section 1.2.1](#)), on 28 February 2021 the CoR closed the PVRs. The register transferred to the PSA-accredited [RCT](#). **[2021]**.

The HCPC provides guidance on its site about [Regulating further professions](#) and NHS Employers has advice on sonographer registration, on the site [Sonographers, sonography and the regulation of the medical ultrasound workforce](#).

The SoR has produced a document giving advice on [Ultrasound training, employment, registration and professional indemnity insurance \(2021\)](#) and BMUS has information on [How to become a sonographer](#), which includes working in the UK and qualifications.

For some sonographers working in areas of practice within the remit of the Academy for Healthcare Science (AHCS), statutory registration may be available either by following approved education and training routes as a clinical scientist or by being able to demonstrate ‘equivalence’. Statutory registration, if it is obtainable, will be with the HCPC as a clinical scientist. The AHCS also administers a [voluntary register](#) which is accredited by the [PSA](#).

The [Registration Council for Clinical Physiologists](#) runs a PSA-accredited voluntary register that is relevant for professionals specialising in echocardiography.



It is strongly recommended that sonographers register with either a statutory register, if they are able, or with the RCT.

1.2.1 Professional Standards Authority report on sonographer regulation

[2019]

As part of a major project involving the SoR, BMUS and a wide range of stakeholders to develop a new career structure for sonography, HEE commissioned the PSA to analyse the evidence available under the criteria outlined in the document [Right-touch assurance: a methodology for assessing and assuring occupational risk of harm](#) (2016) and to provide advice on the most appropriate form of assurance for the role. Evidence was presented to the PSA by the SoR, BMUS, RCR and CASE along with other interested parties in December 2018: [Evidence put forward for statutory registration of sonographers](#).

The PSA report [Right-touch assurance assessment for sonographers](#) was published in July 2019. The SoR, BMUS, RCR, CASE and other stakeholders were disappointed and concerned by the conclusions, which overturned the recommendations of the PSA’s own internal public advisory panel that had

been constituted for the review and had recommended statutory registration. Following its publication, they have been in contact with senior NHS and government officials to try and achieve statutory registration for all sonographers and recognition of title. This is both to protect the public and to allow the proposed HEE career structure for sonographers to be fully realised. Statutory registration for sonographers remains the policy of the SoR, BMUS, RCR and CASE.

In August 2024 the PSA published the Standard One assessment of the RCT [Decision on whether accreditation is in the public interest Register of Clinical Technologists \(RCT\)](#), which recommended the following: **[2025]**

The Accreditation Panel noted that the sonography risks appear sufficiently high to recommend that the UK Government should consider assessing the risk to determine whether voluntary registration is likely to be adequate. It is noted that the following information could help establish this.

- 1. Gathering data about the number of regulated and unregulated sonographers in the UK, both inside and outside the NHS, to inform understanding of the volume of risks.*
- 2. Understanding the extent to which the number of unregistered sonographers is growing, because this may pose a risk to the public if they are not held to the same standards as registered sonographers.*

1.3 Profession vs tool

There are many healthcare professionals working within the UK who use ultrasound as a 'tool' to assist with their overall treatment or evaluation of patients. There is published advice on education and training available to those who use ultrasound in this way but whose main work and role is not that of an ultrasound practitioner. For those who use the professional title of 'sonographer', ultrasound is their daily work and their primary profession. When used as a 'tool', ultrasound aids and assists a healthcare practitioner with their wider examination and treatment, but in overall terms, ultrasound is only a small part of their work. It is important for safe and effective service delivery that all ultrasound examinations are undertaken by appropriately trained and competent personnel and that there is associated audit and continuing professional development (CPD) in the use of ultrasound.

The following links provide further information about ultrasound education and standards:

- i) CASE-accredited focused courses can be found in the [Directory of CASE accredited courses](#) along with details of the [Standards for sonographic education](#).
- ii) RCR has published [Ultrasound training recommendations for medical and surgical specialities](#).
- iii) RCR and BMUS [Recommendations for specialists practising ultrasound independently of radiology departments: safety, governance and education](#) are available. **[2023]**

1.4 Screening examinations using ultrasound

The United Kingdom [National Screening Committee](#) (NSC) advises ministers in all four countries and resides within the Department of Health and Social Care.

Before any pathology or condition is accepted for national screening there is a full evaluation against the [NSC published criteria](#).

It should be noted that there may be variations in the screening programmes that operate across the four countries of the UK, and ultrasound practitioners should contact the relevant organisations for current advice.

- [Scotland](#)
- [Northern Ireland](#)
- [Wales](#)

In England, all public screening information is available on the NHS Choices website. Information for professionals is hosted on the [gov.uk website](#), and learning resources are on the eLearning for Healthcare (elfh) website, developed by HEE.



See additional resources on the [elfh site](#).
Free access for NHS staff and healthcare students in the UK.

The four national screening programmes of relevance to ultrasound practitioners are:

i) Antenatal screening

In England the NHS Fetal Anomaly Screening Programme (NHS FASP) is responsible for the two ultrasound scans that are offered to every pregnant woman in England. There are equivalent organisations to NHS FASP in the devolved countries, although the 11⁺² to 14⁺¹ week scan is not offered as a screening scan in Northern Ireland.

The two ultrasound scans for which NHS FASP (England) is responsible are the 11⁺² to 14⁺¹ week scan that includes the combined test for Trisomy 21, 13 and 18, and the 20 week screening scan, carried out between 18 and 20⁺⁶ weeks ([ref: section 5.7](#)).

[NHS FASP](#) has published comprehensive information for professionals in the document [NHS Fetal Anomaly Screening Programme Handbook](#) (2015, updated 2025). **[updated 2022]**

Equivalent organisations to NHS FASP in Scotland and Wales:

- Scotland: National Services Division: [Pregnancy Screening](#)
- Wales: [Antenatal Screening Wales](#)

Independent providers offering screening ultrasound scans to NHS patients during pregnancy must work within the published screening programme standards for the country in question.



See additional resources at [elfh - NHS Fetal Anomaly Screening Programme](#)

- Screening for Down's, Edwards' and Patau's syndromes
 - Fetal cardiac elearning
 - First-trimester screening resource for sonographers
 - 18⁺⁰ to 20⁺⁶ week fetal anomaly ultrasound scan
-

ii) NHS Abdominal Aortic Aneurysm (AAA) screening programme

The [AAA screening programme](#) has now successfully completed its roll-out across the UK.

Information on AAA screening in the devolved countries is available for:

- [Scotland](#)
- [Wales](#)
- [Northern Ireland](#)



See additional resources at: elfh – [NHS Abdominal Aortic Aneurysm \(AAA\) Screening Programme](#)

- AAA Clinical skills trainer elearning
 - AAA Screening technician elearning
-

iii) NHS breast screening programme

The [NHS breast screening programme \(BSP\)](#) website has resources relating to the programme and education. Although ultrasound is not part of the initial screening examination, specialists in breast ultrasound will use ultrasound techniques for further evaluation and biopsy.

iv) NHS newborn and infant physical examination (NIPE) screening programme

This national screening programme is responsible for issuing guidance and standards regarding the screening pathways for physical examination of newborns in England. There is currently no equivalent screening programme in the devolved countries.

- Guidance on when ultrasound examinations of the neonatal hip should be performed can be found on the website [Newborn and infant physical examination: programme handbook](#) (section 10.9).
- Standards for the NIPE programme can be found in the [Newborn and infant physical examination screening: standards](#) documentation.
- It is important to note that the neonatal hip ultrasound examination itself is a post-screening examination and is outside the direct remit of the NIPE screening programme.

Government advice on private screening for different conditions and diseases

Information outlining the advantages and disadvantages of screening outside the national programmes, along with information for healthcare professionals and patient information leaflets, can be found on the website [Private screening: important information](#).

Duty of candour guidance in the screening programmes

The NHS published a document [NHS screening programmes: duty of candour](#) in October 2016 ([ref: section 2.7.4](#)).

NHS population screening: education and training

The NHS England screening programmes provide links to educational resources and updated information in their [website](#).

SECTION 2: Governance and safety

2.1 Code of Practice for Sonographers

This code of practice has been included to support the use of the professional title of 'sonographer' and the future development and regulation of the sonography profession. Hence, this term is used rather than the generic 'ultrasound practitioner' ([ref: section 1.1](#)).

A code of practice can be defined as a set of written rules that explain how people working in a particular profession should behave. It is designed to cover all circumstances, is written in broad terms and expresses ethical principles.

The statements below are from the Code of Practice for Sonographers. They were previously published by UKAS in the *Guidelines for Professional Working Standards – Ultrasound Practice* (2008) and are equally relevant today.

These statements that reflect best practice are a guide and offer advice to sonographers, educationalists, students of medical ultrasound and other healthcare practitioners. They are statements of professional conduct that reflect the individual's rights, local and national changing patterns of ultrasound service delivery and the requirement of sonographers to demonstrate continuing competency through personal and professional development.

There are other codes that sonographers and ultrasound practitioners may need to follow. If they are statutorily registered with the GMC, HCPC or NMC, practitioners need to follow the codes of conduct and ethics published by these regulators. Professional bodies such as the SoR and the RCM have also published codes of professional conduct, for example the SoR [Code of Professional Conduct 2025](#) applies to all SoR members including sonographers from any background. **[2025]**

The RCT has a [Scope of Practice document](#) and CASE has [Standards of Proficiency for a Sonographer](#), which can be read in association with this code of practice. Additionally, there are National Occupational Standards for ultrasound ([CASE, Appendix 4](#)), which are relevant to anyone undertaking ultrasound examinations.

Code of Practice for Sonographers

[updated 2025]

1. Sonographers have a duty of care to their patients with respect to the minimisation of ultrasound exposure consistent with diagnostic needs.
2. Sonographers are ethically and legally obliged to hold in confidence any information acquired as a result of their professional and clinical duties, except where there is a legal obligation for disclosure. This includes the use of social media.
3. Sonographers must be committed to the provision of a quality ultrasound service having due regard for the legislation, ethical, professional and governance frameworks and established codes of practice related to healthcare provision in order to minimise risk to patients, patients' carers and other professionals.
4. Sonographers are legally and professionally accountable for their own practice and must not be influenced by any form of discrimination.

5. Sonographers must identify limitations in their practice and request training and support to meet their perceived needs. They must refer patients to a suitably qualified practitioner if the care they require is beyond their scope of practice.
6. Sonographers will take all reasonable opportunity to maintain and improve their knowledge and professional competency and that of their peers and students.
7. Sonographers must pay due regard to the way in which they are remunerated for their work. Any potential conflicts of interest should be declared and should not impact clinical judgement.
8. Sonographers have a duty of care to work collaboratively and in co-operation with the multidisciplinary healthcare team in the interests of their patients and patients' carers.
9. Sonographers must act at all times in such a manner as to justify public trust and confidence, to uphold and enhance the reputation of sonography and to serve the public interest.
10. Sonographers must ensure that they represent their qualifications, education, experience, training and competence accurately. They should only use titles that are recognised in the UK when addressing patients, so as not to mislead patients into believing for example that a sonographer is a registered doctor in the UK if they are not GMC registered to practice at that level.
11. Sonographers must ensure that unethical conduct and any circumstances where patients and others are at risk are reported to the appropriate authority.
12. Sonographers who are held accountable in another area of healthcare must relate this Code to others that govern their practice.
13. Sonographers should try to take care of their own health and wellbeing, recognising its importance to good practice and keeping patients safe ([SoR, 2025](#)).
14. Student / apprentice sonographers pursuing a qualification in medical ultrasound must adhere to their university or higher education institution's codes of conduct that relate to all elements of their ultrasound education and training. Additionally, any requirements set by [CASE](#) about supervised training must be followed.



The RCR (2025) [Standards for the interpretation and reporting of imaging investigations guidance](#), 3rd edition clearly state that:

“the prefix title “Doctor” or “Dr” should only be used to indicate a medically qualified practitioner.

This related to doctors who are no licenced to practice in the UK or those with a doctorate level qualification.

2.2 Professional indemnity

The UK government introduced legislation in 2014 which requires ultrasound practitioners who are statutorily registered with the HCPC (e.g. as a radiographer, physiotherapist or clinical scientist), the NMC (e.g. as a nurse or midwife) or other statutory regulator to have a professional indemnity arrangement as a condition of their statutory registration. The majority of statutorily registered ultrasound practitioners will already meet this requirement and will not need to take any further action. Either they work in an employed environment where their employer will indemnify them or, if they undertake self-employed work, they will have already made their own professional indemnity arrangements. However, some statutorily registered ultrasound practitioners may need to take steps to make sure that they have appropriate professional indemnity arrangements in place.

Registrants and applicants for statutory registration will be asked to confirm that they do, or will, meet this requirement by completing a professional declaration when renewing or registering for the first time. The HCPC has published guidance, [Professional indemnity and your registration](#), on the requirements, along with an accompanying flow diagram.

The NMC has published guidance, [Professional indemnity arrangements](#), as has the GMC: [Insurance indemnity and medico-legal support](#).

In addition to insurance obtained when working in an employed environment, PII is also available through membership of trade unions and professional bodies, which is often secondary PII, or can be purchased from medical defence unions or commercial insurers. Ultrasound practitioners should carefully review and follow the terms of any indemnity insurance they have.

Ultrasound practitioners who are self-employed or who work in a part-employed, part self-employed environment are particularly advised to read the guidance published by their statutory regulator. There is no PII associated with the RCT. If an ultrasound practitioner is not statutorily registered, it is clearly good practice to ensure that they have appropriate professional indemnity arrangements in place to protect both the public and themselves.

2.3 Medico-legal issues

The place of work should have a written set of protocols that accurately describe the range of ultrasound examinations undertaken. Their content should address the ultrasound examinations, their reporting and the appropriate referral pathways for patients with normal and abnormal ultrasound findings. The details in the protocols should be such that a new staff member, having read them, could carry out and report these examinations and appropriately refer the patient, after the examination, to the expected standard. Protocols should be updated regularly and their review date should be included in their content. Superseded protocols should be kept on file permanently.

Records are currently required by law to be kept for a number of years as specified by Department of Health and Social Care advice ([ref: section 2.13](#)).

The following guidance should be considered:

- Ultrasound practitioners should be aware that they are legally accountable for their professional actions, including the reporting of ultrasound examinations, in all circumstances.
- The report is a public document and part of the patient's medical record, together with any images, and/or video recordings which may accompany it.

- When a patient consents to an ultrasound examination, they have the right to expect it to be performed and reported by a competent ultrasound practitioner.
- A competent ultrasound practitioner is one who works to the standards defined by the guidelines of their place of work, the code of conduct of their professional body, the guidelines of that and other relevant bodies and of the regulatory body where appropriate.
- The standard of care provided by a competent ultrasound practitioner is that which the majority of similar individuals would provide and/or which a significant body of similar individuals would provide in similar and contemporaneous circumstances.
- Images that accompany an ultrasound examination carried out by a competent ultrasound practitioner evidence the assumption that the necessary standard of care has been delivered.
- All images must be capable of being attributed to the correct examination and should include the patient identifier(s), examination date and time.
- Nationally published requirements for the storage of images must be followed. Examples would be the image storage requirements of the AAA and fetal anomaly screening programmes and those published by the Department of Health and Social Care.

Ultrasound practitioners working in the NHS should have a job plan, detailing their duties, responsibilities, accountabilities and objectives (NHS England (2020) [E-job planning the clinical workforce](#)).

Refer to 'Duty of candour' ([ref: section 2.7.4](#)).

Reference is also made to medico-legal considerations relating to consent in [section 2.5](#).

Expert witnesses

Some ultrasound practitioners, with relevant expertise and experience, may undertake expert witness work for medico-legal cases and/or regulatory body fitness to practise cases. The CoR has an [expert witness list](#) which sonographers can apply to be included on. Subject to acceptance onto the list and following an introductory training day, ultrasound cases can be sent to the experts on the list for their consideration. Further information about the role and responsibilities of an expert witness can be found in the SoR|CoR document [The role of the expert witness: A guide for clinical imaging and therapeutic practitioners](#). [2023]

Further information on reducing the risk of litigation can be found in the ASA – BMUS joint statement [Reducing the risk of litigation: Information for sonographers](#) (2024) [2025]

2.4 Clinical governance

Clinical governance is defined in the 1998 consultation document [A First Class Service: Quality in the New NHS](#) and by [Scully and Donaldson in the British Medical Journal](#), also in 1998, as:

A framework through which NHS organisations are accountable for continuously improving the quality of their services and safeguarding high standards of care by creating an environment in which excellence in clinical care will flourish.

As clinical governance is based on professional values and concern for others, the ultrasound practitioner is actively involved in this process of accountability as part of their daily activities. By safeguarding high standards of care and seeking to continuously improve quality, it ensures that healthcare provision is patient-centred, which is central to the concept.

The main components of a clinical governance framework can be summarised as follows:

- i) Risk management
- ii) Clinical audit
- iii) Education, training and CPD
- iv) Patient and carer experience and involvement
- v) Staffing and staff management

NHS England has produced guidance: [Clinical governance](#) (2021, updated 2025).

For the ultrasound practitioner, clinical governance involves:

- i) Clinical effectiveness: taking part in personal, departmental and wider audit programmes to evaluate clinical practice and service to patients; this will include audit of ultrasound examinations and reports, participation in multidisciplinary team (MDT) meetings and radiology discrepancy meetings
- ii) Patient identification, communication and valid, informed consent ([ref: section 2.5](#))
- iii) Patient safety: including avoiding physical injury and following published ultrasound safety guidelines ([refs: section 2.8](#) and [section 2.12](#))
- iv) Ensuring the proper care and maintenance of equipment and not using damaged equipment or equipment that is not fit for purpose ([ref: section 2.9](#))
- v) Risk management: ultrasound practitioners have a duty to participate in education and training offered by employers on subjects such as back care, health and safety and infection control
- vi) Education, training and CPD ([ref: section 3.4](#))
- vii) Team working: see RCR/SCoR document [Team working in clinical imaging](#) (2012)
- viii) Patient, public and carer involvement
- ix) Being accountable for one's own actions
- x) The implementation of national clinical guidance which reflects the best standards of care; examples include implementing NICE Guidelines and national screening programme guidance and requirements
- xi) Incident reporting and raising concerns; this is of particular importance following the publication of the [Francis Report](#) in 2013 ([ref: section 2.7](#))

In 2008 the National Ultrasound Steering Group published a document entitled [Ultrasound Clinical Governance](#). The National Ultrasound Steering Group was a short-term subgroup of the National Imaging Board.

In June 2018, BMUS published a [position statement on NHS ultrasound services](#) that refers to the National Imaging Board document. [2018]

The following 'four-layer' advice from the GMC for those who work in an employed environment as part of wider clinical teams is also relevant to the topic of clinical governance and is included for consideration (General Medical Council (2004). Report and accounts 2004):

The first layer (of patient protection) is the individual practitioner and their commitment to a common set of ethics, values and principles which puts patients first. Next is team-based regulation which reflects the importance of acting if a colleague's conduct or performance is putting patients at risk. After that comes workplace regulation which reflects the responsibilities of NHS and other healthcare providers and finally, the regulator, through work on standards, education and fitness to practise.

Further information can be found at:

- Public Health Wales (2023) [Clinical Governance framework](#)
- RCR and SoR (2014) [Standards for the provision of an ultrasound service](#)
- RCR (2023) [Clinical Radiology Multidisciplinary team meetings: standards for clinical radiologists](#)
- RCR (2020) [Standards for radiology events and learning meetings](#)
- SCoR (2018) [Patient, Public and Practitioner Partnerships within Imaging and Radiotherapy: Guiding Principles](#)

2.5 The 6 Cs, patient identification, communication and consent

Compassion in Practice (the 6 Cs)

The 6 Cs are a set of values that underpin Compassion in Practice, a vision and strategy for nursing, midwifery and all health and care staff. This is part of the [Leading Change, Adding Value](#) framework.

They are:

C	Care
C	Competence
C	Compassion
C	Communication
C	Courage
C	Commitment

While undertaking any ultrasound examination and working in accordance with locally agreed practice, ultrasound practitioners should:

- Greet and correctly identify the patient using their name, address, date of birth (IPEM, CoR, RCR, 2019 [Patient identification: guidance and advice](#))
- Introduce self and others using “**hello my name is...**” and explaining the title and role of those present (<https://www.hellomynameis.org.uk/>)
- Obtain sufficient verbal and/or written information from the referring clinician to undertake correctly the examination requested ([ref: section 4.4](#))
- Ensure the proper care and maintenance of equipment and not use damaged equipment or equipment that is not fit for purpose
- Be mindful of the need to use appropriately trained professional interpreters as and when necessary to communicate adequately with the patient
- Be able to discuss the relative risks and benefits of the examination with the patient
- Explain the scanning procedure appropriately to the patient
- Obtain valid, informed consent from the patient or their representative being mindful of their capacity to understand

- Be aware of the individual patient's special needs including chaperoning and privacy during the examination ([ref: section 2.6](#))
- Be professional and understanding throughout the examination; manage the interaction between the patient and others in the room, in a way that enables the examination to be carried out to a competent standard
- Explain and discuss the findings with the patient within local guidelines
- Interpret and communicate the findings appropriately and in a timely fashion to the referring clinician
- Ensure appropriate arrangements have been made for further care before the conclusion of the examination as necessary

Consent

Valid, informed consent must be obtained before commencing any ultrasound examination or procedure. Ultrasound practitioners who do not respect the right of a patient to determine what happens to their own body in this way may be liable to legal or disciplinary action.

The consent process is a **continuum**, beginning with the referring healthcare professional who requests the ultrasound examination and ending with the ultrasound practitioner who carries it out. It is the responsibility of the referring professional to provide sufficient information to the patient to enable them to consent to the ultrasound examination being requested. It is the responsibility of the ultrasound practitioner to ensure that the patient understands the scope of the ultrasound examination prior to giving their consent.

The patient needs to have the capacity to consent to an examination or procedure. To do this they must be able to:

1. Understand the information in order to make a decision (see table below)
2. Remember that information
3. Use the information provided to make an informed decision
4. Communicate their decision to the healthcare provider

Consent (taken from [SoR, 2020](#))

Information should be clear and presented in a way that can be understood.
It should include the following information, as a minimum:
• Having the procedure/test is voluntary
• The nature of the procedure
• Any limitations of the procedure/test
• Any risks associated with the procedure/test
• Possible consequences of not having the procedure/test
• Alternative options available

Important reading

- [Mordel v Royal Berkshire NHS Foundation Trust \[2019\] EWHC 2591 \(QB\) 2019](#). This is a case related to NHS FASP first trimester screening and consent.
- The [Montgomery ruling](#) (2015) highlights the need to ensure that patients are fully involved in decision-making processes, including providing evidence-based information that a 'reasonable person' in their position might 'attach significance to the risk'.

Verbal valid, informed consent must be obtained for all examinations and should be recorded in the ultrasound report. Additional valid, informed verbal consent should be obtained where a **learner** undertakes part or all the ultrasound examination under supervision. Some categories of ultrasound examination (interventional ultrasound, guided procedures, e.g. biopsies) will require written consent.

Literature which explains the scope of the examination clearly and accurately should be made available to patients prior to the ultrasound examination. NHS Choices carries information on a wide range of topics, for example [ultrasound scans](#).

The national screening programmes have explanatory literature available for patients and have published consent standards which are usually now included with the various NHS England service specifications.

There is much information that has been published on valid, informed consent. The following are all relevant:

BMUS

- [Statement on patient information and informed consent](#)
- [Transvaginal ultrasound examinations – Guidance for practitioners](#) (2nd edition, 2025)

SoR

- [Obtaining consent - a clinical guideline for the diagnostic imaging and radiotherapy workforce](#) (2018)
- [Consent for radiographers and sonographers: Reviewing guidance on consent](#) (2020)
- [Guidance on mental capacity decisions in diagnostic imaging and radiotherapy](#) (2018)
- [Intimate examinations and chaperone policy](#) (3rd edition, 2023)

GMC

- [Consent: patients and doctors making decisions together](#) (2008)
- [Decision making and consent](#) (2020, updated 2024)
- [The seven principles of decision making and consent](#)

HCPC

- [Guidance on confidentiality](#)
- [GDPR added to Confidentiality guidance for registrants](#)

NHS

- [Consent to treatment](#)

Communicating unexpected findings and difficult news [2020]

A consensus statement has been developed to assist sonographers when discussing unexpected findings in obstetric ultrasound settings. This document has been referred to in the 2023 [Pregnancy loss review](#).

Some of the principles within the consensus guidelines can be applied to any area of practice. See [Consensus guidelines for the delivery of unexpected news in obstetric ultrasound: The ASCKS framework](#) and the supplementary files.

2.6 Intimate examinations and chaperones

The definition of an intimate examination may differ between individual patients for personal, ethnic, religious or cultural reasons. In addition, some patients may have a clear preference for a health carer of specific gender identity due to their ethnic, religious or cultural background, because of previous experiences or in view of their age. Where possible, such individual needs and preferences should be taken into consideration (SoR, 2023 [Intimate examinations and chaperone policy](#)).

When conducting an intimate examination, the ultrasound practitioner should:

- Act with propriety and in a courteous and professional manner
- Communicate sensitively and politely using professional terminology
- Follow published guidance for use of a chaperone (links below)
- Respect the patient's rights to dignity and privacy
- Comply with departmental schemes of work and protocols
- Ensure person-centred care is delivered

Patients should not be asked to remove clothing unnecessarily. When required, private, warm, comfortable and secure facilities for dressing and undressing should be provided. Care should be taken to ensure privacy in waiting areas used by patients not fully dressed in their own clothes. During the ultrasound examination, only those body parts under examination should be exposed. Care must be taken to maintain confidentiality when non-healthcare personnel are nearby.

Patients should be given the opportunity to have a chaperone, irrespective of the ultrasound practitioner's gender and the examination being undertaken. The ultrasound practitioner should give equal consideration to their own need for a chaperone, again, irrespective of the examination being undertaken or the gender of the patient.

A record should be made in patients' notes or ultrasound report when chaperones are offered and used, and when they are declined. The record should include the name and designation of the chaperone. Chaperones should normally be members of the clinical team who are sufficiently familiar with the ultrasound examination being carried out to be able to reliably judge whether the ultrasound practitioner's actions are professionally appropriate and justifiable. Chaperones should be trained in the role.

Patients' privacy and dignity should be maintained throughout the examination, which should be conducted without interruption. Only personnel essential for carrying out the examination should be in the room.

It is good practice (as for any examination) to ensure that, when possible, hand washing and equipment cleaning are carried out in full view of the patient at the beginning and end of the examination to reassure them that effective infection control procedures are being applied.

Advice on students/trainees and intimate examinations is given in the 2023 SoR document: [Intimate examinations and chaperone policy](#) and in the 2015 RCR document: [Intimate examinations and the use of chaperones](#).

Several organisations have produced advice on the conduct of intimate examinations and also on the use and role of chaperones:

- GMC [Intimate examinations and chaperones](#)
- Medical Defence Union (2022) [Protecting yourself from a sexual assault allegation](#)
- RCR (2015) [Intimate examinations and the use of chaperones](#)
- SoR (2023) [Intimate Examinations and Chaperone Policy](#)
- BMUS (2025) [Transvaginal Ultrasound Examinations – Guidance for Practitioners](#)



See additional resources at:

- 01_07 [Chaperones and consent](#)

2.7 Professional responsibilities and safeguarding

2.7.1 Safeguarding

Ultrasound practitioners have a duty to report concerns relating to children and vulnerable adults. Employers will have available advice and policies on the pathways that ultrasound practitioners are required to follow. Training and updating in local safeguarding procedures and policies is a mandatory requirement of the employer.

Further information can be found at:

- Dearnley, R. (2019) [Preventing modern slavery: The role of the NHS](#). NHS England Blog.
- Department of Health, Northern Ireland (2015) [Adult safeguarding. Prevention and protection partnership](#)
- NHS England (2023) [Safeguarding children, young people and adults at risk in the NHS](#)
- NHS England (2018) [Abuse and neglect of vulnerable adults](#)
- NICE (2009, updated 2017) [Child maltreatment: when to suspect maltreatment in under 18s](#)
- Public Health Wales (2017) [National Safeguarding Service](#)
- Scottish Parliament (2007) [Adult Support and Protection \(Scotland\) Act 2007](#)
- The Scottish Government (2021, updated 2023) [National guidance for child protection in Scotland 2021 – updated 2023](#)

2.7.2 Raising concerns

It is important to read this section in association with the executive summary of the February 2013 [Report of the Mid Staffordshire NHS Foundation Trust Public Enquiry \('The Francis Report'\)](#).

NHS trusts and health boards will have their own published policies on 'raising concerns' following the publication of the Francis Report. All healthcare professionals have a professional duty to report concerns they may have about the safety of patients and of service delivery.

The following advice will also be helpful if needing to raise concerns:

Care Quality Commission (CQC):

- [Report a concern if you are a member of staff](#)

HCPC:

- [Fitness to practise - Raising concerns](#)

NHS England

- [Freedom to speak up](#)
- [The national speak up policy](#) (2022)

NHS Resolution:

- [Our refreshed 2019 to 2022 strategic plan: Delivering fair resolution and learning from harm.](#) (2019) – provides information on the strategy to help support NHS staff when things go wrong and help identify ways to learn from errors and prevent future errors
- [Five years of cerebral palsy claims](#) (2017) – reviewed cerebral palsy claims as part of the NHS target to reduce still birth, neonatal and maternal deaths, to share learning from such cases

SoR:

- [Raising concerns in the workplace: guidance for SoR members](#) (2015)

The [NHS Constitution](#) (2023) provides information for healthcare professionals about protecting patients and staff.

2.7.3 Female genital mutilation (FGM) – statutory requirements of practitioners

From 31 October 2015 (England and Wales) there is a legal requirement for all statutorily registered ultrasound practitioners to report to the police FGM in those younger than 18 years of age. This duty is on the individual ultrasound practitioner and not the employer; it cannot be transferred.

Complying with the duty does not breach any confidentiality requirement or other restriction of disclosure that might apply. The same principle also applies to ultrasound practitioners who are not statutorily registered. Ultrasound practitioners in Scotland and Northern Ireland should use their established safeguarding protocols as required.

Further information can be found at:

- Home Office (2015, updated 2016) [Mandatory reporting of female genital mutilation: procedural information](#)
- NHS England [FGM: mandatory reporting in healthcare](#) (contains flow diagrams and posters)
- NMC (2019) [Additional information on female genital mutilation cases](#)
- Education Authority Northern Ireland [Multi-agency practice guidelines: female genital mutilation](#)

2.7.4 Duty of candour

All healthcare professionals have a responsibility to act in an open and transparent way, particularly when things go wrong. Ultrasound practitioners should also be aware of the requirements of their professional indemnity insurer if asked to make any statements regarding patient care, complaints and claims.

Further information can be found at:

- NHS Resolution (2017) [Saying Sorry](#)
- PHE (2016) [NHS Screening Programmes. Duty of Candour](#)

- GMC and NMC (2015) [Openness and honesty when things go wrong: The professional duty of candour](#)

2.7.5 Conscientious objection

The following is the conscientious objection clause from the previously published 'Standards of Conduct, Performance and Ethics' that were associated with the PVRs:

You must report in writing to your employing authority, at the earliest date in your employment, any conscientious objection that may be relevant to your professional practice. You should explore with them ways in which you can avoid placing an unreasonable burden on colleagues because of this. Your right to conscientious objection does not exempt you from providing service users with full, unbiased information; for example, prior to prenatal screening or testing. You do not have the right to refuse to take part in any emergency treatment.

The NMC have advice, [Conscientious objection by nurses, midwives and nursing associates](#). This gives further details of the legal circumstances when such a clause might apply.

2.8 Safety of medical ultrasound

The BMUS [Statement on the safe use, and potential hazards of diagnostic ultrasound](#) states that:

Ultrasound is now accepted as being of considerable diagnostic value. There is no evidence that diagnostic ultrasound has produced any harm to patients in the time it has been in regular use in medical practice. However, the acoustic output of modern equipment is generally much greater than that of the early equipment and, in view of the continuing progress in equipment design and applications, outputs may be expected to continue to be subject to change. Also, investigations into the possibility of subtle or transient effects are still at an early stage. Consequently, diagnostic ultrasound can only be considered safe if used prudently.

Ultrasound exposure depends on many factors, including the examination type, patient body habitus and equipment settings. Some modes, such as B-mode, have a lower potential for tissue damage than Doppler, with pulsed Doppler techniques having the potential for the highest exposure levels. Recommendations related to ultrasound safety assume that the equipment being used is designed to international or national safety requirements and that it is operated by competent and trained personnel.

It is the responsibility of the operator or ultrasound practitioner to be aware of, and apply, the current safety standards and regulations and to undertake a risk/benefit assessment for each examination.

The SCoR and BMUS produced a joint statement, [SCoR and BMUS position statement: The use of portable ultrasound equipment for at home pregnancy scanning](#), to highlight concerns about the growing use of portable machines for self-scanning in pregnancy. [2020]

Key principles for the safe use of ultrasound are published in the document [Guidelines for the safe use of diagnostic ultrasound equipment](#):

- i) Medical ultrasound imaging should only be used for medical diagnosis and/or as an aid to medical/surgical interventions.
- ii) Ultrasound equipment should only be used by people who are fully trained in its safe and proper operation. This requires:
 - an appreciation of the potential thermal and mechanical bio-effects of ultrasound;
 - a full awareness of equipment settings;
 - an understanding of the effects of machine settings on power levels.

It is, however, recognised that ultrasound is a useful tool used for improving patient safety during procedures such as line and needle placement. While users may not have a full understanding of the physical properties of ultrasound imaging, they must be aware of the need to limit examination times and only use equipment for the proposed medical purpose.
- iii) Examination times should be kept as short as is necessary to produce a useful diagnostic result.
- iv) Output levels should be kept as low as is reasonably achievable while producing a useful diagnostic result.
- v) The operator should aim to stay within the BMUS recommended scan times (especially for obstetric examinations).
- vi) Scans in pregnancy should not be carried out for the sole purpose of producing souvenir videos or photographs.

BMUS has UK-leading advice on ultrasound safety that all ultrasound practitioners should be familiar with: [Physics and safety](#).

BMUS has also published guidance for the use of volunteers and patients for demonstrations: [Guidelines for the management of safety when using volunteers & patients for practical training and live demonstration in ultrasound scanning and consent](#). This includes scanning during pregnancy for demonstration and teaching purposes. [2019]

2.9 Ultrasound equipment and quality assurance testing

An ultrasound practitioner is expected to:

- i) Have detailed knowledge of ultrasound equipment in order to ensure that it is appropriate for purpose
- ii) Manipulate the equipment correctly so that patient diagnosis and management are not compromised
- iii) Take care when using the equipment in order to avoid damage
- iv) Ensure that regular planned preventative maintenance is carried out by qualified personnel
- v) Ensure that an agreed quality assurance programme is in place that incorporates the regular inspection of ultrasound machines and ancillary equipment.

The stated aims of quality assurance procedures applied to ultrasound equipment are to ensure consistent and acceptable levels of performance of the imaging system and image recording facilities and to ensure the safety of the patient. The foundation of a good quality assurance programme is regular visual inspection of the equipment and the reverberation pattern of each probe by the users, since the majority of faults may be detected in this way. Common faults are damage to probes, which may present an electrical or infection hazard and/or affect the efficiency of all or part of the probe. Formal quality assurance protocols focus on the consistency of specific features of image quality over time. The acceptability of image quality may not be apparent from measurable changes in the parameters tested. The issue of what constitutes unacceptable equipment performance is still very difficult to assess objectively, but there is evidence that probe faults, such as drop out affecting more than one element, compromise diagnostic quality.

There is a section relating to image quality requirements, quality assurance and equipment replacement in the RCR/SCoR document [Standards for the provision of an ultrasound service](#) (2014) (section 2).

BMUS has recommended quality assurance testing and monitoring advice available in the article by Dudley *et al.*, 2014, [The BMUS guidelines for regular quality assurance testing of ultrasound scanners](#).

A [QA manual](#) facilitating the implementation of a system that complies with current guidelines is freely available in the UK. [2021]

2.10 Transducer and equipment cleaning and disinfection

[updated 2020]

There have been two previous Medicines and Healthcare Products Regulatory Agency (MHRA) alerts relating to transducer cleaning and disinfection:

- [Reusable transoesophageal echocardiography, transvaginal and transrectal ultrasound probes \(transducers\) – failure to appropriately decontaminate](#) (2014)
- [Ultrasound transducer probes with an internal lumen used for taking transrectal prostate biopsies](#) (2009)

In addition to the following guidelines, ultrasound practitioners should refer to published local infection control protocols and procedures. Many organisations also have infection prevention and control leads who should be consulted as necessary. Compared to just a few years ago there is now

a wide range of information available; departments and sonographers will need to make their own assessments as to what are the most appropriate cleaning and disinfection methods for transducers and equipment given their own circumstances. The Association of Healthcare Technology Providers for Imaging, Radiotherapy and Care (AXREM), BMUS and SCoR have published a document, [Ultrasound transducer decontamination – Best practice summary](#), and a downloadable [poster](#) to summarise the key documents and guidelines relating to decontamination of the ultrasound transducer and machines. Key highlights are referred to below. **[2020]**

The document highlights issues to be included when considering the best method of decontamination, including:

- Type of examination being undertaken
- Manufacturer's recommendations for each transducer
- Whether the transducer has been reconditioned or was new
- Different methods of cleaning the machine and transducer cables
- Staff training and personal protective equipment use
- Quality assurance and recording of decontamination processes



1. Remove transducer cover, gel/visible soiled material from transducer.
2. Visually inspect the transducer, cable and machine. Report any signs of damage and remove affected piece of equipment.
3. Determine the level of decontamination required and refer to the manufacturer's guidance on cleaning products or devices which can be used.
4. Follow decontamination process.
5. Record actions where required.

Types of decontamination [2020]

Type of decontamination	Cleaning	Cleaning and disinfection	Cleaning and sterilisation
When to use	<ul style="list-style-type: none"> • Intact skin e.g. transabdominal examinations, superficial structures, vascular 	<ul style="list-style-type: none"> • Broken skin (including post-interventional procedures) • Infected skin • Contact with known pathogenic microbes • Intracavity examinations with mucous membrane contact e.g. transvaginal or transrectal examinations 	<ul style="list-style-type: none"> • Use in a sterile area of the body e.g. intraoperative or intracranial examination
What to use	Manufacturer-approved wipes	An automated decontamination system is best practice; where this is not possible, manufacturer-approved wipes and cleaning system	Manufacturer-approved sterilisation device or process
Warnings	<p>Check approved options for each type of transducer</p> <p>Gentle use</p> <p>Training needed</p>	<p>Training, monitoring and review of any cleaning system used is required</p> <p>Audit trail required of decontamination for every endo-cavity examination</p> <p>Handle with care and where relevant use personal protective equipment (PPE)</p> <p>Training needed</p>	<p>Training, monitoring and review of any cleaning system used is required</p> <p>Audit trail required of decontamination for every patient</p> <p>Handle with care and where relevant use PPE</p> <p>Training needed</p>

2.10.1 Ultrasound gel

[2021, updated 2025]

In November 2021, the [UK Health Security Agency](#) (UKHSA) published updated guidance on the safe use of ultrasound gel following a national patient safety alert. This was updated in May 2022 and again in January 2025. As the guidance changes regularly, it is important to check the UKHSA guidance periodically. Key recommendations beyond hand hygiene, probe decontamination and gel storage include, but are not limited to:

- Sterile gel in single use sachets should be used for invasive procedures or when an invasive procedure may be performed in the following 24 hours; for use on non-intact skin or where there is contact with mucous membranes, e.g. transvaginal or transrectal scans and on severely immunocompromised individuals or in high dependency settings. If an unplanned procedure takes place within 24 hours of using gel, the site needs to be cleaned carefully
- Non-sterile gel should not be decanted from larger gel containers
- Bottles of non-sterile gel should be dated when opened and used within one month
- Gel bottles should not be inverted in a bottle holder. They must be stored upright so that the nozzle does not come into contact with any surfaces
- The tip of the gel bottle should be wiped with a disinfectant wipe before and after use and should not come into contact with the patient's skin or equipment
- Gel should be removed from the patient's skin after the examination
- Warming of gel is not advised

2.10.1 Ultrasound probe covers

[2023]

When using ultrasound probe covers or sheaths, it is important to ensure full removal of an intact cover to reduce the chance of infection. The SoR has published a position statement [Preventing retention of sheaths, 'foreign objects' and ultrasound probe covers following intimate and invasive radiological procedures](#).

2.11 Examination times

The time allowed for an ultrasound examination should take into account the fact that the actual transducer time is only one component of the overall examination, as highlighted in the SoR document [Ultrasound examination times and appointments](#) (2020). In many cases the maximum appointment times are limited by the [NHS national tariff payment system](#), which has different payments for ultrasound examinations with a duration of less than 20 minutes and those over 20 minutes.

Time needs to be allowed for room preparation, assessing the ultrasound request, introductions and explanations, obtaining valid consent and assisting the patient when necessary onto and off the examination couch. Post-procedure time is required to discuss the findings with the patient, write the report, archive the images and attend to the aftercare of the patient, including making arrangements for further appointments and/or further investigations ([SoR, 2020](#)). Equipment will also need cleaning and disinfecting as required post-examination.

An ultrasound practitioner has a professional responsibility to ensure that the time allocated for an examination is sufficient to enable it to be carried out and reported safely and competently, with critical and urgent findings dealt with appropriately. It is critical to patient management that no ultrasound examination is compromised by departmental and/or government targets. You are advised to put concerns in writing, report any issues and speak to your trade union representatives if necessary e.g. SoR representative.

The allocated appointment time will vary depending on the type and complexity of the ultrasound examination. It may also be influenced by the expertise of the ultrasound practitioner and training commitments within the department. In addition, the duration of the examination will be influenced by the scan findings and/or the physical condition of the patient. The quality of equipment and general support available to the sonographer are also relevant. Having an assistant / support worker present can also impact the time taken for an examination ([SoR, 2020](#)). The SoR has a [Support worker and assistant practitioner \(SWAP\) resource hub](#), where additional information can be found.

[2025]

Examination times should be determined with reference to national standards such as those published by the NHS FASP, by organisations such as NICE and by proper evaluation of the local working arrangements and resources, which will be different for each service provider. Examination times will need to take into account whether there are trainees present and their stage of training, if teaching is to be effective.

Times for the two obstetric ultrasound screening scans are now within NHS England FASP Service Specifications Nos 16 and 17.

- [Service specification 16](#), page 13 (the ultrasound component of the combined screening test) states a **minimum** of 20 minutes.
- [Service specification 17](#), page 13 (18⁺⁰ to 20⁺⁶ week ultrasound scan) states a **minimum** of 30 minutes for a singleton pregnancy and 45 minutes for a multiple pregnancy.

[NICE Guidelines on twin and triplet pregnancy \(NG137\) \(2019, updated 2024\)](#) state that:

- 45 minutes should be allowed for anomaly scans in twin and triplet pregnancies (section 1.4.11), concurring with NHS FASP guidelines.
- 30 minutes should be allowed for growth scans on twins and triplets.

BMUS [Professional Guidance for Fetal Growth Scans Performed after 23 weeks of Gestation](#) recommend 30 minutes for a third trimester singleton growth scan and 45 minutes for twin pregnancy.

[2023]

[The AAA screening programme](#) (2017) has guidance on clinic booking times and overall session numbers in its Standard Operating Procedures. Appointments are at 5–10-minute intervals, with short breaks within each session, to include 15–18 scans in a 3-hour session.

The SoR has published guidance on [Ultrasound examination times and appointments](#) (2020). In the absence of any local evidence-based determination of examination times or national standards, the SoR advises that 20 minutes should be the minimum for a general abdominal ultrasound examination. The complete document should be read for full context.

[2020]

Individual departments can determine examination times, taking into account local circumstances. A tool to help evaluate these is the former [NHS Improvement - Examination Times Assessment Tool](#) (select improvement toolkit from the right hand list: Radiology section A: Challenge 4). Full details of how to access this are in Appendix 3 of the SoR examination times document.

Many request forms are very non-specific in terms of the patient's symptoms, and due allowance may need to be made for this in schedule planning if it is decided to proceed ([ref: section 4.4](#)). For example, it may be necessary to perform both transabdominal (TA) and transvaginal (TV) scans to fully evaluate the abdomen and pelvis of women with ultrasound.

The SoR document [Principles of safe staffing for radiography leaders](#) (2024) may be helpful to ensure appropriate skill mix when planning ultrasound services.

[2025]

2.12 Ergonomic practice, including high body mass index (BMI)

Prevention and management of work-related musculoskeletal disorders

Work-related musculoskeletal disorders (WRMSDs) are known to be associated with ultrasound practice. There are several causative factors, including high workloads, increasing patient BMI, poor equipment, room design and organisation of list, stress, poor posture and ergonomics when scanning. It is important that ultrasound practitioners take care of themselves and their working environment while scanning.

Employers have a legal duty of care to their employees and should be guided in ways to avoid potential work-related injuries, i.e. by supplying equipment fit for purpose and being realistic about time management. Departmental guidelines should include strategies to minimise the risk of WRMSDs, including appropriate management of workload.

A range of advice and guidance documents have been published, to which ultrasound practitioners are referred.

Health and Safety Executive

- [Risk management of musculoskeletal disorders in sonography work](#) (2012)

SoR

- [Work related musculoskeletal disorders \(sonographers\)](#) 3rd edition (2019)
- [The causes of musculoskeletal injury amongst sonographers in the UK](#) (2002)
- [Prevention of work-related musculoskeletal disorders](#) (2007)
- [Ultrasound ergonomics poster](#) (2019)

RCR and SCoR

- [Standards for the provision of an ultrasound service](#) (2014) (section 2)

Managing the high-BMI patient

Information is provided in the 2019 SoR document [Work related musculoskeletal disorders \(sonographers\)](#).

2.13 Acquisition, archiving and use of ultrasound data

Ultrasound data refer to ultrasound images, ultrasound reports and request forms. It includes images captured and stored in digital, video, film and thermal paper formats and written reports/requests generated either in electronic form or on paper. The RCR published the second edition of [Guidance on maintaining patient confidentiality when using radiology department information systems](#) in November 2019.

Image recording

The compilation of an appropriate number of annotated images that represent the entire ultrasound examination is good practice as it provides the following:

- Support for the written report ([NHS resolution, 2018](#))
- A second opinion to be given on those parts of the examination that have been imaged
- A contribution to clinical governance through audit and quality assurance procedures ([RCR and SCoR, 2014](#); [BMUS recommended audit tool](#))
- A teaching tool

- Evidence that the examination was carried out to a competent standard
- Evidence that local and national guidelines and protocols were followed

Unless the entire examination is recorded it must be recognised that the ultrasound images cannot be fully representative of that examination. The stored images will have been chosen by the ultrasound practitioner as a reasonable selection to support the examination report only. If an abnormality or other pathology has been missed during the real-time examination, it is unlikely to have been included on an image.

All images should have the following demographic and machine information correctly recorded on them:

- Patient identification
- Date and time of examination
- Hospital/trust/department/provider identification

Ultrasound practitioners should be aware that the on-screen information is not always reproduced on the recorded images. For example, the safety indices displayed during the real-time examination may not be replicated. This will depend on the machine in use.

Managers of ultrasound services should ensure that the local protocols and guidelines address the issue of:

- Ultrasound data acquisition
- Storage and archiving of specific ultrasound data in accordance with national guidance and current legislation including the data protection and freedom of information acts

It is the ultrasound practitioner's responsibility to ensure that they are familiar with local protocols for image recording and storage.

Selection of images

Recording of images should be done in accordance with agreed local protocols and/or as required by national protocols where these exist (e.g. within screening programmes). Ultrasound practitioners should ensure that stored images are correctly annotated and can be benchmarked against the national standard.

Professional judgement should be exercised in the selection and recording of any images in addition to those required by protocol to support the examination report or demonstrate that a measurement has been made. As technology develops, entire examinations may be able to be routinely saved, thus removing the need to select specific images for recording.

Screening programme requirements

The [NHS FASP](#) and the [AAA screening programme](#) have published requirements for the images that must be recorded.

The equivalent screening programmes in the devolved countries will have their own recommendations ([ref: section 1.4](#)).

Independent practice ([ref: section 2.16](#))

Ultrasound practitioners working independently should be clear as to who owns the images and what their responsibilities are for image storage, and should have clear governance procedures relating to image recording and storage. If images are to be given to the patient at the end of the

examination, it is recommended that, as a minimum, an identical image set is stored by the provider for future reference.

Ultrasound practitioners working in England under the CQC ‘practising privileges’ exemption should be aware of the wording on page 8 of the CQC [Scope of Registration](#). This states that the hosting provider will own all records and will have responsibility for ensuring that essential levels of quality and safety are met.

Only the [CQC](#) can give formal advice on registration requirements; the onus is on the independent provider to register, unless advised otherwise by the CQC.

General advice on independent practice can be found at [section 2.16](#) of these Guidelines, within the RCR and SCoR’s (2014) [Standards for the provision of an ultrasound service](#) document and the [NHS Resolution report](#) (see page 24 onwards).

Storage of images and data

There are varying requirements for the storage of images and associated ultrasound data including the report and request form. For obstetric scans this can be up to 25 years or more. Scans on children and young people have similarly long retention times. Full details can be found at NHS England [Records management: Code of practice 2023](#).

Trusts, health boards, departments and independent providers should include details of image storage requirements and responsibilities within their governance procedures.

2.14 Recording of images by patients during examinations

[2019, updated 2022]

The ultrasound scans during pregnancy are a “challenging area of practice, as the sonographer has to balance the needs of the complex clinical examination with the needs of the needs and expectations of the parents.” ([SoR, 2021](#)) Any distractions should be minimised, to enable the ultrasound practitioner to focus on the scan and interpretation of findings.

The SoR has developed the following guidance documents to support local policy development:

- [Recording of images and clinical discussions by patients during diagnostic imaging, interventional procedures and radiotherapy treatment](#) (2019)
- [NHS obstetric ultrasound examinations. Guidance on sale of images, fetal sexing, commercial considerations and requests to record](#) (2021)
- [Recording images of sonographers performing NHS obstetric ultrasound examinations: Guidance to support local policy development](#) (2022)
- [Guidance and recommendations for running an effective, high-quality obstetric ultrasound service and supporting obstetric sonographer career development](#) (2023)

2.15 ‘Have you paused and checked’: posters and prompt cards

‘[Have you paused and checked?](#)’ posters and a prompt card have been published to support ultrasound practitioners in clinical imaging services. They are designed to act as a ready reminder of the checks that need to be made when any ultrasound examination is undertaken. The posters are designed in PDF format to allow for easy downloading and printing. They can then be displayed in the department as required. There are A4 and A3 sizes available and an A6 version that is small enough to be placed close to a machine or workstation. The posters have been developed by a joint working party from the SoR and BMUS.

2.16 Independent practice

Many ultrasound practitioners work independently where they are not directly employed by an organisation such as a health board, NHS trust or independent company; some will combine independent work with an employed post. There are a wide range of ways in which independent ultrasound practitioners can work, for example owning a private company, as a franchisor or franchisee, or as a sole trader. Ultrasound practitioners have also been successful in obtaining contracts via local NHS clinical commissioning groups (CCGs), as they were known, and the NHS 'Any Qualified Provider' scheme, either individually or in partnership with other ultrasound practitioners. These Guidelines cannot provide specific advice, although the following information may be helpful.

The CQC regulations, which are a legal requirement, apply to England only. Ultrasound practitioners practising independently in the devolved countries are advised to contact the equivalent organisations in their own countries for advice about any legal requirements that may apply.

- i) Unless exempted, the legal body that provides a regulated activity (service provider) must by law register with the CQC. Regulated activities include ultrasound. Service providers can be an individual, company, charity, partnership, NHS trust or other organisation. The onus is on the service provider to register (CQC [The scope of registration](#), 2015).

The regulations relating to hosting arrangements, subcontracted services and 'practising privileges' are complex and can be found on pages 8 and 9 of [the scope of registration](#) document. Only the CQC can formally advise as to whether CQC registration is necessary.

The CQC guidance [Independent healthcare services: information for providers](#) may help with additional advice.

Scotland has published legal requirements on the registration of independent clinics: [Regulation of independent healthcare in Scotland](#).

- ii) Many contracts of employment with trusts and health boards and independent companies require disclosure of independent work and activities that may have a bearing on the work of the employer and, even if not stated, may be implied or judged to be so once operational. There may be conflicts of interests that arise. Independent practitioners are advised to seek advice, for example from their employer, or seek independent legal advice.
- iii) Ultrasound practitioners should be entirely clear on when they are working independently (self-employed) and when they are working as an employee. This should be made clear in any written contracts, but some are very poorly written and constructed and this is not always apparent. The Advisory, Conciliation and Arbitration Service (ACAS) has advice on [employment](#) contracts, or independent legal advice can be sought. Independent practitioners should be aware of the differences between a 'contract of service' and a 'contract for services'. An employee–employer relationship is a 'contract of service' and a contractor–client relationship is a 'contract for services'. Further information is available here: [IR35 Explained: 'Contract of service' and 'contract for services'](#).
- iv) It is a requirement of statutory registration with regulatory bodies such as the [HCPC](#) and the [NMC](#) that a declaration of having PII in place is made at the time of initial registration or at renewal or revalidation ([ref: section 2.2](#)). Ultrasound practitioners working independently **must be aware of, and follow the requirements and conditions of, their professional indemnity insurer.** It is important to be fully aware of any terms and conditions that may

apply and that it is applicable to all areas of the ultrasound practitioner's work. Many professional indemnity policies will apply only to the individual practitioner and not to companies.



Some policies, such as the [SoR's Professional Indemnity Insurance \(PII\)](#) [member log-in required] are **secondary to a contract of employment** which must be in place, with the employer accepting primary vicarious liability.

Additional insurances for public liability, employer's liability and the ultrasound equipment itself may also be required, depending on circumstances. From 1 April 2013, independent sector providers of NHS services have been able to join the [Clinical Negligence Scheme for Trusts](#).

- v) The safety of patients is paramount and ultrasound practitioners must have documented evidence of their competencies, CPD and reflective practice and show evidence of audit of all aspects of the service(s) they provide. Governance arrangements should include protocols and procedures for image acquisition, storage and retention ([ref: section 2.13](#)). Refer also to the 2014 RCR and SCoR document [Standards for the provision of an ultrasound service](#).
- vi) Independent providers of NHS services are advised that there may be a requirement to hold an [NHS Provider licence](#). Providers are exempt if their annual applicable turnover from the provision of NHS services is less than £10 million, but there can be other factors affecting this such as if services are specifically designated by commissioners to require an NHS Provider licence to be held. Providers are advised to make their own enquiries with commissioners with which they hold contracts, as the rules are complex. These regulations apply in England.
- vii) The SoR has published information, [Independent practice and independent practitioners](#).

The RCR/SCoR (2014) document [Standards for the provision of an ultrasound service](#) applies to independent practice as it does for trusts, health boards and independent companies. There is guidance within on the qualificatory requirements of staff providing independent ultrasound services.
- viii) See [section 2.13](#) for guidance on image acquisition, retention and storage, which includes reference to independent practice.
- ix) Independent providers of national screening programme examinations (e.g. NHS FASP) must follow their published requirements with regard to service delivery and quality assurance procedures.
- x) Independent practitioners are encouraged to seek [Quality Standard for Imaging \(QSI\)](#) accreditation of their services ([ref: section 3.3](#)). **[2018, updated 2025]**
- xi) General Data Protection Regulation (GDPR) **[2018]**
The [GDPR](#) came into effect on 25 May 2018. Independent sonographers are likely to have responsibilities for data under the act as data controllers. There will probably be a requirement to register with the Information Commissioner. A registration self-assessment

tool is available. The assessment tool takes approximately 5 minutes to complete. There is a small fee if required to register with the Information Commissioner.

The [Data \(Use and Access\) Act 2025](#) should also be reviewed in association with the GDPR.

[2025]

xii) Marketing and advertising [2018, updated 2025]

The SoR, within its [Code of Professional Conduct 2025](#), states that practitioners must represent their “qualifications, education, experience, training and competence accurately.” and the HCPC [Standards of Conduct, Performance and Ethics](#) states that professionals “must take reasonable steps to make sure that any promotional activities you are involved in are accurate and are not likely to mislead.”

Any advertisement must conform to the British Codes of Advertising Practice and Sales Promotion. To achieve the standard, the following criteria apply:

- Advertisements should not be false, fraudulent, misleading, deceptive, self-laudatory, unfair or sensational.
- Advertisements should be dignified and professionally restrained.

The healthcare practitioner/patient relationship is important, so due regard should be paid to the maintenance of the highest ethical standards in any advertising. Direct appeals to patients, either face to face or over the telephone, should be avoided. It is undesirable to use too many abbreviations, which can be confusing to clients. Comparative claims with other practitioners should not be made in respect of superiority of skills, equipment and/or facilities. The term ‘specialist’ should be restricted to those who have a defined specialist skill. While it may be correct and proper for independent practitioners to be able to publicise their service and practice, they should act in a restrained and professional manner at all times. Claims with regard to registration status should not mislead.

Further information can be obtained from the [Advertising Standards Authority \(ASA\)](#). The [ASA issued advice](#) regarding advertising of private scans in pregnancy, following two cases. [2023]



When using **regulatory body, professional body or professional organisations’ logos** on a company website, make sure you have the right to use them and, if so, have appropriate permission, e.g. [HCPC](#), [SoR](#) and [BMUS](#).

Independent practitioners who are registered with a regulatory body such as the HCPC, GMC or NMC must also comply with their requirements.

It is important that claims made about the performance of specific imaging modalities or methods for screening for various types of pathology are accurate. See the [Private screening for health conditions: NHS recommendations](#) documentation.

SECTION 3: Education and accreditation

3.1 Education and training

[2025]

In the absence of statutory professional regulation for sonographers, the SoR and BMUS strongly encourage UK based sonographers complete a CASE accredited qualification. Where a sonographer does not hold a CASE accredited award, the comparability to [CASE Standards for sonographic education](#) should be assessed by employers. The SoR and BMUS document (2024) [Recruitment of sonographers without a CASE accredited award: Guidance for employers](#) offers practical information to support this assessment.

Key findings from the 2024 BMUS and SoR survey [Recruiting international sonographers and those without a CASE accredited award](#) have also been published.

A joint publication from the SoR, Royal College of Midwives and Chartered Society of Physiotherapy [Supporting international recruitment - principles & standards](#), provides further guidance. Other professional groups, particularly point of care ultrasound users, may adopt alternative training pathways endorsed by their respective bodies when CASE accredited focused courses or programmes are unavailable.

One major challenge in training ultrasound practitioners is the limited capacity for clinical placements. The SoR document (2025) [Potential ways to increase sonographer training capacity: case studies](#) outlines strategies for expanding clinical placement opportunities to accommodate additional trainees required to meet service demands.

High quality clinical education depends on well trained, supportive practice educators. The SoR document (2025) [Ultrasound practice educator guidance](#) details the requisite knowledge, skills and attributes of an ultrasound practice educator, offers best practice recommendations, and describes career development pathways for the role.

Refer to accreditation in [section 1.1](#).

3.2 eLearning for Healthcare

[Clinical Imaging](#) is an elearning programme developed by the SCoR, in collaboration with NHS England's award-winning [elfh programme](#).

The elearning provides CPD to support sonographers with interpreting ultrasound imaging and offering reports. The online training sessions complement existing teaching methods and provide a valuable reference point. They are designed to be engaging and interactive, using quality images, video and animation. Content is presented using various templates such as 'real-life' scenarios, case studies and self-assessment questions.

There are seven modules on ultrasound; each contains a number of sessions, as indicated below.

- Module 15 – Gynaecological Ultrasound – 9 sessions
- Module 16 – Abdominal Ultrasound – 19 sessions
- Module 17 – Men's Health Ultrasound – 3 sessions
- Module 18 – Vascular Ultrasound – 8 sessions

- Module 19 – Musculoskeletal Ultrasound – 11 sessions
- Module 20 – Head and Neck Ultrasound – 5 sessions
- Module 21 – Obstetric Ultrasound – 15 sessions and 15 multiple choice quizzes and 4 Saving Babies' Lives Care Bundle version 2 (SBLCBv2) sessions

The Clinical Imaging sessions have been written by expert ultrasound practitioners to match the format used by elfh. This is a very valuable learning resource and can contribute to an ultrasound practitioner's CPD ([ref: section 3.4](#)). All of the ultrasound sessions are reviewed every 3 years and most were updated in 2023/2024, with the remainder being updated in 2025/2026.

To access the free sessions, please register at <http://portal.e-lfh.org.uk/>. All elfh programmes are available to anyone with an NHS.uk, ac.uk or gov.uk account.

In addition to the Clinical Imaging programme, there are elfh modules covering a wide range of healthcare provision, leadership, communication and core skills. The national screening programme elearning resources (NHS FASP, AAA) is also on the elfh site.

Throughout these guidelines, some of the relevant elfh modules have been highlighted. Look out for the elfh symbol. **[2020, updated 2025]**



3.3 Quality Standard for Imaging (QSI)

[updated 2025]

All providers of ultrasound services are encouraged to align their services to the Quality Standard for Imaging, QSI (jointly owned and developed by the CoR and RCR).

The Standard and useful resources to meet the standard are available on the [CoR website](#) and [RCR website](#). Further information and support is available by contacting the Quality Improvement Partners at gsi@rcr.ac.uk

Services can be assessed against the Standard and work towards achieving the QSI Quality Mark, this provides strong and independent confirmation that high-quality services are being delivered.

Quality Improvement Partners can be contacted for further information about the process of assessment.

3.4 Continuing professional development (CPD)

CPD has been defined as:

... the process by which health professionals keep updated to meet the needs of patients, the health service, and their own professional development. It includes the continuous acquisition of new knowledge, skills, and attitudes to enable competent practice. ([Peck et al., 2000](#)).

It is a process that seamlessly continues from starting as a student, through successful completion of a first qualification, and lasts throughout a healthcare professional's life. CPD is embedded in the NHS clinical governance strategy ([ref: section 2.4](#)). All ultrasound practitioners must be engaged with CPD.

Statutory regulators including the HCPC, NMC and GMC each prescribe distinct CPD requirements. Some regulators, such as the HCPC, employ an 'outputs'-based model centred on learning and reflective practice, whereas others adopt an 'inputs'-based approach that prioritises certificates and attendance at formal study days.

Statutory regulators provide information on CPD for their registrants, for example the HCPC's [Continuing professional development and your registration](#), which applies to many ultrasound practitioners.

If an ultrasound practitioner is not statutorily registered, the same good practice principles of CPD will still apply. Ultrasound practitioners who are voluntarily registered with the [RCT](#) accept responsibility for their ongoing CPD activities. Audit of CPD, based on HCPC principles and systems, is part of registration with the RCT. Further information can be found on the [RCT website](#).

Evidence of CPD is also a requirement to maintain accreditation with the [CSVS](#).

Evaluation and reflection on the learning gained from the following activities can all be used as evidence to meet HCPC and RCT CPD requirements. Other regulators may have a different emphasis or procedures; ultrasound practitioners are advised to consult the website of their own regulator where information will be available.

- i) Successfully completing a programme of study
- ii) Attendance at, and participation in, appropriate professional workshops and conferences
- iii) Defining and implementing a departmental audit programme
- iv) Implementing a change process in practice
- v) Mentoring an ultrasound student in practice
- vi) Participation in an ultrasound or professional research project
- vii) Attendance at and participation in case reviews
- viii) Attendance at radiology discrepancy meetings and MDT meetings
- ix) Submission of a paper to a journal
- x) Critical evaluation of a peer-reviewed research paper
- xi) Peer review of an article for a journal
- xii) Teaching peers and students, both formally and informally
- xiii) Completion of [elfh](#) modules and other online learning activities
- xiv) Active engagement with a professional ultrasound group, professional or regulatory body or scientific society
- xv) Promoting the practice of ultrasound to other healthcare professionals within a wider context
- xvi) Communicating with, and imaging, patients

The list of possible activities is for example only. There are many and varied other activities that can also contribute to an individual's CPD.

It is important that suitable records are maintained and that evidence is compiled on a regular basis.

SoR members have access to [CPD Now](#). This is a user-friendly online tool for identifying, planning, evaluating and recording CPD that will also help the individual, if asked, to present evidence of CPD by the HCPC. A 'CPD Now' app is available for Android and IOS (Apple) devices.



Evidence should include not only attendance certificates at events but also written records of personal learning, reflection and details of how the learning will improve your practice, the service and experience of service users.

A document published by the Interprofessional CPD and Lifelong Learning UK Working Group, including representation from the SoR, [Principles for continuing professional development and lifelong learning in health and social care](#), was published in January 2019. This provides additional guidance on CPD.

The [Personalised Care Institute](#) provides free e-learning resources for health care professionals, to equip them with the "knowledge, skills and confidence to help patients get more involved in decisions about their care."

Both BMUS and the SoR have a range of CPD resources on their websites.

- Members of BMUS can access CPD via the BMUS website and gain CPD points by completing tasks relating to the BMUS journal [CPD Online](#).
- SoR [CPD resources](#) include [CPD shorts](#), [CPD Now approved](#) events and [webinars](#) and the [Radiate: Wellbeing hub, elfh sessions and CPD activities related to articles in the Insight journal](#).

3.5 Levels of practice

[2025]

The CoR [Education and career framework](#) highlights the levels of practice for staff working within imaging and oncology. The [Career framework for sonographers](#) (appendix A) demonstrates the levels of practice for a sonographer.

The CoR has produced mapping tools to assist practitioners at different career levels to map their current knowledge, skills and attributes to assist with learning needs analysis.

- [Education and career framework practitioner mapping tool: Consultant level knowledge, skills and attributes](#)
- [Education and career framework practitioner mapping tool: Advanced level knowledge, skills and attributes](#)
- [Education and career framework practitioner mapping tool: Enhanced level knowledge, skills and attributes](#)

Additional resources and frameworks include:

- CoR (2025) [Scope of Practice](#)
- CoR (2025) [Guidance on scope of practice for advanced practitioners and consultant practitioners 2025](#)
- CoR (2025) [Code of Professional Conduct 2025](#)
- NHSE [Consultant level practice](#)
- NHSE [Multi-professional consultant-level practice capability and impact framework](#)
- NHSE [Advanced practice](#)
- NHSE [Enhanced practice](#)
- NHSE [Multi-professional Practice-based Research Capabilities Framework](#)
- SoR [Consultant practitioner](#) resources
- SoR [Careers in ultrasound](#). Case studies

3.6 Audit, learning events and learning meetings

Introduction

As outlined in the RCR/SCoR 2014 document [Standards for the provision of an ultrasound service](#), objective and robust audit and review of non-obstetric ultrasound imaging is difficult owing to the very nature of the imaging specialty. Ultrasound is an operator-dependent imaging modality where image assessment and diagnosis occur in real time. The recorded still images are a record of the examination that was performed but they do not necessarily reflect the quality of the examination undertaken. That said, assessment of hard-copy images can be an indication of whether any imaging parameters have been altered and technique modified in response to the conditions found while undertaking the scan. There are multiple limiting factors affecting the quality and outcome of any ultrasound examination. In addition to patient factors, the age and quality of the machine being used, the experience of the operator and, not least, an understanding of the clinical question being asked all have an impact on the final outcome of any examination. Undertaking quality assurance of ultrasound studies under these conditions is challenging.

The subjectivity and operator dependence of ultrasound imaging needs to be recognised within any audit programme being implemented. Prior to implementation, it is essential that there is an understanding of what the audit programme is trying to achieve. It is also essential that staff members within the team in which the audit programme is being implemented understand the rationale for this programme, understand the process and engage with the process itself. Audit programmes should be viewed as a process rather than simply a means to an end. They should highlight areas where improvements can be made while recognising that resources and support will be necessary to ensure improvements can be implemented. Learning outcomes and actions points are an essential part of such audit programmes so that improvement to clinical practice can be monitored, focused and reviewed.

Actionable reports are required for safe patient management, and audit of the reporting outcomes is strongly advised by the RCR (2018) in the document [Actionable reporting](#). This method could be used in conjunction with the peer review audit tool outlined below.

For any ultrasound practitioner working in isolation or within a team, it is important to gain an understanding of the expected and achievable standard of practice. Knowing and understanding this standard will provide evidence for commissioners of any contracts but, more importantly, it will provide a benchmark against which practitioners can be measured and can measure themselves.

While issues of failing competency are rare, they are incredibly difficult to deal with if there is no known standard of practice within a service ([Parker and Byass, 2015](#)).

Reviewing images and reports is the essential first step in an ultrasound audit programme. A range of practices are already in place that may be used to assess quality or to inform services of their performance. These often include CPD activities such as follow-up of individual cases, image review/discrepancy/learning meetings and attendance at MDT meetings. While such CPD activities are vital in developing the education of ultrasound practitioners, they should be used in conjunction with, rather than instead of, a more formal quality assurance programme ([RCR and SoR, 2014](#)).

When undertaking an audit programme within an ultrasound service, a holistic view of the quality of an ultrasound examination is required. While image quality and overall report accuracy are important, it is essential that other factors such as clarity, content, readability and relevance of the report should be assessed. A limiting factor to the clarity of the report may be due, in part, to the quality of the referral. It is recommended that any audit programme assesses the referral for relevance and clarity of clinical question in addition to assessing the ultrasound examination itself.

Audit programme

There are various methods of audit process proposed in the literature and currently being undertaken in practice. However, BMUS has devised a universal [peer review audit tool](#) that can be used to evaluate the referral, the image quality and the report. While this tool may not encompass all audit programmes, it is recommended as a starting point from which in-house audit tools can be developed to meet local needs.

As yet, there are no national standards for expected quality of images and reports for non-obstetric ultrasound. The benchmark standard against which images and reports will be assessed will be limited by the individuals or department standard. An optimum approach would be to recruit external auditors to review practice, be this neighbouring trusts/health boards or colleagues, but it is recognised that this may encounter financial and time constraints.

In line with the CoR and RCR [Quality Standard for Imaging](#) and the RCR publication [Standards for radiology events and learning meetings](#) (2020), it is strongly recommended that this peer review audit is undertaken in conjunction with a radiology events and learning meeting (REALM). It is recommended that each service agrees a tolerance level of acceptable quality and any cases falling below this tolerance level should be discussed openly within a REALM, and learning points and further action agreed within the team of peers.



Standard 8 ([RCR, 2020](#))

There should be a culture of respectful sharing of knowledge with no blame or shame.

Recommendations for use of the BMUS audit tool

It is acknowledged that a peer review of images and reports takes time. A reasonable estimation of time required is to allocate an average of 5 minutes per case reviewed. It is recommended that services should aim for a review of 5% of all examinations and reports ([RCR, 2020](#)).

A timely retrospective audit of cases is required. Services may wish to allocate time on a daily, weekly or monthly basis. Access to image and report storage facilities are required and often

assistance from the IT department or PACS (picture archiving and communication system) manager is required to retrieve retrospective data on examinations performed.

A randomised sample of examinations will reduce bias between reviewers, and users of this tool are advised to determine a reliable method to both retrieve data and ensure it is randomised. Some users may prefer that the cases are anonymous, but this can make it difficult for the service to identify learning needs of individual practitioners.

Individual services will need to agree who within the team is to perform reviews, bearing in mind that an individual's inclusion into audit programme often improves compliance and enhances a sense of ownership and responsibility. It is strongly suggested that all practitioners within a team participate in the process.

A database for identifying cases that have been reviewed and storing the audit data will need to be established. This can be an electronic database, a system linked to hospital patient records or a paper filing system. Services need to be mindful of data protection and information governance guidance and legislation with regard to storing patient data.

Review process

Once cases for review have been identified, the reviewer will need to access the referral information, the images stored and the report issued.

- All three aspects of the examination are reviewed.
- Initially the clinical question should be reviewed. Is it clear and appropriate?
- The images are then reviewed and categorised into good, acceptable or poor. These judgements will be based on the reviewer's own standard of practice.
- The report will then be reviewed and again categorised into good, acceptable or poor. BMUS recommended reporting standards and best practice is documented in the article [What makes a good ultrasound report](#) (2014), available from the *Ultrasound* journal.
- Finally, the reviewer should determine if the clinical question has been answered and whether appropriate advice or a conclusion has been given where appropriate. This can include a statement of normality or 'no cause of symptoms demonstrated', and may be dictated by departmental practice. It is recognised that in some specialised cases, or cases including intervention, a conclusion may not be desirable or helpful.

All scores should be recorded on an appropriate database. It is recommended that cases falling below the level of the department's predetermined minimum standards are discussed with the individual practitioner before being discussed openly at a discrepancy meeting. It is strongly recommended that any significant errors, such as unreported pathology or significant typographical errors, are rectified immediately either by issuing a supplementary report or by recalling the patient following discussion with the practitioner and/or clinician referring the examination.

Learning from discrepancies

An ultrasound **disagreement** is identified by a person second reviewing images and/or a report, when their opinion is different to the original in retrospect. This review may occur as part of peer review, MDT or x-ray discussion, in-house audit or as part of routine work.

A reporting **discrepancy** occurs when a "retrospective review, or subsequent information about patient outcome, leads to an opinion different from that expressed in the original report ... Not all reporting discrepancies are errors" ([RCR, 2020](#)).

It is recommended that local terms of reference are agreed when establishing the meetings. The terms of reference should include as a minimum:

- the membership of the meeting
- the chair of the meeting
- confidentiality of the cases and discussions
- agreement as to whether or not the cases are anonymous
- the review process for cases being discussed
- how the cases are documented
- any grading and/or scoring system being implemented
- any voting process being used
- who is eligible to vote
- who the arbitrator is of any discussion
- how learning outcomes are recorded
- how action points are recorded
- how data is recorded for review
- duty of candour actions
- how serious errors or discrepancies are escalated.

Suggestions for holding ultrasound discrepancy meetings

It is recommended that discrepancy meetings are held every month. Those present with appropriate qualifications vote on the case using the following system.

Grade of disagreement

The aim of the outcome of discussions at the discrepancy meeting is to grade the severity of the disagreement. The following grades are suggested:

Grade	Radiological significance not clinical significance
0	No discrepancy – simply a disagreement!
1	Understandable miss Disagreement with report – no action required
2	Disagreement with report – report amended (should be called most of the time)
3	Significant disagreement with report – action required (should be called almost every time)

The majority view is taken.

Grade 0 is not a discrepancy but simply a disagreement of opinion between healthcare professionals.

Grade 1 is regarded as an understandable miss. Two examples are detailed below:

- *Images of the examination demonstrate that the **para-aortic region was not imaged or commented on**. Operators need to be aware of the reason for scanning the para-aortic region. This is done to assess for enlarged lymph nodes, but it is understandable why this was not imaged, given the clinical details and presence of gas in the abdomen.*
- *A liver that appears to be hyperechoic compared to the kidney on review of the images may have appeared normal at the time of the examination. The appearances may be due to the machine quality and setting. Only with additional clinical information such as increased liver blood tests (LBTs) would the possibility and significance of fatty infiltration be considered.*

These are contentious points, and this is why we take a majority view from a group of qualified peers.

Grades 2 and 3 are reporting discrepancies. A reporting discrepancy occurs when a retrospective review, or subsequent information about patient outcome, leads to an opinion different from that expressed in the original report. Not all reporting disagreements are errors.

Grade 2 may be a discrepancy in which the wording of the report is ambiguous or additional statements are required to improve diagnosis. An example of a grade 2 discrepancy is detailed below:

- *On review of the images, there is apparent right renal pelvis fullness but no other evidence of hydronephrosis or renal obstruction. No evaluation of resistance indices made which may have improved diagnostic confidence. The report states no cause for obstruction seen, implying the kidney is obstructed. On discussion with the peers, the majority would have worded the report differently, which may have affected future patient management but not significantly affected outcome.*

Grade 3 may be a discrepancy in which an abnormality is demonstrated on the images and not documented on the report or where the abnormality imaged is interpreted differently from the majority view. In the vast majority of these cases, the patient is recalled for a subsequent follow-up ultrasound examination or alternative imaging to evaluate whether an abnormality has been missed or misinterpreted. The findings of any such review examinations are fed back to the individual operator via a one-to-one discussion and to the team at the next disagreement meeting.

Type of disagreement

If a grade 3 discrepancy has occurred, it is recommended that the discrepancy is benchmarked to promote personal and corporate reflection.

	Type of discrepancy
A	Observation
B	Interpretation
C	Poor imaging technique
D	Poor wording

Following discussion and agreement of the grade and type of discrepancy, the meeting should agree learning outcomes and action points for the individual and team. This may include a change to guidelines, additional training, a revision of pathologies and conditions occurring in certain patient groups or simply a review of a single case. Any such learning outcomes and action points should be recorded, with a copy being sent to the individual practitioner and a copy stored securely within the department for future reference.

Duty of candour

A process needs to be established for how errors and/or disagreements are communicated to the referrer and subsequently the patient. It is recommended that ultrasound practitioners and departments seek advice regarding local practice and guidelines within their local service. ([ref: section 2.7.4](#)).

The NMC and GMC have advice on the duty of candour in their document [Openness and honesty when things go wrong: the professional duty of candour](#) (2015).

Ultrasound practitioners should also be aware of the requirements of their professional indemnity insurer if asked to make any statements regarding patient care, complaints and claims.

Further information can be found at:

- National Ultrasound Steering Group (NUSG), a subgroup of the National Imaging Board (2008) [Ultrasound Clinical Governance](#)

3.7 Preceptorship and capability development

[2022]

As part of the sonographer career development work funded by HEE (now part of NHS England), the [Preceptorship and capability development framework for sonographers](#) was launched in 2022 and revised in 2023. This document provides support and advice for managers, education providers and sonographers to assist the transition of newly qualified sonographers into the workplace, support new staff or those progressing into different roles and help sonographers to identify and plan progression along the sonography career framework.

Examples of activities and responsibilities associated with each career level (practitioner/preceptee, enhanced, advanced and consultant practitioner) are given in addition to advice on methods to engage with these activities. Levels of practice and responsibilities are aligned with HEE's [Multi-professional framework for advanced practice 2025](#) in England, [CASE standards](#) and the [Sonographer career and progression framework](#) (currently available within the [Preceptorship and capability development document](#)) and cover all four pillars of practice, namely; clinical practice, education, research, leadership and management.

Templates on how to record preceptee and mentee meetings are provided in appendices B and C of the document.

BMUS offers a Preceptorship endorsement scheme for trusts created specifically for sonographers. This scheme is designed to assist departments with a structured preceptorship scheme for new and established staff and can assist departments to prepare for quality inspections. Details of the scheme can be obtained from: professionalofficer@bmus.org.

SECTION 4: Introduction to the ultrasound examination

This section includes examination-specific guidelines and common clinical scenarios. These have been compiled by subgroup experts within BMUS and the SoR. Each section presents examples of good practice which it is hoped will be of value to departments. Guidelines or links to information on the vetting and justifying of ultrasound requests, reporting and audit are also included. The Guidelines presented here are not prescriptive.



These Guidelines do not and cannot cover all elements of an ultrasound examination. Ultrasound practitioners are advised to access additional published information and research in order to fully inform their own local departmental protocols and procedures when there are no nationally agreed ones available.

4.1 Overview of ultrasound examination procedures

Relating to all ultrasound examinations, the ultrasound practitioner should be aware of locally agreed standards of practice and current guidelines of other professional bodies and organisations.

The following points should be considered for all ultrasound examinations:

- The patient is correctly identified following required departmental procedures.
- The clinical details provided are sufficient to carry out the examination requested and the correct examination has been requested.
- Relevant information is available from the case notes, previous investigations and other sources.
- The role of the ultrasound examination is understood in the clinical context for the patient.
- The potential risks involved in the procedure are explained to the patient.
- Valid, informed consent is obtained before proceeding with the examination.
- Requirements for chaperones are followed where applicable.
- Due consideration is given to the need for an interpreter.
- A systematic scanning approach is adopted that can be modified as required.
- Requirements and recommendations are followed should the examination be incomplete.
- The need to extend the ultrasound examination, and/or proceed to additional imaging techniques is considered where necessary in accordance with locally agreed protocol.
- The aftercare of the patient is addressed.
- Appropriate national and local health and safety regulations, including infection control, are applied.

4.2 Vascular, echocardiography and breast examinations

In the 2015 edition and the subsequent revisions, no practice guidelines are included for vascular ultrasound examinations, echocardiography or for ultrasound of the breast.

Echocardiography

The [BSE](#) has published protocols for the various procedures that fall within its remit.

Vascular

For information on this aspect of ultrasound practice, please see the website of the [CSVs](#).

The CSVs has published [guidelines](#) for the various procedures that fall within its scope of practice. These include a number of clinical areas such as:

- Carotid Duplex Assessment
- Upper and Lower Limb Venous Duplex Ultrasound Examination for the Assessment of Deep Vein Thrombosis (DVT)

National recommendations for **carotid ultrasound** examinations can be found in the article [Joint recommendations for reporting carotid ultrasound investigations in the United Kingdom](#).

BMUS has published [giant cell arteritis \(GCA\)](#) guidance. The document is intended as a reference for departments or practitioners starting a GCA service in conjunction with rheumatology colleagues. It is not a training document and does not replace formal training in this area, but will act as a guide for new service development. Further information can also be found in the CSVs document [Vascular Technology Professional Performance Guidelines: Giant Cell Arteritis Duplex Ultrasound Examination](#).

For information about the **abdominal aorta** see [section 5.2.6](#).

4.3 NICE and other guidelines

[NICE](#) publishes a wide range of guidelines, many of which have implications for ultrasound practice.

Other organisations publishing guidelines include the following (the list is for example only):

- [AEPU](#)
- [BMUS](#)
- [BSE](#)
- [BSGI](#)
- [Clinical Imaging Board](#)
- [CSVs](#)
- [FME](#)
- [ISUOG](#)
- [NSC](#) and the individual national screening programmes
- [RCOG](#) (particularly the 'Green-top Guidelines')
- [RCR](#)
- [SoR](#)



Anyone undertaking an ultrasound examination should meet the knowledge, understanding and performance criteria defined by the Skills for Health National Occupational Standards:

- [Cl.C.2019 Perform, interpret and report on ultrasound examinations](#)
- [Cl.I Perform image guided procedures and/or interventions](#)

4.4 Vetting, justification and authorisation of ultrasound requests

An ultrasound department or provider may receive requests from many different sources, including wards, outpatient departments and primary care. Some departments and providers will also accept self-referrals for certain types of examination.

A fully completed ultrasound request in either paper or electronic form will normally be required for every examination undertaken. Departments and providers should make clear within their local requesting protocols who may request an ultrasound examination. This may, for example, be restricted to a medically qualified person or a qualified and registered healthcare practitioner. It is advised that non-medical requestors of NHS ultrasound scans have an agreed scheme of work approved by the imaging department or provider and by their relevant clinical lead prior to referrals being made. If self-referrals are accepted by the department or provider, the circumstances in which this may occur should be recorded within the local requesting protocols.

The ultrasound scans themselves may be performed by a variety of staff, in a variety of locations, both in and out of normal working hours. It is essential that ultrasound departments are proactive in managing workload to ensure that the right scan is performed in the right place, by the right person and at the right time. Protocoling of ultrasound requests by an ultrasound practitioner is therefore important.

Aims of vetting

These are:

- To ensure that ultrasound scans are justified and that the correct scan has been arranged with the appropriate patient preparation
- To ensure that clinically urgent requests are undertaken in a timely manner
- To ensure that the scans are undertaken by the right person, in the right place and at the right time

Checks should be made to determine whether the request has been completed correctly and complies with individual department policies. When vetting requests, it is important to consider patients' previous imaging history to avoid duplication and/or booking examinations at inappropriate time intervals. The vetting practitioner should be confident that the request provides sufficient clinical information and that the ultrasound examination is appropriate to answer the clinical problem posed. There should be an agreed departmental mechanism for dealing with inappropriate requests and requests for which the vetting practitioner is uncertain.

It is recommended that there be a procedure for flagging clinically urgent requests together with a mechanism for dealing with such requests.

Audit can be carried out as suggested by the RCR (2021) in the document [Vetting \(triaging\) and cancellation of inappropriate radiology requests](#).

Justification

Advice has been produced by BMUS in the document [Justification of ultrasound requests](#) (2022) to give best practice guidance to ultrasound providers. It is intended to support primary care physicians and ultrasound providers in the appropriate selection of patients for whom ultrasound would be beneficial in terms of diagnosis and or disease management.

This document has been written to aid ultrasound providers in justifying that an ultrasound examination is the best test to answer the clinical question posed by the referrer. While it is primarily aimed at primary care, the guidance is also relevant for other referrer groups. This document has been compiled by a panel of ultrasound experts to support good practice in vetting and justifying referrals for ultrasound examinations. It has been written with a pragmatic approach to managing referrals based on the panel's expert opinion. This document can be used to assist and underpin any local guidelines that are produced. Reference is made to the evidence-based [iRefer publication](#) and should be used in conjunction with this.

The NICE guidance NG12, [Suspected cancer: recognition and referral](#), published in June 2015 (updated 2025), has also been considered in the production of this updated publication.

In many instances, NICE advises urgent direct-access computed tomography (CT), but if this is unavailable it recommends that patients are referred for an urgent ultrasound examination. Local practice will dictate appropriate pathways following consideration of capacity and demand issues in each trust.

Principles

This document is based on several non-controversial principles:

- Imaging requests should include a **specific clinical question(s)** to answer, and contain **sufficient information** from the clinical history, physical examination and relevant laboratory investigations to support the suspected diagnosis(es).
- The majority of ultrasound examinations are now performed by ultrasound practitioners such as sonographers who are not medically qualified. Suspected diagnoses must be clearly stated, not implied by vague, non-specific terms such as 'pain query cause' or 'pathology'.
- Although ultrasound is an excellent imaging modality for a wide range of abdominal diseases, there are many for which it is not an appropriate first-line test (e.g. suspected occult malignancy).
- Given sufficient clinical information, most NHS providers will re-direct ultrasound requests to CT or magnetic resonance imaging (MRI) where appropriate, with the agreement of local commissioners.

This general guidance is based on clinical experience supported by peer-reviewed publications and established clinical guidelines and pathways. Individual cases may not always be easily categorised and local arrangements for prompt access to specialist advice are essential.

Local guidelines should include identification of who justifies the referral, timescales for vetting and appropriate training for individuals undertaking this process.

Changes to guidelines and pathways should be approved by local trust governance processes. It is recommended that any referrals returned to the referrer have an accompanying letter explaining

the rationale behind this. All actions should be documented and recorded on the local radiology information system.

Implementation

the service that is to be commissioned. This can be informed by service, and good practice guidelines should be incorporated into any contracts.

The suggested steps are given as guidance to service leads to aid implementation of the [BMUS Justification of ultrasound requests](#). **[updated, 2022]**

1. Be clear why guidelines are to be introduced. They may also represent best use of limited resources or may be required to limit demand.
2. The [BMUS document](#) can be used to assist and underpin local guidelines, in conjunction with the evidence-based RCR [iRefer publication](#). Local pathways should be established, based on level of service provision offered in primary and secondary care.
3. Once agreed, discuss with the service provider contracts lead (this may be a team in a large trust or a local manager if an independent provider) and enter into discussions with the local ICB.
4. Wider engagement is then needed with local ICB and general practitioner (GP) representatives, attending local learning events, meetings or committees to present the case and need for change. Be prepared to make further edits to the document to reflect feedback about local requirements.
5. Once agreed, plan a start date for implementation. A lead-in period may be considered where referrals are accepted but referrers are informed that they do not fit the proposed guidelines, and why.
6. Plan vetting time into schedules as declining referrals and communicating with GPs is time-consuming.
7. A clear and robust communication pathway is needed to ensure the referrer is informed if the referral is declined. It is vital that the reasons for declining are clear so that referrers may learn the new guidelines.
8. Ensure there is a system in place to record all referrals, including those declined. This may be the development of a local code on the patient information system, or a password-protected database.
9. Provide feedback to the ICB on the impact of implementation on waiting lists and referral quality and of any non-compliance.

4.5 Recommendations for the production of an ultrasound report

When considering ultrasound report writing, the following documents and publications are important:

- BMUS (2017) [Reporting of Ultrasound Imaging](#). BMUS position statement **[2018]**
- BMUS (2022) [Patient access to medical imaging reports](#). BMUS position statement **[2022]**
- Edwards, H., Smith, J., and Weston, M. (2014). [What makes a good ultrasound report?](#), Ultrasound 22, 57–60
- RCR and SoR (2014) [Standards for the provision of an ultrasound service](#) (section 5)
- RCR (2025) [Standards for interpretation and reporting of imaging investigations](#), 3rd edition

Safety statement

It is recognised in the book [The Safe Use of Ultrasound in Medical Diagnosis](#) (2012) that all personnel undertaking ultrasound examinations should be aware of the potential biological effects, of situations in which examinations may be contra-indicated, and of the nationally recommended mechanical and thermal indices and the ALARA principle ('as low as reasonably achievable') to reduce ultrasound patient dose.

General comments

- The ultrasound report should be written and issued by the operator undertaking the ultrasound examination and viewed as an integral part of the whole examination.
- The ultrasound practitioner is responsible for reviewing and taking into account previous imaging and investigations.
- The report should be written as soon as possible after the examination has been completed. NHS England's [Diagnostic imaging reporting turnaround times](#) (2023) specify that reports should be completed at the time of the examination or ultrasound scanning session. **[2023]**
- The name and status of the operator issuing the report should be recorded on the report. Where applicable, it is good practice to include the statutory regulatory body and registration number of the report author.
- The report author should take responsibility for the accuracy of the report and ensure that the report is communicated to the appropriate personnel.
- The report author should be aware of their limitations and consequently seek clinical advice when necessary.
- The report author should be aware at all times of the implications for the patient of the contents of the report and act in accordance with local guidelines, policies and procedures.

The RCR (2018) highlighted nine essential steps for production of an ultrasound report:

[NOTE: this has been superseded by the 2025 version of [Standards for interpretation and reporting of imaging investigations](#), 3rd edition and readers are advised to review the updated version, which includes guidance on the use of artificial intelligence (AI) assisted reporting].

[updated 2025]

1. Understanding clinical information

Sufficient clinical information should be provided by the referring clinician or be available to allow relevant and appropriate interpretation of the images. The person interpreting the images and then producing the report must understand the referring clinician's information and request. They should ensure that they fully understand the aim of the ultrasound examination, in order to affect a clinically useful and relevant report. The diagnostic importance of the report in the clinical management of the patient should be understood.

2. Technical knowledge

Ultrasound is an operator-dependent technique and the diagnostic quality of the images relies very much on the skills of the operator. The person interpreting and reporting the images must be able to reflect critically on the image quality and appraise the impact on diagnostic accuracy. Where the images are technically suboptimal (e.g. high patient BMI), the reporting author must decide whether the patient requires recall and rescan. It is recommended that any technical limitations of a scan are clearly recorded in the report.

3. Observation

To minimise the possibility of error in producing a report for the wrong patient, it is essential that the report author cross-checks the unique patient identification with the date and type of ultrasound examination performed ([ref: section 2.5](#)).

Observations may be subclassified as:

- Normal findings
- Abnormal findings: expected or unexpected
- Equivocal findings: may be normal or abnormal
- Normal variants
- Quality assurance and recording of decontamination processes



It is recommended that a systematic approach to image scrutiny is used for both live and post-scan analysis to ensure that the **S**hape, **S**ize, **O**utline, **T**exture, **V**ascularity, **M**ovement and **M**easurements of any findings are appropriately considered.

(Acronym **SSOTVMM**).

4. Analysis

Detailed critical analysis of the images should be undertaken, taking into account the observations and clinical reasoning to formulate a clinical opinion and to consider its diagnostic implication.

Examples:

Are the findings abnormal and do they directly relate to the clinical question?
Are the appearances simply normal age-related changes?

If the appearances represent active pathology, then further critical analysis is required to identify the most likely diagnosis and/or to provide a list of differential diagnoses.

5. Medical interpretation

The interpretation of the findings and subsequent report must be considered in the light of the wider clinical picture. In order to produce a relevant diagnostic report, review and understanding of any previous imaging or relevant investigations may be required. RCR (2018) stated that “a clinically relevant opinion encompasses all the known factors about the patient, as well as the imaging findings”. In this context, it is essential that the report author has extensive medical knowledge to reach a diagnosis or a series of ranked differential diagnoses on which clinical decisions can be made.

Whether the report is produced by a medically qualified or non-medically qualified ultrasound practitioner, it is essential that there are governance procedures in place to ensure that the individual does possess the knowledge, skills and competence to effect this duty without detriment to the patient outcome. In addition, there must be a failsafe mechanism to ensure that, when required, a radiological or equivalent expert opinion can be obtained promptly to allow the report to be issued without undue delay.

6. Advice

It is essential that the report author is aware of the diagnostic accuracy of the examination related to the individual patient. The level of certainty or doubt in the diagnosis should be made evident. If a definitive diagnosis cannot be made then advice

on further appropriate imaging investigations should be provided, when required. Local policy should exist clearly stating mechanisms for advising on relevant further investigations that takes account of the professional background of the report author, which may be a non-medical one.

7. Communication with the referrer

There needs to be an effective mechanism in place locally to ensure timely dissemination of the ultrasound report (Academy of Medical Royal Colleges, 2022 [Alerts and notifications of imaging reports: Recommendations](#)).

The report should be issued in line with RCR's recommendations ([Academy of Medical Royal Colleges, 2022](#); [RCR, 2025](#)) and must provide information which relates to the original clinical question, including expected and unexpected findings and their clinical relevance.

There should be an awareness of the referrer's understanding of such reports, and reports should be worded to ensure that the referrer is able to understand the clinical information expressed, including their access to complementary investigations (e.g. CT/MRI).

A mechanism to allow the referring clinician to discuss the report findings with the report author to ensure better understanding of the clinical impact of the report on management is appropriate. For example, a dedicated department email address may be set up to allow communication between referrers and reporters for such queries.

8. Taking appropriate action

The report author also has a duty of care to the patient to ensure that when immediate or urgent action is required, this information is delivered promptly to the referring clinician. This should be agreed at local level through appropriate 'alert mechanisms'. Such urgent communication(s) should be recorded in the report as recommended in the document [Alerts and notifications of imaging reports: Recommendations](#).

9. Communication with the patient

It may or may not be possible for the report author to pass on information regarding the outcome of the examination to the patient, particularly if there has not been time to review the wider clinical aspects of the case.

Caution is recommended when discussing the clinical findings with the patient, particularly in respect of possible management strategies where the report author may not have adequate knowledge. Ultrasound practitioners should also adhere to the guidance provided on communication by their professional body and NHS England's [Guidance on patient digital notification of diagnostic imaging reports](#) (2025).

Appropriate training should be undertaken prior to giving any difficult or unexpected news to ensure that such news is given sensitively and effectively and without ambiguity. ([BMUS, 2022](#); [Independent pregnancy loss review, 2023](#)).

10. Digital notification of ultrasound reports

[2025]

In 2019, the Healthcare Safety Investigation Branch (HSIB) report [Failures in communication or follow-up of unexpected significant radiological findings](#) recommended a digital method for notifying patients of unexpected significant

findings in an agreed timeframe. In July 2024, NHS England, RCR and SoR published guidance [Clinical guidance for automation of results release in patient engagement portals](#), which built on this recommendation, stating that all test results should be released via a digital route, where possible. It is recommended that a delay is factored into the release of results to provide time for the referrer to arrange follow-up care for patients with urgent results. In England, if this is not implemented patients may have access to their imaging reports immediately following their ultrasound appointment. For organisations that enable immediate access to reports, [NHS England, RCR and SoR](#) recommend using the following statement in imaging reports:

This report has been sent to the referring clinician (doctor or other healthcare professional) who referred you for this investigation. If you have any questions, please discuss with your referring clinician.

The guidance also highlights that reports contain “medical phrases and terminology” which might be difficult for patients, so a footnote may be included to highlight that.

Report content

It is recommended that an ultrasound report be divided into the following sections (Refer also to [RCR, 2025](#)):

- **Type of examination performed**

The type of ultrasound examination performed should be stated at the top of the report to ensure there is a true record.

Examples:

Ultrasound examination of the upper abdomen
Transvaginal ultrasound examination of the pelvis

This is particularly important in the latter example where it is essential to document the intimate nature of the procedure. Care is also required where a decision may have been made for appropriate reasons not to examine the pelvis when an abdomen and pelvis examination was requested. Standard generated headers such as ‘Ultrasound abdomen and pelvis’ must be amended appropriately and the reasons identified in the report.

- **Summary of clinical details**

It is often helpful to record an overview of key clinical history and findings at the start of the report. If the referring clinician has only provided scant information and further relevant information has been gleaned from the patient by the operator, this should be recorded accordingly. This will assist in setting the report in its true clinical context.

In cases where the clinical question within the referral is unclear, it may be useful to state the inferred clinical question which the report then sets out to answer.

- **Descriptive element**

It can be helpful to include a description of the observations and findings to include analysis of the **Size**, **Shape**, **Outline**, **Texture**, **Vascularity** and any **Movement** and **Measurements** of the structures examined.

Example:

A well-defined mass with mixed echoes is present in the left rectus sheath. The lesion is exquisitely tender. The mass measures 5.2 x 4.6 x 3.6cm. Appearances and findings are in keeping with a rectus sheath haematoma.

Any technical difficulties encountered must be noted, together with their impact on diagnostic accuracy.

Example:

Only limited intercostal views of the liver obtained owing to the presence of bowel gas obscuring access. However, where seen, the liver is normal in size and appearance.

- **Conclusion**

The standard use of a conclusion is good practice and should include an interpretation of the observed examination findings set into the clinical context and to answer the clinical question. This should not be a repetition of the main content of the report.

The main principal diagnosis should be given and the RCR recommends that, where possible, a single diagnosis should be reached. Where this is not possible, the most likely diagnosis should be highlighted, with other options listed in rank order of likelihood ([RCR, 2025](#)).

- **Differential diagnoses**

Where these are necessary, they should be limited in number and brief, and should include a statement as to why they are less likely than the primary diagnosis ([RCR, 2025](#)).

- **Recommendations for further investigations/management**

Appropriate recommendations for further investigation (e.g. CT/MRI/drainage/biopsy) or referral should be included, depending on local department guidelines and practice.

- **Identification of the author and contributors**

The name, position and profession of the person performing and interpreting the ultrasound examination should be clearly stated ([RCR, 2025](#)). This should also apply to anyone involved in second-party reporting. It is good practice to state the report author's GMC, HCPC or any other statutory regulatory body number, where applicable. The specific action of any secondary involvement should also be stated, e.g. "Dr -----, Consultant Radiologist, reviewed the images and agrees with the above interpretation".

- **Identification of chaperones**

Details of any chaperones or third parties in the room should be documented, giving name and professional capacity. The patient's actions regarding whether a chaperone was accepted or was offered and declined should be documented ([ref: section 2.6](#)).

- **Consent**

Details of any consent gained prior to the procedure should be documented. For instance, verbal consent gained for intimate examinations or written consent for biopsy procedures should be recorded ([ref: section 2.5](#)).

- **Additional relevant information**

Any further information gained during the examination which may affect future investigations or may have resulted in a non-standard procedure being undertaken should be included. For instance, "Due to latex allergy, a latex-free probe cover was used". (NB Local guidelines will need to be considered if such statements are to be used).

- **When patients have direct access to reports**

[2025]

Include the statement or similar, as advised by [NHS England, RCR and SoR 2024](#)

This report has been sent to the referring clinician (doctor or other healthcare professional) who referred you for this investigation. If you have any questions, please discuss with your referring clinician. ([NHS England, RCR and SoR 2024](#))

Report style (Edwards *et al.*, 2014, [What makes a good ultrasound report](#))

- Reports should be succinct, clear, unambiguous and relevant wherever possible.
- A standard reporting template is helpful for both the ultrasound operator and referring clinicians to establish a 'house style' which is clearly understood by all parties involved. However, standard reports which are understood and accepted by staff within a hospital may need to be modified for outside referrals. For example, reports to GPs may need to contain more advice regarding patient management than reports being written for hospital consultant referrals.
- Abbreviations are not recommended, in order to avoid ambiguity and potential confusion.
- Reports should be written in plain English language and should be free from the use of any ultrasound terminology (e.g. transonic, hyperechoic), as such phrases are generally meaningless to non-ultrasound users and, as such, may be subject to misinterpretation. Short paragraphs and appropriate layout should be used.
- The report should address the clinical question and generally pertain to the reason for referral.

Example:

The gallbladder is very tender and cholecystitis is the likely cause of the right upper quadrant pain.

- Where the examination is extended to examine areas other than those in the primary request, the structures examined and the subsequent findings must be clearly documented. The examination and the technique(s) used should be recorded.

Example:

A large left sided varicocoele is present and, in view of this, the kidneys were examined. Both kidneys appear normal and in particular the left kidney is normal on ultrasound examination.

- Any limitations (technical or clinical) of the examination should be stated and, if a relevant organ has not been fully examined/assessed, the reason(s) should be indicated.

Examples:

The pancreas is obscured by bowel gas and not seen adequately enough to assess.

The gallbladder is contracted as the patient is not fasted therefore the presence of small gallstones cannot be confirmed or excluded with confidence.

- Diagrams may be useful in describing the findings to the referring clinician (e.g. in vascular studies and gynaecology examinations) and a standard template can be used as an adjunct to the written report.
- The report should be conclusive where possible, indicating when the appearances are consistent with a specific diagnosis. Where no conclusion is possible, alternative explanations for the ultrasound appearances may be offered.
- Any relevant actions undertaken should be reported.

Example:

I have informed the patient that she has an ovarian cyst which requires follow-up. I have arranged a follow-up scan in 6 weeks' time. The patient is aware of this appointment. In view of the findings I have discussed these results with the referring clinician, Dr XXX, by telephone.

- If second opinions have been sought and given, or if other personnel have scanned the patient, their status, actions and opinions should be stated.

Examples:

Case discussed with Dr XXX, Consultant Radiologist, who agreed with findings and report.

Patient also scanned by Mrs XXX, Lead Sonographer, who agrees with the findings and report.

In conclusion, a good report is a report that answers the clinical question. The clinical question is ideally given in an appropriate request. Good reporting avoids confusion, clearly identifies the appropriate findings and gives a correct interpretation in a clear and unambiguous format. Ultimately, good reporting equates to good communication skills and, in the clinical context, will avoid error and potential harm to the patient.

Reporting audit [2018]

[Actionable reports](#) are required for safe patient management, and audit of the reporting outcomes is strongly advised by the [RCR \(2025\)](#). This method could be used in conjunction with the peer review audit tool outlined in [section 3.6](#) of this publication.

SECTION 5: Ultrasound clinical examinations



While there are suggested reports in this section, it is important to review these in relation to your local protocols and procedures and work within your own scope of practice.

Also be aware of the boundaries of your professional practice. For example, non-statutorily regulated healthcare professionals are unable to act as a referrer for ionising radiation examinations, train as an independent or supplementary prescriber or use Patient Group Directions (PGDs).

5.1 Gynaecological ultrasound examinations

[updated 2025]

General scanning principles

Gynaecological ultrasound is a useful imaging technique for women of all ages and has a role in identifying a wide range of pathology. It is particularly useful for imaging people of child-bearing age and younger patients since there is no associated radiation burden. To maximise diagnostic accuracy, the ultrasound practitioner must be aware of age-related appearances, the menopausal status of the patient and expected physiological changes of the menstrual cycle.

Due to the intimate nature of ultrasound examination, it is essential that it is conducted in a quiet room, without interruption and a chaperone offered. The practitioner must aim to preserve the patient's dignity and privacy at all times. The practitioner must also be mindful that many patients attending for this examination are very anxious. See SoR (2023) [Intimate examinations and chaperone policy](#).

Justification and clinical history

Prior to the examination, the ultrasound practitioner should consider the clinical referral and understand the clinical question posed. Additional essential information may be obtained from the patient. Before commencing the examination, the practitioner should be aware of the reason for referral, age, menstrual history, obstetric history, symptoms, relevant medication, previous relevant imaging, and previous gynaecological surgery/treatment.

Technique

It is considered best practice for all initial gynaecological ultrasound examinations to be performed via the TA approach using the distended bladder as an acoustic window. Scanning transabdominally with an empty bladder can also be useful. It gives a good overview and may be better in many cases than a scan with an over-filled bladder. TA assessment allows the whole of the pelvic contents to be imaged. Large or deep pelvic abnormalities may be identified but often with limited resolution.

The patient should be invited to empty their bladder to undergo TV assessment for an alternative and often more detailed evaluation of the pelvic structures. Valid, informed consent for a TV scan must be obtained. It is accepted that some patients may decline, or it may be inappropriate. Details of the type of examination and patient consent or decision to decline should be documented in the report. BMUS (2025) [Transvaginal ultrasound examinations – guidance for professionals](#), 2nd edition may be helpful.

[2022]

The TV probe can be used to assess mobility of the uterus and surrounding structures, looking for the '[sliding sign](#)' during gynaecological ultrasound examinations, particularly in patients with chronic pelvic pain. [2022]

The TV examination allows only a limited area to be imaged but with higher resolution than TA imaging. Large or deep pelvic abnormalities may not always be demonstrated adequately. Colour Doppler and/or power Doppler may be relevant in appropriate clinical presentations, e.g. the assessment of myometrial vascularity, ovarian tumour angiogenesis, or endometrial perfusion. Setting a low pulse repetition frequency to maximise Doppler sensitivity is essential.

3D/4D ultrasound offers the ability to assess the uterus and ovaries in multisectional and volumetric reconstruction and may be useful in the assessment of pathology and congenital malformations.

Structures to examine and evaluate

Structures should be examined in at least two planes. The size, outline, echotexture and vascularity, where relevant, of normal anatomy, anatomical variants and abnormal findings should be considered, taking into account menstrual status and age-related appearances. Included in the examination are:

- Bladder – wall and contents.
- Vagina – limited assessment of outline and echotexture is possible for some pathologies and congenital malformations. Also consider conditions such as haematocolpos or pyometrocolpos depending on clinical history.
- Cervix – internal os, external os, cervical canal, continuity with uterus, assessment of size, outline, echotexture.
- Uterus – size, shape, echotexture and position, e.g. anteversion, retroversion; the uterine length is dependent on age and parity. The outline should be smooth. Assess the echotexture and uniformity of the myometrium.
- Endometrium – thickness, echotexture and junctional zone.
 - *Premenopausal endometrium:*
Consider menstrual-related appearances, thickness, uniformity and junctional zone. The endometrium measures up to approximately 16mm in normal premenopausal women ([Gupta et al., 2017](#)). Protocols should be agreed with local clinicians.
 - *Postmenopausal endometrium:*
The length of the endometrium should be seen in its entirety and, if not, this should be reported. Fluid in the endometrial cavity should also be reported in symptomatic women.

Consider thickness, uniformity and junctional zone. If asymptomatic, up to and including 10mm ([Alcázar et al., 2018](#)) is acceptable, although features such as increased vascularity and heterogeneous endometrium should be noted and referral to a gynaecologist may be considered. Protocols should be agreed with local clinicians.
- Ovaries – size (in relation to reproductive status), shape and appearance should be noted. A volume calculation obtained from measurements in three different planes should be offered when ovarian volume is considered abnormal. The number and size of follicles may be relevant depending on hormone status, fertility treatment or use of specific contraceptives.
- Adnexa – structures including the broad ligament, pelvic muscles, main blood vessels, and Fallopian tubes may be identified.

- Rectouterine pouch (pouch of Douglas) – if fluid is present, consider whether it is more likely physiological or pathological. Consider anterior surface of the bowel wall lying directly behind the uterus. Deep endometriotic nodules may be visible here.



Imaging the uterus in the transverse plane is particularly helpful for identifying common congenital malformations such as Müllerian duct anomalies.

If this is a new finding of Müllerian duct anomalies, extending the examination to assess the kidneys can be helpful.

Normal appearances

On ultrasound, normal gynaecological appearances of, for example, the uterus vary greatly depending on the age and menopausal status of the woman. A premenopausal uterus is larger and pear-shaped whereas a postmenopausal uterus may take on a slimmer, tubular appearance in keeping with atrophy.



Gently push with the TV probe, after warning the patient, to assess for movement of the pelvic organs.

5.1.1 Common clinical scenarios

5.1.1.1 Uterus

Fibroids (leiomyoma)

These occur commonly, especially in women of Black ethnicities, and have an estimated prevalence of up to 70% ([Stewart et al., 2017](#)). They are clinically apparent in 25% of women of reproductive age and are benign tumours of fibrous and smooth muscular tissue. Some contain areas of necrosis and/or circumferential or punctate calcification. Location is variable and may be intramural, subserosal, submucosal, cervical or pedunculated. If fibroids occur near uterine cornua, they may impinge on the Fallopian tube and impair patency.

The common presentation is menorrhagia and/or dysmenorrhoea. Fibroids appear on ultrasound as well-defined areas of altered echogenicity. The fibrous content attenuates the ultrasound beam at a higher rate than the surrounding tissue, often resulting in multiple lines of shadowing being visible behind the fibroid.

When fibroids are identified, the practitioner should evaluate the number, location(s) and size. Where previous imaging is available, it is important to compare interval change in size and appearance. Rapid growth is associated with malignancy. Vascular patterns vary considerably and are unreliable for diagnosis, so colour Doppler has limited value.

Extending the examination

Large fibroids may compress one or both ureters. In such cases, the practitioner should proceed to a renal ultrasound examination to look for hydronephrosis.

Uterine leiomyosarcoma (LMS)

This is a rare but aggressive carcinoma of uterine muscle that occurs in one to five of every 1,000 women with fibroids. There are no reliable methods to diagnose LMS before surgery, and ultrasound appearances may be non-specific but can include a very heterogeneous myometrium with cystic spaces. LMS should be suspected if fibroids change rapidly in size, although it is worth emphasising that even in cases where there has been rapid growth, most fibroids will still be benign.

Adenomyosis

Diffuse or nodular deposits of endometrium within the myometrium. Presentation is often menorrhagia and/or dysmenorrhoea in multiparous women in their 40s. Ultrasound appearances may comprise an enlarged bulbous uterine fundus and body, and a coarse, heterogeneous myometrial echotexture, often containing small cystic spaces. Frequently, the posterior myometrium is thicker than the anterior myometrium ([Garcia *et al.*, 2011](#)). Acoustic linear shadows and an indistinct endometrial/myometrial junction may be visible. Concurrent discrete fibroids may also be seen; however, careful evaluation is required. Previously, adenomyosis has been misdiagnosed as 'early fibroid change'. If the appearances within the uterus are diffuse, with asymmetry of the myometrial walls, the appearances are more likely to indicate adenomyosis.

Endometriosis

This common disease often goes undetected on ultrasound, which contributes to long delays in diagnosis, averaging 8 – 12 years ('[Endometriosis' Guideline of European Society of Human Reproduction and Embryology](#), 2022). In addition to endometriomas, many features are visible sonographically, including nodules of deep endometriosis (DE) and an absence of normal movement of pelvic structures on gentle pressure (absent 'sliding sign' due to adhesions). Training may be required to visualise DE nodules, but the '[sliding sign](#)' should be part of routine pelvic ultrasound.

For patients with pelvic pain or menstrual disorders, especially those with dyschezia during a period, a detailed TV assessment, with consent, is required, with specific attention to the following:

- Bladder – look for DE nodules between the bladder and anterior surface of the uterus.
- Ovaries – look for endometriomas and gently check for mobility of the ovaries. Are they adherent to the uterus, or to each other ('kissing ovaries'), or are they located in the rectouterine pouch?
- Uterus – look for signs of focal or diffuse adenomyosis and check for the 'sliding sign' by using your free hand to press the lower abdomen while gently advancing the transducer against the cervix. The uterine fundus should move independently of adjacent bowel.
- Rectouterine pouch – again, check for sliding by gently advancing the transducer against the cervix to see if the anterior bowel wall just beneath the cervix slides independently (normal) or appears adhered to the cervix (abnormal).
- Bowel – look for DE nodules on the anterior bowel wall behind the uterus.
- Ureter – look for a distal hydroureter at the level of the cervical internal os and near the ovarian fossae and, if seen, proceed to assess the kidneys for hydronephrosis.



While scanning, remember to ask the patient for any specific sites of tenderness and examine those areas carefully to identify discrete nodules.

BMUS have a poster [Ultrasound for endometriosis](#), providing further information on potential ultrasound appearances.

Management advice

In some cases, a scan at a specialist centre may be warranted. It is recommended that departments locate their nearest centre of expertise.

The British Society of Gynaecological Endoscopy offers a list of [accredited UK endometriosis centres](#).

Further information can be found at:

Dr Susanne Johnson's site [GynaecologyUltrasound.com](#) offers a contemporary selection of videos on how to recognise endometriosis.

5.1.1.2 Endometrium

The British Menopause Society guidance (2024) [Management of unscheduled bleeding on hormone replacement therapy \(HRT\)](#) should be considered when assessing the endometrium in women taking HRT.

Benign endometrial hyperplasia

This is a common condition and is defined as >16mm ([Gupta et al., 2017](#)). in the secretory phase or >10mm in asymptomatic postmenopausal women ([Alcázar et al., 2018](#) and [Wolfman 2018](#)). It is often in response to oestrogen stimulus, and usually regresses spontaneously or responds well to treatment with hormones or minor surgery. Drugs such as hormone replacement therapy and Tamoxifen may induce endometrial hyperplasia. A very small percentage of women with endometrial hyperplasia go on to develop endometrial cancer.

Carcinoma

Almost all (95%) cases of endometrial carcinoma present as abnormal uterine bleeding or unscheduled postmenopausal bleeding (PMB). In women with PMB, a well-defined endometrium measuring 5mm or less is unlikely to be cancerous ([Wolfman 2018](#)).



There is no agreed consensus on reference values for predicting endometrial cancer ([Saccardi et al., 2021](#)). Some centres use a threshold of 4mm in symptomatic postmenopausal women and 11mm in asymptomatic postmenopausal women ([Alcázar et al., 2018](#); [Wolfman 2018](#) and [Morrison et al., 2022](#)). Therefore, it is important to agree endometrial thickness cut-offs and PMB protocols locally with clinicians.

Polyps

These benign growths are common in pre- and postmenopausal women. Most are asymptomatic but may present with intermenstrual bleeding or PMB. In cases of thickened endometrium and a suspected polyp, it is often helpful to rescan premenopausal patients during the proliferative phase.

Ultrasound appearance:

- focal endometrial thickening or a hyperechoic mass within the endometrial cavity

- low velocity flow colour Doppler may identify a 'feeder vessel' supplying the polyp



When a thickened endometrium is discovered as an incidental finding, see the BMUS document [Incidental findings](#).

Asherman syndrome

This condition involving scar tissue/adhesions in the uterine cavity may be seen in women with a history of severe pelvic infection or repeated dilatation and curettage procedures. Presentation includes pain, dysmenorrhoea and subfertility.

On ultrasound there may be foci of increased echogenicity in the border between the endometrium and the myometrium (junctional zone). Fibrous connections, or synechiae, may be seen to criss-cross the uterine cavity.

5.1.1.3 Ovaries

Simple cyst

Simple ovarian cysts are common, and in premenopausal women, most are physiological. The ultrasound appearance is of a well-defined, anechoic, unilocular cyst with thin, smooth walls and good through transmission of sound. Most are asymptomatic, are managed conservatively and resolve spontaneously.

Haemorrhagic cyst

Ultrasound appearances vary depending on the time of the event causing haemorrhage, but these cysts are commonly homogeneous with thin fibrous internal strands initially, which become heterogeneous as clots form and then retract. Patients often present with adnexal pain.

Ovarian torsion

Ultrasound appearances are complex and may develop over time. They include:

- Enlarged, congested, oedematous ovary demonstrating follicles displaced to the periphery
- Appearance of a complex adnexal mass
- Reduced or, in cases of intermittent torsion, transient vascular perfusion
- Ischaemia, infarction
- Free fluid in the pelvis

Polycystic ovarian morphology (PCOM) and polycystic ovary syndrome (PCOS)

PCOS is a syndrome of ovarian dysfunction with multiple clinical signs including menstrual irregularities, menstrual infrequency, signs of androgen excess (hirsutism, acne), and obesity. No single diagnostic criterion, such as hyperandrogenism or ovaries with sonographic polycystic appearances, is sufficient for clinical diagnosis ([International Evidence-based Guideline for the assessment and management of polycystic ovary syndrome 2023](#)). There are challenges in the diagnosis of PCOS and the aim should be to prevent over-diagnosis on the strength of ultrasound features especially in the adolescent age group. Therefore, ultrasound is not indicated in adolescents within 8 years of onset of menarche, due to overlap with normal reproductive physiology ([NICE, 2018 PCO: What investigations should I arrange?; International Evidence-based Guideline for the assessment and management of polycystic ovary syndrome 2023](#)).

Two of the following three criteria are required for a diagnosis of PCOS ([International Evidence-based Guideline for the assessment and management of polycystic ovary syndrome 2023](#)):

- Oligo- or anovulation
- Clinical and/or biochemical signs of hyperandrogenism
- Features of polycystic ovarian morphology (PCOM) on ultrasound or elevated anti-mullerian hormone (AMH) levels, after other causes of these features are excluded

Further recommendations from the [International Evidence-based Guideline for the assessment and management of polycystic ovary syndrome \(2023\)](#) may be helpful, and include the following:

1. TV is the preferred method for the diagnosis of PCOM, subject to appropriate consent.
2. Using TVS with a frequency bandwidth that includes 8MHz, PCOM can be diagnosed when:
 - ≥ 20 follicles present on either or both ovaries and/or
 - ovarian volume $\geq 10\text{ml}$ if no corpora lutea, cysts or dominant follicles are present.
3. In patients with irregular menstrual cycles and hyperandrogenism, an ovarian ultrasound is not necessary for PCOS diagnosis; however, ultrasound will identify the complete PCOS phenotype.
4. In TA ultrasound, reporting is best focused on ovarian volume with a threshold of $\geq 10\text{ml}$, given the difficulty of reliably assessing follicle number with this approach.
5. Clear protocols are recommended for reporting follicle number per ovary and ovarian volume on ultrasound. Recommended minimum reporting standards include:
 - Last menstrual period (LMP)
 - Transducer bandwidth frequency
 - Approach/route assessed
 - Total follicle number per ovary measuring 2–9mm
 - Three dimensions or volume measurement of each ovary
 - Other ovarian and uterine pathology, as well as ovarian cysts, corpus luteum, dominant follicles $\geq 10\text{mm}$
 - Where a dominant follicle is seen, the follicle count of the contralateral ovary can be used for diagnosis
 - Appearances of the uterus, endometrium and endometrial thickness

Ovarian masses

Ultrasound has an important role to play in managing a suspected ovarian mass. According to NICE, 2011 [Ovarian cancer: recognition and initial management](#), if the woman has a serum CA125 value of 35 IU/ml or greater, an ultrasound scan of the abdomen and pelvis should be requested.

- A combination of TV and TA assessment may be appropriate for the evaluation of larger masses and extra-ovarian disease.
- Use of colour Doppler has generally not been shown to significantly improve diagnostic accuracy.
- Combined use of the TV route in combination with colour Doppler and 3D imaging may improve sensitivity, particularly in complex cases.

TABLE 1: [Ovarian masses in premenopausal women](#)

Ovarian masses in premenopausal women <i>Agree all protocols with local clinicians but the following information may be helpful.</i>	
Description	Suggested management (From RCOG GG62)
Simple. Less than 30mm diameter. No septations or a single thin septation of less than 3mm thick. No or minimal calcification in the wall.	Almost certainly physiological. No follow-up required.
Simple. Measuring 30–49mm.	Almost certainly benign. No follow-up required.
Simple. Measuring 50–70mm.	Almost certainly benign. Yearly ultrasound follow-up. If cyst is reduced in size at the next scan, no further follow-up. If unchanged or larger, gynaecological referral suggested.
Simple. Measuring more than 70mm.	Consider MRI and gynaecological referral/surgical intervention.
Features suggesting dermoid cyst (mature cystic teratoma): solid foci, fluid layering, shadowing and/or 'mesh' appearance, measuring >50mm.	Consider gynaecological referral/surgical intervention.
Complex mass which is indeterminate or solid, multilocular, thick vascular septation, papillary nodules (+/- vascularity). Ascites may be present.	Tumour markers and gynaecological referral.



Incidental finding of premenopausal and postmenopausal ovarian cysts:
see the BMUS document [Incidental findings](#).

TABLE 2: [Ovarian masses in postmenopausal women](#)

Ovarian masses in postmenopausal women <i>Agree all protocols with local clinicians but the following information may be helpful.</i>	
Description	Suggested management (From RCOG GG34)
Asymptomatic, simple, unilateral, unilocular, <50mm.	<p>Low risk of malignancy.</p> <p>If the CA125 serum value is normal, 4–6-monthly ultrasound surveillance for 1 year.</p> <p>If cyst is unchanged or smaller at the end of this time, and CA125 remains normal, the woman may be discharged.</p>
Persistent complex adnexal mass – solid, multilocular, focal thickening.	Gynaecological referral.

[The International Ovarian Tumour Analysis \(IOTA\) group](#) has developed some simple ultrasound ‘easy descriptors’. These can be used to classify masses as more likely benign (B-rules) or more likely malignant (M-rules). Refer to the [IOTA Plus website](#) or to the RCOG (2011) [Ovarian Masses in Premenopausal Women, Management of Suspected \(Green-top Guideline No. 62\)](#).

B-rules ([IOTA](#))

- Unilocular cysts
- Presence of solid components where the largest solid component <7mm
- Presence of acoustic shadowing
- Smooth multilocular tumour with a largest diameter <100mm
- No blood flow

M-rules ([IOTA](#))

- Irregular solid tumour
- Ascites
- At least four papillary structures
- Irregular multilocular solid tumour with largest diameter ≥100mm
- Very strong blood flow

Further information on managing ovarian cancer can be found in NICE (2011, updated 2023) guidelines [Ovarian cancer: recognition and initial management](#).

Adnexal masses

Adnexal masses include pelvic abscess and/or pyo- and hydrosalpinx. Ultrasound appearances include incomplete septation from dilated serpinous Fallopian tubes, cog-wheel appearance in cross-section, debris and low-level echoes within.

Extending the examination

The ultrasound practitioner may consider proceeding to an abdominal ultrasound examination when indicated. For example, when a large pelvic mass has been found, hydronephrosis of the kidneys and/or abdominal ascites will need to be considered.



See additional online resources at:

- 15_01 - [Gynaecological Ultrasound: Introduction and Image Optimisation](#)
- 15_02 - [Gynaecological Ultrasound: Children and Adolescents](#)
- 15_03 - [Gynaecological Ultrasound: The Uterus](#)
- 15_04 - [Gynaecological Ultrasound: The Ovaries and Adnexa](#)
- 15_05 - [Gynaecological Ultrasound: The Menstrual Cycle](#)
- 15_06 - [Gynaecological Ultrasound: Normal Early Pregnancy](#)
- 15_07 - [Gynaecological Ultrasound: Abnormal Early Pregnancy](#)
- 15_08 - [Gynaecological Ultrasound: Postmenopausal Pelvis](#)
- 15_09 - [Gynaecological Ultrasound: Fertility](#)

5.1.2 Pelvic ultrasound reporting examples

Referral for PMB

Clinical details: Age 57 years. Approx. 6 years post-menopause – intermittent bleeding for 1 month.

Transabdominal and transvaginal scans of the pelvis performed with verbal consent. Chaperone XX present:

No previous relevant imaging. The uterus is normal in size but there is a 6mm x 4mm polyp within the endometrium. The endometrial thickness is 3mm and the uterine cavity is distended by 4mm of fluid.

No other abnormality detected. Both ovaries are of normal appearance.

Conclusion:

Appearances suggest endometrial polyp, otherwise normal uterus and ovaries.

Referral for pelvic pain with palpable mass

Clinical details: 25 days post-LMP. Irregular cycle 4–6 weeks. Intermittent pain and O/E pelvic mass.

Transabdominal and transvaginal scans of the pelvis performed with verbal consent. Chaperone, Mrs. XX, Imaging Assistant, was present during examination with patient's consent:

Anteverted uterus containing several submucosal fibroids on the anterior wall, the largest of which is Xmm in diameter. The endometrium is not clearly visualised. Ultrasound appearances of both ovaries are normal (corpus luteum noted in the left ovary).

Conclusion:

Fibroids.

Referral for deep dyspareunia

Clinical details: LMP – unsure ?6 weeks ago. Irregular cycle. Complains of deep dyspareunia of 2 months' duration.

Transabdominal ultrasound of the pelvis performed with verbal consent. Transvaginal scan declined. Chaperone XX present:

Note is made of the pelvic scan performed 2 years ago showing normal appearances

Normal anteverted uterus and endometrium, with endometrial thickness Xmm. Ultrasound appearances of the left ovary and adnexa are normal. The right ovary has normal ultrasound appearances. Adjacent to the right ovary is a complex tubular structure measuring Y x Y x Ymm and containing low-level echoes. Small volume of fluid noted in the rectouterine pouch.

Conclusion:

Appearances consistent with pyosalpinx or tubo-ovarian abscess.

Further information can be found at:

- [BSGI](#)
- [GynaecologyUltrasound.com](#)
- [IOTA](#)
- [ISUOG](#)
- [NICE](#)
- [RCOG](#)

The YouTube channel [Gynaecology Ultrasound](#) contains many short gynaecology ultrasound videos, containing still images and ultrasound video clips, on a wide range of subjects including ovarian masses, PMB and a 'case of the week'. If you subscribe to the YouTube channel, you will receive an email alert every time a new video is uploaded.

5.2 Abdominal ultrasound examinations

[updated 2021]

General scanning principles

The ultrasound practitioner should tailor the examination according to the clinical presentation. The emphasis of examination of the abdominal structures may be altered according to the clinical scenario, previous imaging findings and patient history. If targeted ultrasound is performed, this should be documented within the report, making explicit which structures have and have not been examined.

All abdominal organs should be examined in a minimum of two planes, i.e. longitudinal section (LS) and transverse section (TS), with additional views as required. The purpose of the scan is to survey the entire organ, where possible, with representative images of normality and any pathology, focal or diffuse, being taken. Age-related appearances and normal variants need to be recognised. Any tenderness found during a scan should be stated in the report. The absence of tenderness should also be documented where relevant, e.g. negative sonographic Murphy's sign.

TABLE 3: Structures for an abdominal ultrasound examination

Structures	Details for evaluation
Liver	Size, shape, contour and ultrasound characteristics of all segments, appearance of intrahepatic vessels and ducts
Gallbladder	Good visualisation of neck, body and fundus. Size, shape, outline and surrounding area. Ultrasound characteristics of the wall and the nature of any contents
Common duct	Maximum diameter and contents; optimally it should be visualised from porta to head of pancreas
Pancreas	Size, shape, outline and ultrasound characteristics of head, uncinate process, body, tail and main duct
Spleen	Size, shape, outline and ultrasound characteristics including the hilum. Assessment of splenic vein blood flow and presence/absence of collateral vessels
Aorta	Diameter, course and main branches including the bifurcation, appearance of its walls, lumen and para-aortic regions
Inferior vena cava	Patency, diameter, appearance of its lumen and para-caval regions
Adrenals	Not routinely viewed but any apparent abnormality of size and ultrasound characteristics should be noted
Kidneys	Size, shape, position and orientation, outline and ultrasound characteristics of cortex, medulla, collecting system
Urinary bladder	Appearance of wall and contents. Assessment of volume pre- and post-micturition when indicated +/- TA assessment of prostate gland
Other structures	When clinically indicated, evaluation may include abdominal wall, possible hernias, lymph nodes, appendix and sites for potential fluid collection

5.2.1 Reporting examples

General principles of reporting apply and reference is made to the reporting section of this document ([ref: section 4.5](#)).

Sample abdominal ultrasound reports

Outlined below are sample reports for various common clinical scenarios. These are provided as guidance with the aim of standardising and improving reporting skills in this important field of practice.

Referral for upper abdominal pain

Clinical details: RUQ pain with occasional vomiting and fatty intolerance, ?gallstones.

Upper abdominal ultrasound performed with verbal consent:

Normal liver.

The gallbladder is tender, has a thickened, oedematous wall and contains several stones. The CBD is dilated measuring 9mm, but the lower end of the duct is not demonstrated due to overlying duodenal gas. No intrahepatic duct dilatation.

The pancreas is poorly visualised, despite a water load.

Normal spleen, both kidneys and abdominal aorta.

Conclusion:

Acute cholecystitis with gallstones and a dilated common bile duct. The lower end of the duct is not seen and MRCP is advised as the next step.

Referral for painless jaundice

Clinical details: Painless jaundice. Bilirubin 400 $\mu\text{mol/L}$.

Upper abdominal ultrasound performed with verbal consent:

There is intrahepatic duct dilatation around the porta hepatis and into the left lobe of liver. The liver otherwise appears normal. Although no liver lesions are seen on this baseline scan, a non-contrast scan does not exclude the presence of metastases.

The gallbladder is non-tender and contains some small stones.

The CBD is dilated measuring 10mm down to the head of pancreas, where there is a 20mm mass.

The pancreatic duct distal to the mass is also dilated at 4mm.

No ascites or peripancreatic fluid demonstrated.

Conclusion:

20mm mass in the head of the pancreas causing biliary obstruction. This is likely to be malignant. Urgent cross-sectional imaging advised for staging.

Report fast-tracked to referring clinician (...or pancreatic MDT informed, or similar)

Referral for left sided discomfort

Clinical details: Stone former with H/O lithotripsy. Normal LBTs. Left flank pain for last 6 weeks.

Upper abdominal ultrasound performed with verbal consent:

The liver, pancreas, spleen and both kidneys look normal. No evidence of renal stones or hydronephrosis. The abdominal aorta is a normal calibre. The gallbladder and biliary tree are unremarkable.

Conclusion:

No cause found for left sided pain.

5.2.2 The liver

General scanning principles

Liver disease is common, and ultrasound is frequently requested for a range of hepatic conditions both for initial diagnosis and for surveillance/follow-up. Best practice requires ultrasound to be used in context with relevant clinical history, so it may be helpful to refer to the [BMUS Justification of ultrasound requests](#) when determining if liver ultrasound is the most appropriate imaging modality for yielding an answer to the clinical question posed.

Technique

Full examination of the liver requires subcostal scanning from both supine and left decubitus patient positions, on arrested respiration if possible. Real-time repeated 'sweeps' in TS and LS as well as supplementary intercostal access are best for visualising the liver in its entirety. Images to be saved are dependent on local protocols but, as a minimum, should include left lobe, right lobe, the hepatic veins draining to the inferior vena cava (IVC) and the portal vein at the liver hilum.

Size

Use of formal liver measurements is controversial as alterations in liver volume may not be reflected in isolated measurements. Moreover, body habitus influences liver size and shape. Early enlargement may be more sensitively identified by the blunting of the free inferior edge of the right lobe. Variation in size of liver segments should be documented, e.g. enlargement of the caudate lobe (segment 1) in established cirrhosis.

Echotexture

Normal liver is uniform and minimally hyperechoic or isoechoic compared to normal renal cortex. Where abnormality is suspected, or diffuse liver disease is the clinical indication for the scan, a comparison image of liver and right kidney should be stored. Focal liver lesions should be described in terms of their size, outline, echogenicity, vascularity and location.

Note: Incidental findings of liver haemangiomas are common. See the BMUS document [Incidental findings](#) for recommendations on management.

Where the liver texture appears hyperechoic (fatty), the following should be considered:

- Loss of signal in deep liver due to increased attenuation
- Loss of prominence of intrahepatic portal vein branch walls
- Altered liver surface (steatosis and fibrotic change often coexist)
- Colour and spectral Doppler analysis of portal and hepatic veins

Vascularity

If the liver texture is diffusely abnormal, or if portal hypertension or chronic hepatitis is on the request, Doppler studies of the portal vein and hepatic veins should be obtained. Normal lower-range peak velocity in the main portal vein is 12cm/s in the fasted patient. Higher velocities are not generally of significance except in liver transplants, where it may indicate vessel stenosis and needs reporting if above 40cm/s (mean flow velocity).

Normal waveform of hepatic veins is triphasic. Bi- or monophasic flow indicates a loss of liver elasticity, but this is a non-specific sign present in other liver conditions. Elastography is useful in assessing the liver stiffness ([ref: section 6.1](#)). Highly pulsatile waveforms in both or either the portal vein or selected hepatic vein may be related to cardiac problems and should be reported as it may be suggestive as a cause for abnormal liver blood tests (LBTs), formerly known as liver function tests (LFTs) ([British Liver Trust](#)).

5.2.2.1 Common clinical scenarios

Diffuse liver disease

Hepatic steatosis

The liver can appear hyperechoic (focal or diffuse) when extra lipid (fat) deposits are stored in the hepatocytes of the liver (steatosis/fatty change). It can be caused by alcohol- or non-alcohol-related

factors, including diabetes mellitus, medication, obesity and pregnancy. Liver echogenicity can be compared with the normal renal cortex and/or spleen and by assessing the reduction in prominence of the periportal tracts and diaphragm.

In the absence of a quantifiable method of diagnosing and reporting steatosis being available, it is important to include details such as the following, with or without the use of a grading system:

- Slight, diffuse increase in echogenicity of the liver. Normal appearance of the diaphragm and portal vein walls (mild/score 1).
- Increased echogenicity of the liver causing slight difficulty in differentiating the portal vein walls and diaphragm (moderate/score 2).
- Hyperechoic liver with limited or no visualisation of the portal vein walls or diaphragm. Attenuation of sound causing limited views of the posterior aspect of the liver (severe/score 3). ([Ferraioli and Soares Monteiro., 2019](#))

Cirrhosis

[Updated 2025]

Fibrosis of the liver can be caused by end-stage hepatitis and cirrhosis. There are two main types:

- Micronodular, which gives a coarse echotexture
- Macronodular, which is seen as discrete (>10mm) nodules

Liver enlargement may be seen in the early stages, while reducing in later stages.

A range of appearances and complications can be seen with ultrasound, depending on the stage and extent of disease. These include:

- Surface nodularity (high-frequency transducer can be helpful)
- Dampening of the hepatic vein waveform
- Portal hypertension, including some/all: reduced or hepatofugal (reverse) flow in the portal vein, collateral vessels, ascites, splenomegaly, varices

Ultrasound is used for hepatocellular carcinoma (HCC) surveillance in patients with cirrhosis ([NICE, 2016 Cirrhosis in over 16s: assessment and management](#)). Elastography ([ref. section 6.1](#)) and contrast-enhanced ultrasound (CEUS) ([ref. section 6.2](#)) can be helpful in the diagnosis and management of patients with cirrhosis. NHS England published [Hepatocellular carcinoma surveillance: minimum standards](#) (2024) with recommendations to support the provision of a quality ultrasound service for HCC surveillance.

HCC ultrasound surveillance scans ([NHSE, 2024, updated 2025](#))

- Should be offered to eligible patients at 6-monthly intervals
- Should be carried out by an “appropriately trained, competent and experienced” ultrasound practitioner
- Should focus on “identifying HCC and the complications of liver disease,” so do not need to include routine upper abdominal assessment of other organs such as the aorta and renal tract.
- Should ideally be reported using standardised, structured reports including the [Liver Imaging Reporting and Data System](#) (LI-RADS) ultrasound surveillance classification.
- Should “include standardised image and video capture to enable retrospective review and support interpretation of subsequent imaging examinations.”

Focal liver lesions

Focal liver lesions can be assessed using B-mode, colour Doppler and CEUS. A basic overview of B-mode appearances of some common focal hepatic lesions is given in Table 4.

TABLE 4: Focal liver lesions: ultrasound appearance

	Appearance	Comments
Cysts	Well-defined, thin-walled, anechoic with posterior enhancement.	If multiple cysts, check the kidneys for associated cysts in polycystic kidney disease. CEUS no enhancement. Often clearer in the late phase due to normal liver enhancement.
Haemangioma	Well-defined, hyperechoic (smaller lesions) or hypoechoic or heterogeneous (larger lesions).	Can be single or multiple. CEUS centripetal filling.
Adenoma	Well-defined, homogeneous, isoechoic (smaller) or hyperechoic. Heterogeneous (larger lesions). Peripheral vascularity may be seen with colour Doppler. May see haemorrhage, necrosis or calcification.	Dietrich <i>et al.</i>, 2019. Often need CEUS or other cross-sectional imaging to diagnose.
Focal nodular hyperplasia (FNH)	Well-defined, solitary, isoechoic. Can be slightly hyperechoic or hypoechoic. Some have hyperechoic central scar visible.	Often need CEUS or other cross-sectional imaging to diagnose. CEUS 'spoke and wheel' type filling.
Metastases	Various appearances. Hyperechoic, isoechoic, hypoechoic or target lesions. May have necrosis or calcification.	Can be single or multiple. Can be diffuse, giving a heterogeneous appearance of the liver. Look for mass effect, deviation of vessels within the liver, to help identify isoechoic lesions.
HCC	Various appearances, including hyperechoic, isoechoic or heterogeneous vascular lesions.	



See additional online resources at:

- 16_06 - [Abdominal Ultrasound: The Liver - Session 1](#)
- 16_07 - [Abdominal Ultrasound: The Liver - Session 2](#)

5.2.2.2 Liver ultrasound reporting examples

Referral for HCC surveillance

Clinical details: Known advanced chronic liver disease. For 6 monthly HCC surveillance.

Comparisons made with ultrasound scan on X/X/XXXX

Visualisation A: No or minimal limitations

Transabdominal liver ultrasound performed with verbal consent:

Background liver: Macronodular liver parenchyma.

Patent hepatic veins. Portal vein is patent with normal hepatopetal flow, 20cm/s.

Focal hepatic observations: A 15mm well defined hypoechoic lesion seen in segment 6 (LI-RADS score US-3)

Extrahepatic:

No ascites, splenomegaly, lymphadenopathy.

Please note that this was performed as a focused scan, as such the remaining abdomen (pancreas, kidneys, aorta) have not been assessed.

Conclusion:

Single US-3 observation, further contrast enhanced imaging [CEUS/MRI/CT] is required.

Clinical team informed.

Referral for liver lesion assessment

Clinical details: focal liver lesion on CT scan, ?nature.

Upper abdominal ultrasound performed with verbal consent:

A recent CT KUB demonstrates a 4cm liver lesion in segment 6. This is confirmed on ultrasound to be a hyperechoic solid lesion. No other liver lesions are identified.

2mls of xxx contrast agent administered. No known contra-indications.

The lesion demonstrates peripheral nodular arterial enhancement with rapid centripetal filling and good contrast take-up in the sinusoidal phase.

Conclusion:

Benign incidental haemangioma of no clinical significance. The liver is otherwise normal.

Referral for abnormal LBTs

Clinical details: *Palpable liver edge with abnormal LBTs, H/O alcohol abuse. Smoker. (Additional information from patient records: AST xxx, ALT xxx, Bili xxx.)*

Upper abdominal ultrasound performed with verbal consent:

Fatty liver with small areas of fatty sparing in segments 4 and 8. No other focal lesions identified but the liver texture is diffusely nodular and the liver capsule is irregular.

The non-tender gallbladder is contracted and contains several stones. No biliary duct dilatation.

Enlarged spleen – 16cm.

Patent portal and splenic veins with hepatopetal flow.

Normal CBD, pancreas, both kidneys and abdominal aorta. No abdominal or pelvic ascites.

Conclusion:

Probable cirrhosis with signs of portal hypertension. Referral to a hepatologist is recommended.

Further information can be found at:

- Durot, I., Wilson, S.R., and Willmann, J.K. (2018). Contrast-enhanced ultrasound of malignant liver lesions. *Abdom. Radiol.* 43, 819–847. Available at: <https://doi.org/10.1007/s00261-017-1360-8>
- Hertzberg, B., and Middleton W. (2015). *Ultrasound: The Requisites*, 3rd ed. (Elsevier).
- National Institute for Health and Care Excellence (NICE) (2015, updated 2020). [Suspected cancer: recognition and referral](#)
- Penny, S. (2018). *Examination review for ultrasound: Abdominal & Obstetrics and Gynecology* (Wolters Kluwer).
- Riestra-Candelaria, B., Rodríguez-Mojica, W., Vázquez-Quiñones, L., and Jorge, J.C. (2016). Ultrasound Accuracy of Liver Length Measurement with Cadaveric Specimens. *J. Diagn. Med. Sonogr.* 32(1), 12–19. Available at: [10.1177/8756479315621287](https://doi.org/10.1177/8756479315621287)

5.2.3 The gallbladder and biliary tree

Gallbladder

General scanning principles

The gallbladder is normally situated inferior to the right lobe of the liver. Its size and shape vary. The gallbladder neck usually sits in the gallbladder fossa. The fundus is mobile and dependent on patient position.

Technique

The gallbladder is best seen with the patient in the left decubitus position and after a period of fasting (drinking clear fluids only) to aid distension. It should be examined in at least two patient positions, for example supine and left decubitus, left posterior oblique and/or erect, to establish movement of any contents and to ensure visualisation of the entire organ. It is good practice to examine the gallbladder along both its long and transverse axes.

The shape and measurements of the gallbladder vary greatly but it is normally pear-shaped when dilated, with a narrow neck and widening towards the fundus. A very rounded shape may imply tense dilatation. Some gallbladders may be folded or have a Phrygian cap at the fundus. These shapes can conceal small stones if care is not taken to 'unfold' the organ, by moving the patient, and examine it comprehensively.



A high-frequency linear transducer may provide greater resolution when the gallbladder is very superficially located.

The gallbladder neck often has a 'J' or reversed 'J' shape, and attention should be paid to this area to identify pathology such as trapped stones. The wall should be thin (no more than 3mm), smooth and well-defined. Measurements of wall thickness should ideally be taken from the anterior wall when perpendicular to the beam. Here, the image contains fewer artefacts and the measurement is reproducible. The bile contained in the gallbladder should be anechoic.

In patients with right upper quadrant (RUQ) pain, the transducer may be used to gently probe the exact site of the pain (termed 'sonographic Murphy's sign'). This information may be useful in confirming a diagnosis of acute cholecystitis. Gallstones are frequently asymptomatic, so it should not be assumed that the finding of gallstones establishes the cause of pain and a full scan should always be conducted.



Equipment settings: Applying harmonic imaging reduces unhelpful artefacts within the gallbladder, but remember to remove spatial compounding, otherwise posterior shadowing from small stones hidden in the neck may be lost.



Gallbladder polyps may be managed safely using the BMUS document [Incidental Findings](#).

Bile ducts

Technique

The common duct (CD) normally lies anterior to the main portal vein and is best imaged at this point using the liver as an acoustic window and the beam perpendicular to the vein. The duct should then ideally be traced distally to the head of pancreas. As with the gallbladder, superior views are usually obtained with the patient in a left decubitus position. Duodenal gas can sometimes compromise the view but may be moved by altering patient position and/or applying gentle pressure with the transducer and/or revisiting the area after a short time interval.

The measurement is from inner lumen wall to inner lumen wall, measured at the porta hepatis. Duct measurements should be taken in clinical context with reference to previous history, including cholecystectomy and LBTs.

The normal CD diameter is variable, but the upper limit of normal calibre is generally accepted as 6mm in an adult. This can increase after cholecystectomy and in older adults due to loss of elasticity of the duct wall. Individual ultrasound departments may choose to use different parameters for normal bile duct size dependent on the trade-off between sensitivity and specificity for biliary pathology. However, it is recommended that departments should collaborate with local biliary surgeons where significant deviance from accepted normal range is proposed.

Abnormal bile ducts

Bile duct wall thickening is an abnormal sign, even in the absence of dilatation, and is frequently associated with cholangitis or cholestatic disease.

It is difficult to demonstrate normal intrahepatic ducts past the first order of duct (right and left hepatic ducts) but they can be seen with good equipment in young, slim patients and should not be confused for intrahepatic duct dilatation. Comparison should be made with the accompanying veins. In health, the bile duct is narrower than the parallel portal vein.

In cases of intrahepatic duct dilatation, efforts should be made to establish the cause by tracing the system down to the point of obstruction. Isolated segments of intrahepatic duct dilatation, with a normal calibre extrahepatic biliary tree, raises the possibility of serious disease such as primary sclerosing cholangitis or cholangiocarcinoma. MRI is useful for further evaluation.



In cases of extrahepatic biliary dilatation of unknown cause, a second look at the head of pancreas may reveal a stone or mass missed on the initial assessment earlier in the examination.

Further information can be found at:

- Hertzberg, B.S., and Middleton W.D. (2016). *Ultrasound: The Requisites*, 3rd ed. (Elsevier).
- Hilsden, R., Leeper, R., Koichopolos, J., Vandelinde, J.D., Parry, N., Thompson, D., and Myslik, F. (2018). Point-of-care biliary ultrasound in the emergency department (BUSED): implications for surgical referral and emergency department wait times. *Trauma Surg. Acute Care Open* 3, 164. Available at: <http://tsaco.bmj.com/>
- Lal, N., Mehra, S., and Lal, V. (2014). Ultrasonographic measurement of normal common bile duct diameter and its correlation with age, sex and anthropometry. *J. Clin. Diagn. Res.* 8, AC01-4. Available at: <http://www.ncbi.nlm.nih.gov/pubmed/25653927>
- Patel, K., Dajani, K., Vickramarajah, S., and Huguet, E. (2019). Five-year experience of gallbladder polyp surveillance and cost effective analysis against new European consensus guidelines. *HPB* 21(5), 636–642. Available at: <https://doi.org/10.1016/j.hpb.2018.10.008>
- Penny, S.M. (2018). *Examination review for ultrasound. Abdomen & obstetrics and gynecology* (Wolters Kluwer).
- Revzin, M.V., Scoutt, L.M., Garner, J.G., and Moore, C.L. (2017). Right Upper Quadrant Pain: Ultrasound First! *J. Ultrasound Med.* 36, 1975–1985. Available at: <https://onlinelibrary.wiley.com/doi/full/10.1002/jum.14274>



elearning for healthcare

See additional online resources at:

- 16_08 - [Abdominal Ultrasound: The Gallbladder and Biliary Tree - Session 1](#)
- 16_09 - [Abdominal Ultrasound: The Gallbladder and Biliary Tree - Session 2](#)

5.2.4 The pancreas

General scanning principles

The clinical features of pancreatic disease are often non-specific, including vague epigastric pain sometimes radiating to the back, anorexia and weight loss. Ultrasound may be appropriate initially due to overlap with other conditions such as gallbladder disease. However, when clinical suspicion is high for pancreatic disease, CT and MRI should be the principal imaging modalities. Conventional ultrasound has a significant false negative rate for detecting serious pancreatic disease (Ashida *et al.*, 2019). However, when the pancreas is seen well, ultrasound may give better detail than CT or MRI and can be used for problem solving.

The practitioner should always seek to scan the entire pancreas in all general upper abdominal examinations. The gland should be imaged in transverse and longitudinal planes.

The normal pancreas is slightly hyperechoic compared with the liver and this generally increases with age-associated loss of glandular elements and increasing fibrofatty proliferation. The size of the pancreas is variable and is not routinely measured in practice. There is lack of consensus on pancreatic ductal diameter (Penny, 2018; Hertzberg and Middleton, 2015), but in general it is widest in the head (<3.5mm) tapering to <2.5mm in body and <1.5mm in the tail. Age-associated duct ectasia is seen commonly and may exceed 4mm in a significant proportion of older people (Matsuda, 2019). Therefore, when an apparently dilated duct is encountered, careful survey is required for the presence of obstructing mass, calcifications or focal dilatation that may suggest intraductal papillary mucinous neoplasm (IPMN).

Technique

Fasting for 4 to 6 hours to reduce bowel gas improves visibility of the pancreas, as does the use of graded compression, supplementing supine scanning with decubitus or erect positions, and different phases of respiration.

Technique adjustments which may aid visualisation of the pancreas include:

- Using the left lobe of liver as an acoustic window on suspended inspiration
- Scanning in decubitus and/or erect positions
- Intercostal scanning through the spleen to image the pancreatic tail
- Giving water orally to create an acoustic window in the gastric antrum – take care to avoid microbubbles from tap water; turning the patient to the right following ingestion will help to fill the antrum and duodenal loop
- Asking the patient to push out their abdomen against the transducer

Structures to examine and evaluate

The entire gland should be identified where possible, noting texture, size and contour, pancreatic duct and CBD. Further structures for assessment include splenic vein, superior mesenteric vein, portal vein, coeliac axis and superior mesenteric artery.

5.2.4.1 Common clinical scenarios

Acute pancreatitis

While an enlarged/swollen pancreas is a classic sonographic feature of acute pancreatitis, the pancreas may appear sonographically normal or difficult to visualise in the acute setting. Acute peripancreatic phlegmon may not be appreciated and is better assessed with CT as is necrosis, although CEUS can be used. The main utility of ultrasound is to assess for aetiological factors, particularly gallstones, CBD dilatation and sequelae such as fluid collections, pseudocysts, venous thrombosis or pseudoaneurysm formation ([Burrowes et al., 2019](#)).

Chronic pancreatitis

This may result from repeated cycles of acute pancreatitis or develop occultly and is often associated with alcohol consumption. Other causes include autoimmune conditions or obstruction of the pancreatic or common bile duct. Typical appearances commonly include atrophy, calcifications, ductal dilatation and calibre variation of main duct and side branches ([Engjom et al., 2017](#); [Singh et al., 2019](#)).

Pancreatic tumours

Pancreatic cancer is the seventh leading cause of cancer-related deaths in the world and has a slightly higher prevalence in men than in women ([Rawla et al., 2019](#)). Five-year survival remains low at 9%, predominantly due to late presentation, and pre-existing pancreatitis is a serious risk factor for pancreatic cancer ([Rawla et al., 2019](#)). CT and MRI are used primarily for staging, although tumours may be recognised during ultrasound assessment.



If a tumour is identified with dilatation of the biliary tree, urgent CT evaluation should be performed, as operative risks increase with raised bilirubin/jaundice.

The majority of lesions (75%) occur in the pancreatic head, are generally hypoechoic on ultrasound and are often accompanied by pancreatic duct and/or biliary duct dilatation (double duct sign). Most pancreatic tumours are adenocarcinomas (90%+), with cystic neoplasms and [IPMNs](#) increasingly recognised. Other tumours include neuroendocrine and mesenchymal lesions.

IPMNs are often incidental findings on ultrasound, MRI and CT. Typical appearances are those of side branch or main ductal anechoic structures with ultrasonic detection improved if >10mm ([Valdivia et al., 2018](#)). Therefore, they may appear as 'simple cysts' communicating with the pancreatic duct, as focal dilatation of the main duct or as more complex cystic structures. If there is no history of pancreatitis, new discovery of cystic lesions in the pancreas requires review at hepatobiliary MDT.

Endoscopic ultrasound may be used for evaluation and cyst fluid aspiration ([Jeon et al., 2018](#)), although ultrasound has been advocated as part of a follow-up programme ([Morelli et al., 2019](#)).



If ultrasound demonstrates suspected inflammation or a mass, use Doppler to verify the patency of the splenic and portal vein.

See additional online resources at:

- 16_04 - [Abdominal Ultrasound: Pancreas - Session 1](#)
- 16_05 - [Abdominal Ultrasound: Pancreas - Session 2](#)

Further information can be found at:

- Hertzberg, B.S., and Middleton W.D. (2016). *Ultrasound: The Requisites* 3rd ed. (Elsevier).
- Hilsden, R., Leeper, R., Koichopolos, J., Vandelinde, J.D., Parry, N., Thompson, D., and Myslik, F. (2018). Point-of-care biliary ultrasound in the emergency department (BUSED): implications for surgical referral and emergency department wait times. *Trauma Surg. Acute Care Open* 3, 164. Available at: <http://tsaco.bmj.com/>
- Lal, N., Mehra, S., and Lal, V. (2014). Ultrasonographic measurement of normal common bile duct diameter and its correlation with age, sex and anthropometry. *J. Clin. Diagn. Res.* 8, AC01-4. Available at: <http://www.ncbi.nlm.nih.gov/pubmed/25653927>
- Patel, K., Dajani, K., Vickramarajah, S., and Huguet, E. (2019). Five-year experience of gallbladder polyp surveillance and cost effective analysis against new European consensus guidelines. *HPB* 21(5), 636–642. Available at: <https://doi.org/10.1016/j.hpb.2018.10.008>
- Penny, S.M. (2018). Examination review for ultrasound. *Abdomen & obstetrics and gynecology* (Wolters Kluwer).
- Revzin, M.V., Scoutt, L.M., Garner, J.G., and Moore, C.L. (2017). Right Upper Quadrant Pain: Ultrasound First! *J. Ultrasound Med.* 36, 1975–1985. Available at: <https://onlinelibrary.wiley.com/doi/full/10.1002/jum.14274>

5.2.5 The spleen

General scanning principles

The spleen is homogeneous and smooth in echotexture and outline. It is hyperechoic compared to the liver. Its size is variable and dependent on patient demographics, but 5–12cm is taken as a normal adult range ([Chow et al., 2016](#)).

Careful assessment of the splenic hilum should be made as this is a common area for accessory splenic tissue (splenunculi) to develop. A splenunculus will be of the same smooth, homogeneous echotexture as the spleen itself and is not pathological. In patients who have had a splenectomy, coexisting splenunculi commonly become hypertrophic.

Technique

Access to the spleen can be challenging due to overlying ribs and body shape. For optimal visualisation, it is worth trying both supine and right decubitus positions on arrested inspiration and, ideally, with the patient's left arm stretched above their head.



The spleen is often more superior and posterior than anticipated, so bear this in mind when positioning the transducer.

5.2.5.1 Common clinical scenarios

Splenomegaly

The most common pathological condition of the spleen is splenomegaly. This can occur due to portal hypertension, haematological conditions or underlying infection ([Chapman et al., 2021](#)). Correlation with other ultrasound findings, previous medical history and the patient's clinical presentation is required. In the presence of ascites, hepatic perfusion with Doppler assessment of the portal and hepatic veins should be performed. Assessment of the splenic vasculature is required to evaluate the presence of varices commonly associated with portal hypertension. In severe cases, splenorenal varices and shunts may develop.

Trauma

The spleen is the most frequently injured intra-abdominal organ and is visualised commonly as part of the 'focused assessment with sonography for trauma' (FAST) protocol for rapid assessment of unstable blunt trauma patients presenting in the emergency department. However, contrast-enhanced CT remains the gold standard for evaluating splenic injury, as well as injury elsewhere within the abdomen or chest.

Splenic lesions

Solitary and multiple splenic lesions are seen commonly on ultrasound and manifest through a variety of processes ([Walsh et al., 2005](#)).

TABLE 5: Solitary splenic lesions

	Appearance	Likely diagnosis and comments
Cysts	Well-defined, thin-walled, anechoic.	Epidermoid cysts have calcified walls in 10% of cases. Hydatid cysts may be anechoic or of mixed echogenicity due to the presence of hydatid sand or infolded membranes. Multiple, small, internal or subadjacent daughter cysts may arise.
Haemangioma	Well-circumscribed, hyperechoic.	Usually solitary. Multiple lesions may be associated with Klippel–Trenaunay–Weber, Beckwith–Wiedemann or Turner syndrome. Large lesions may result in portal hypertension or splenic rupture.
Lymphangiomas	Complex solid-cystic mix with a hyperechoic periphery.	Rare, slow-growing, vascular lesions that may be single or multiple.
Infarction	Ill-defined, often peripherally based, wedge-shaped or rounded, hypoechoic.	May be difficult to identify with ultrasound in the acute setting. CEUS imaging can aid diagnosis.

TABLE 6: Multiple splenic lesions

	Appearance	Likely diagnosis and comments
Infection	Ill-defined, hypoechoic lesions, which may contain hyperechoic debris and internal septations.	Splenic abscesses occur most frequently in immunocompromised patients, and may be bacterial, fungal or granulomatous.
'Starry sky' spleen	Multiple, small (2–3mm), highly echogenic (hyperechoic) foci with or without acoustic shadowing and may correspond to calcified lesions seen on x-ray or CT.	Multiple highly reflective focal lesions within the spleen give rise to the so-called 'starry sky' appearance. It is usually secondary to previous granulomatous infection with histoplasmosis or tuberculosis.
Lymphoma	Multiple ill-defined and hypoechoic lesions; however, hyperechoic lesions of a complex nature and target lesions have also been described.	Hodgkin's and non-Hodgkin's lymphoma account for the majority of splenic malignancies.
Metastases	Variable appearance, ranging from hypoechoic poorly defined lesions to hyperechoic lesions, with or without a hypoechoic rim or halo.	Uncommon site for metastatic disease. The commonest primary tumours are malignant melanoma, breast and bronchogenic carcinoma. CT remains gold standard for imaging metastatic disease.
Sarcoidosis	Multiple hypoechoic nodules measuring up to several centimetres.	Hepatosplenomegaly and lymphadenopathy are common associated findings. Multisystem granulomatous disease of unknown origin and splenic involvement is relatively uncommon.
Malignant infiltration	Splenomegaly with no discernible alterations in splenic echotexture.	Diffuse leukaemic or lymphomatous involvement of the spleen. Clinical correlation is required. Doppler evaluation of the portal vein may be valuable.



For indeterminate splenic lesions, see the BMUS document [Incidental findings](#).

Further information can be found at:

- Alty, J. Hoey, E. Wolstenhulme, S. Weston, M. and Aly, J. (2013). Practical Ultrasound: An Illustrated Guide 2nd ed (CRC Press).
- Hertzberg, B.S., and Middleton W.D. (2016). Ultrasound: The Requisites 3rd ed. (Elsevier).
- Mazur, R., Celmer, M., Silicki, J., Hołownia, D., Pozowski, P., and Międzybrodzki, M. (2018). Clinical applications of spleen ultrasound elastography – a review. J. Ultrason. 18, 37–41. Available at: <https://pubmed.ncbi.nlm.nih.gov/29844939/>
- Tedesco, G., Sarno, A., Rizzo, G., Grecchi, A., Testa, I., Giannotti, G., and D’Onofrio, M. (2019). Clinical use of contrast-enhanced ultrasound beyond the liver: a focus on renal, splenic, and pancreatic applications. Ultrasonography 38, 278–288. Available at: <https://pubmed.ncbi.nlm.nih.gov/31230431/>
- Trenker, C., Görg, C., Freeman, S., Jenssen, C., Dong, Y., Caraiani, C., Ioanîţescu, E.S., and Dietrich, C.F. (2021). WFUMB Position Paper—Incidental Findings, How to Manage: Spleen. Ultrasound Med. Biol. 47, 2017–2032. Available at: <http://www.umbjournal.org/article/S0301562921001538/fulltext>

5.2.6 Abdominal aorta

[updated 2021]

General scanning principles

The normal abdominal aorta is retroperitoneal, extends from the diaphragm to the bifurcation where it divides to form the right and left common iliac arteries, and measures less than 30mm diameter. Branches seen on ultrasound include the celiac axis, superior and inferior mesenteric arteries, and right and left renal arteries. Age-related changes within the aorta include commonly tortuosity and wall calcification.

Technique

The abdominal aorta should be imaged fully in both longitudinal and transverse planes. Full visualisation, however, is often impeded by overlying bowel and/or body fat. Methods to improve visualisation include:

- Gentle graded transducer pressure to displace the bowel
- Keeping the patient’s arms by their sides for a more relaxed abdomen
- Asking the patient to bend their legs, which also relaxes the abdomen
- Turning the patient to the right and scanning from the left in a coronal oblique plane*
(*Note: This method is useful for radiology staff but is not recommended for use by screening technicians.)

Justification

The most common reason for evaluating the aorta is for suspicion of aneurysm. Aneurysms may be fusiform or saccular, single, double or multiple and may develop at any point along the aorta but occur most commonly just superior to the bifurcation. An AAA is defined as a focal dilatation of the aorta measuring 30mm or more. Anteroposterior measurements taken at the widest point in transverse plane are considered optimal. To ensure consistency of measurements and follow-up,

[NICE \(2020\)](#) recommends measuring the aorta at the widest point using the inner-to-inner maximum anteroposterior diameter. This method has been adopted by the NHS AAA screening programme.



If an aneurysm is identified, at least one image with colour Doppler overlay should be saved to ensure there is no ambiguity over which fluid-filled structure has been measured.

Most AAAs are incidental findings during an imaging examination for another reason. They occur most commonly in older men. In the UK there is a successful NHS-led screening programme to identify asymptomatic aneurysms in men aged around 65 years. Details are available at [NHS AAA screening programme overview](#).



For management advice aligned to the NHS screening programme, see the BMUS document [Incidental findings on general medical ultrasound examinations](#).



If a suprarenal aortic aneurysm is seen, check to see if the aneurysm is extending from the thorax. Report thoracic extension or uncertainty, suggest that a thoracic aortic aneurysm is a possibility and recommend further cross-sectional imaging to assess.

The AAA screening programme [Clinical guidance and scope of practice for professionals involved in the provision of the ultrasound scan within AAA screening](#) also has useful information on management of incidental findings, including the extension of a thoracic aortic aneurysm into the abdominal aorta.

Important things to check ([regulation 28 report](#)):

- Look carefully for an intimal flap when scanning the aorta, as they can be seen extending all the way from the thorax. Appropriate follow-up action is needed if an intimal flap is seen.
- If the suprarenal aorta is dilated, check for an intimal flap extending from a dissecting thoracic aortic aneurysm into the abdominal aorta. CT is more accurate than ultrasound in the assessment of suprarenal aneurysms ([Isselbacher., 2005](#)).

Extending the examination

If an abdominal aneurysm is found it is best practice to view the kidneys to see if either the vascular supply and/or the ureters are compromised by the aneurysm due to pressure effects. One or both kidneys may appear hydronephrotic if the ureter is compressed. Cortical thinning may be evident if there is reduced blood flow to the kidney.

The CSVS guidelines [Endovascular Aneurysm Repair \(EVAR\) Assessment](#) are also helpful for those undertaking EVAR ultrasound examinations.



elearning for healthcare

See additional online resources at:

- 16_02 - [Abdominal Ultrasound: Aorta - Session 1](#)
- 16_03 - [Abdominal Ultrasound: Aorta - Session 2](#)

Further information can be found at:

- Oliver-Williams, C., Sweeting, M.J., Turton, G., Parkin, D., Cooper, D., Rodd, C., Thompson, S.G., and Earnshaw, J.J. (2017). Lessons learned about prevalence and growth rates of abdominal aortic aneurysms from a 25-year ultrasound population screening programme. *Br. J. Surg.* 105, 68–74. Available at: <https://academic.oup.com/bjs/article/105/1/68/6123022>
- Sakalihasan, N., Michel, J.-B., Katsargyris, A., Kuivaniemi, H., Defraigne, J.-O., Nchimi, A., Powell, J.T., Yoshimura, K., and Hultgren, R. (2018). Abdominal aortic aneurysms. *Nat. Rev. Dis. Prim.* 41 4, 1–22. Available at: <https://www.nature.com/articles/s41572-018-0030-7>

5.2.7 Urinary tract, scrotum and penis

General scanning principles

Ultrasound imaging of the urogenital tract is a common first-line investigation for both the adult and paediatric population and for a wide range of indicators including infection, cancer and structural malformations. Secondly, it is often useful for surveillance and follow-up in urinary and testicular conditions. A variety of ultrasound transducers and equipment settings are of particular value in this clinical area. The practitioner must have knowledge of when and how to apply harmonic imaging, spatial compounding and Doppler options for maximum diagnostic accuracy.

Justification and clinical history

Ultrasound imaging is frequently chosen for evaluating the urinary tract, testes and prostate gland, not least because of its advantage over CT in avoiding a radiation dose to sensitive organs. However, a clear answerable clinical question is still required to ensure value to the examination. Where there is doubt, refer to the [BMUS Justification of ultrasound requests](#).

5.2.7.1 The kidneys

General scanning principles

The kidneys and immediate surrounding area should be examined in two planes and representative images stored. The renal length/size should be assessed and measured and reported, especially in paediatric cases and urological referrals. Normal adult kidney sizes vary with age and body habitus but should be symmetrical when compared with each other. A flexible technique is required for acquiring true longitudinal measurements and may involve turning the patient onto their side and using arrested respiration in different phases in order to avoid overlying rib and bowel artefact.

Reference charts of normal measurements for height/age versus renal size must be available if scanning paediatric patients. Exophytic cortical lesions and cysts should not be included in length measurements.



Always examine well beyond the renal margins otherwise pathology such as adrenal tumours, exophytic lesions and collections may be missed.

Cortical thickness

The texture, echogenicity and thickness of the renal cortex should be noted. Increased echogenicity and cortical thinning are indicative of renal parenchymal disease and chronic renal impairment.

Cortical thickness and parenchymal thickness measurements differ. Cortical thickness is taken from the outer capsule to the base of the pyramid. The normal size range is 7–10mm ([Hansen *et al.*, 2016](#)). The parenchymal thickness is taken from the outer capsule to the border of the sinus fat. The measurement should be taken in LS at the mid-pole (or where it is at its thinnest), taking care to avoid any hypertrophied column of Bertin. The lower limit of normal parenchymal thickness is 10mm ([Penny., 2018](#)).

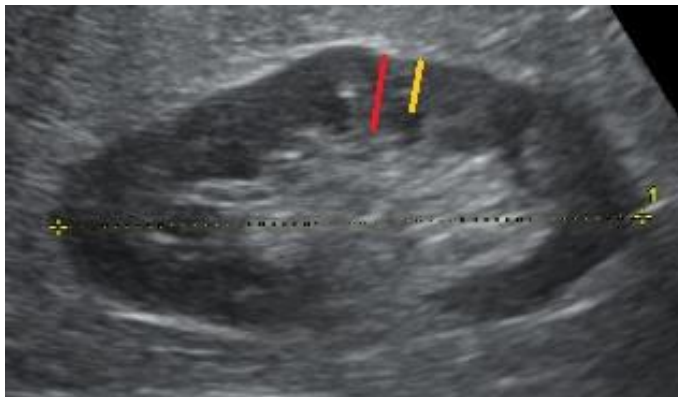


Figure 2: The cortical thickness (yellow line) is from the renal capsule to pyramid; the parenchymal thickness (red line) is from the renal capsule to the sinus echo

Structures to examine and evaluate

Focal or diffuse morphological changes may be observed and should be reported as such. Changes need to be evaluated in the context of previous imaging and clinical history. Focal renal masses include benign cysts, angiomyolipoma and malignant lesions. Service providers are strongly advised to develop management guidelines which include necessary follow-up, onward referral or alternative imaging in conjunction with their urological surgical colleagues and radiologists. The practitioner should be aware of normal anatomical variants that may mimic renal lesions, such as hypertrophied columns of Bertin and splenic humps. While the majority of normal anatomical variants should be correctly recognised with ultrasound, CEUS, CT or MRI should be considered where there remains doubt over a potential lesion.

Renal cysts should be documented and assessed for complexity. Ultrasound of simple/minimally complex cysts is sufficient. More complex renal cysts require formal Bosniak grading with either CEUS or CT, according to local guidelines.

The Bosniak classification system of renal cystic masses, which was originally developed for use with CT, is helpful for management of suspicious lesions ([Gaillard et al., 2008](#)).

Challenges have been made to the current Bosniak system but are yet to gain widespread validation ([Silverman et al., 2019](#); [Zhong et al., 2017](#)).

Suspicious renal lesions may demonstrate any of the following:

- Predominantly solid but can appear as complex cystic masses
- Different echogenicity from the surrounding cortex
- Vascularity – either altered or deviated vasculature
- Altered renal outline if exophytic
- Indentation of the renal sinus (*hypertrophied column of Bertin might mimic tumour)

Renal vein patency should be assessed when a solid renal lesion is suspected.



In the presence of a suspicious renal mass, CEUS is helpful, if available, for more detail on altered perfusion or absent perfusion in the case of complex haemorrhagic cysts.



For imaging management of renal masses, see the BMUS document [Incidental findings on general medical ultrasound examinations](#).

5.2.7.1.1 Common clinical scenarios

Haematuria

The ultrasound practitioner should establish whether haematuria is microscopic or macroscopic and be aware of the place of ultrasound in the diagnostic testing of a patient with haematuria. The investigation of haematuria may be best performed in the context of a dedicated haematuria clinic according to local practice. Both kidneys, ureters (if visible) and urinary bladder should be assessed. Note that the mid-ureter is frequently not visible due to overlying bowel gas, but the ureter at the level of the pelviureteric junction (PUJ) and vesicoureteric junction is usually amenable to ultrasound assessment.

Conditions to identify include hydronephrosis, stones, and lesions within the kidneys or urinary bladder. Ultrasound has limited sensitivity in assessment for transitional cell tumours in the renal collecting system, ureters or urinary bladder. Patients with unexplained macroscopic haematuria should be considered for further tests to better demonstrate these regions, e.g. flexible cystoscopy and CT urogram.

Acute kidney injury (AKI – formerly acute renal failure) and chronic kidney injury

The main aim of ultrasound is first to determine whether renal dysfunction is a medical or surgical (obstructive) problem.

Both kidneys should be assessed for size, parenchymal thickness and cortical reflectivity. The practitioner should be aware of age-related changes in renal appearance. The urinary bladder should be assessed for distension, presence of tumours, trabeculation, wall thickness and diverticula. The size of the prostate gland should be estimated in males and assessment of bladder voiding should be performed where possible. More detailed professional guidelines on the prostate gland are offered in [section 5.2.7.4](#).

Renal cortical echogenicity should be assessed by comparison with adjacent liver/spleen and internally by comparison with medullary pyramids. Increased cortical echogenicity implies 'medical' renal disease but is a non-specific finding.

Where the kidneys are enlarged, the patency of the renal veins should be assessed.

The renal collecting system should be examined for dilatation. In cases of pelvicalyceal dilatation, the collecting systems, ureters, and urinary bladder should be examined to try to determine the level and cause of any obstruction.

The practitioner should be aware of common causes of bilateral renal obstruction such as tumours of the urinary bladder, pelvis and retroperitoneum; inflammatory conditions such as retroperitoneal fibrosis and endometriosis; and bladder outflow obstruction. The practitioner needs to be aware of physiological renal pelvis dilatation secondary to a full bladder and, in such cases, rescanning following micturition is useful.

In cases of AKI, pre-examination preparation with fluid loading should be avoided. In some centres, in-patients are requested to attend with an empty bladder or are catheterised.

Renal obstruction

The ultrasound practitioner should be aware of the limitations of ultrasound in assessing high-grade urinary obstruction. The presence of pelvicalyceal dilatation is not always due to urinary obstruction, and neither does the absence of pelvicalyceal dilatation exclude high-grade obstruction. In the obstructed kidney, the degree of obstruction does not correlate well with the degree of dilatation. Chronic hydronephrosis may be associated with loss of parenchymal thickness.

The renal pelvis and calyces should be assessed for the presence of calculi. While larger calculi may be visible, ultrasound is of limited sensitivity in the detection of small ones. The presence of acoustic shadowing is helpful and the practitioner should be aware of image processing technologies which may reduce the presence of shadowing, particularly spatial compounding. Colour Doppler may be useful to assess for the presence of 'twinkle' artefact, although this is an unreliable sign in isolation.

Secondary signs of obstruction may include presence/absence of ureteric jets within the bladder and increased vascular resistance to intra-renal arterial blood flow. A resistive index of >0.7 is considered raised ([Hertzberg and Middleton., 2015](#); [Viyannan et al., 2021](#)).

The practitioner should also be aware of the utility of other imaging modalities, including radiographs and CT, and the correlative nature of these tests. [NICE \(2019, updated 2024\)](#) offers comprehensive guidance on the management of AKI.

Urinary tract infection (UTI)

In acute infection, the kidneys frequently appear normal on ultrasound.

The kidneys should be assessed for size, morphology and echogenicity. Anatomical variants such as duplex kidney, horseshoe kidney and renal ectopia may make the patient more susceptible to UTI. The practitioner should be alert to the signs of acute renal infection such as small volumes of

perinephric fluid, hydronephrosis, pyonephrosis, diffuse renal enlargement or a focal cortical abnormality suggesting focal pyelonephritis.

The ureters should be assessed for dilatation and the urinary bladder should be examined for distension, wall thickening, and other signs of bladder outflow obstruction. The prostate gland should be assessed for size and the post-micturition residual bladder volume estimated.

Renal transplant (immediate post-operative period)

The objective is to demonstrate any surgical complications which may require immediate intervention.

The size and morphology of the transplant kidney should be examined to establish a baseline for subsequent scans. The practitioner should establish the presence/absence of perinephric haematoma/collection and exclude hydronephrosis. Perfusion of the whole kidney should be assessed using appropriate colour Doppler settings. The main renal vein should be examined with colour Doppler ultrasound to ensure patency throughout its length.

Local protocol may require a more comprehensive Doppler assessment of the transplant kidney. This may include pulsed wave Doppler of the interlobar arteries to assess blood flow patterns which may give indirect evidence of arterial (inflow) or venous (outflow) problems of the graft. Doppler indices (resistance or pulsatility) should be recorded. The presence/absence of reversed arterial diastolic flow should be established and the practitioner should be aware of possible causes for this. Ultrasound appearances that require immediate surgical intervention, such as arterial or venous occlusion of the transplant kidney, must be discussed with the surgical team.



elearning for healthcare

See additional online resources at:

- 16_10 - [Abdominal Ultrasound: Kidneys](#)
 - 16_11 - [Abdominal Ultrasound: Bladder](#)
 - 16_16 - [Abdominal Ultrasound: Renal Transplant](#)
-

5.2.7.1.2 Renal ultrasound reporting examples

Referral for upper abdominal pain

Clinical details: H/O renal stones. Acute pain right side.

Urinary tract ultrasound performed with verbal consent:

Note is made of the ultrasound exam from Jan 2019.

The right kidney contains at least two stones of approx. 12mm diameter causing mild hydronephrosis. In the upper pole of the left kidney there is a non-obstructing 7mm stone. Both kidneys are a normal size and shape. Smooth-walled bladder which empties fully on micturition. Normal calibre abdominal aorta.

Conclusion:

Obstructing right renal stones. Non-obstructing left renal stone remains unchanged from 2019. Report fast-tracked to Urology.

Referral for left sided colic

Clinical details: 68 year old male high BMI, left flank pain ?renal stones

Urinary tract ultrasound performed with verbal consent:

No previous relevant imaging.

Both kidneys look normal in size, shape and morphology. Both measures approx. 120mm. No stones or focal parenchymal abnormality seen. The bladder is empty. There is a fusiform lower abdominal aortic aneurysm just superior to the bifurcation. Maximum AP diameter is 65mm.

Conclusion:

Normal renal appearances. AAA of 65mm. Urgent referral to vascular team advised. Urgent alert generated.

Referral for macroscopic haematuria

Clinical details: 45 year old woman, haematuria, dull ache on right.

Urinary tract ultrasound performed with verbal consent:

The upper pole of the right kidney has been replaced by a heterogeneous vascular mass of approx. 90mm diameter. The lower pole of the right kidney appears unaffected. Left kidney, bladder and abdominal aorta are unremarkable.

The IVC appears normal. No focal liver lesions seen.

Conclusion:

Appearances suspicious for right renal malignancy. Urgent urology referral appropriate. Urgent alert generated.

Further information:

- Tan, W.S., Sarpong, R., Khetrpal, P., Rodney, S., Mostafid, H., Cresswell, J., Hicks, J., Rane, A., Henderson, A., Watson, D., *et al.* (2018). Can Renal and Bladder Ultrasound Replace Computerized Tomography Urogram in Patients Investigated for Microscopic Hematuria? *J. Urol.* 200, 973–980. Available at: <https://www.sciencedirect.com/science/article/pii/S0022534718430455>
- Wentland, A.L., Desser, T.S., Troxell, M.L., and Kamaya, A. (2019). Bladder cancer and its mimics: a sonographic pictorial review with CT/MR and histologic correlation. *Abdom. Radiol.* 44, 3827–3842. Available at: <https://link.springer.com/article/10.1007/s00261-019-02276-w>

5.2.7.2 The testes and scrotum

General scanning principles

Ultrasound is the first-line imaging modality for a raft of conditions affecting the scrotal contents. A linear high-frequency transducer offers superior detail compared with CT or MRI. The most common indicator for requesting a scrotal scan is the presence of a new lump, and ultrasound's superior resolution lends itself well to differentiating easily between cystic and solid masses.

Due to the intimate nature of ultrasound examination of the scrotum, it is essential that it is conducted in a quiet room, without interruption and with a chaperone. The practitioner must aim to preserve the patient's dignity and privacy at all times. The practitioner must also be mindful that many patients attending for this test are very anxious.

Sonographically, the testes and epididymides must be examined systematically in both a longitudinal and transverse plane, noting symmetry, echotexture and echogenicity. Assessment of the epididymal heads, bodies and tails should be made for focal or diffuse thickening and the presence of cysts and other lesions. The practitioner should be aware of age-related and post-vasectomy changes such as atrophy, epididymal thickening and sperm granulomas. The adnexa and scrotal wall are also part of the examination and may contain additional pathology such as oedema, scrotoliths and hydroceles.



In the very enlarged scrotum, perhaps due to suspected hydrocele, infection or trauma, it is helpful to start the examination with a curvilinear transducer affording a wider field of view so that orientation and landmarks are obtained.

Normal appearances

The normal adult testis is up to around 50mm in length and has a smooth homogeneous texture on ultrasound. Testes smaller than 35mm are considered abnormal. The normal epididymis is slim and slightly hypoechoic when compared to the testis. Epididymal enlargement may be focal or diffuse and can be a consequence of infection, abscess, tubular dilatation/ectasia or a mass.



In cases of isolated orchitis or complex epididymo-orchitis, a follow-up scan in the non-acute phase, usually 6–8 weeks later, is advised to avoid missing small underlying lesions.

5.2.7.2.1 Common clinical scenarios

Varicocele

A varicocele is reported if the AP diameter of the peritesticular veins is more than 3mm ([Mittal et al., 2017](#)). The venous flow and presence of reflux are assessed using colour Doppler ([Mittal et al., 2017](#)) and the Valsalva manoeuvre. Although the incidence of occult abdominal malignancies in men with varicoceles is very low, the practitioner is justified in extending the scan to include the abdomen if the varicocele is large or of acute onset, or fails to decompress in the supine position ([Freeman et](#)

[al., 2019](#)). Therefore, it is viewed as best practice to look for retroperitoneal masses and/or malignant thrombus.

If a varicocele is present on the left, the left main renal vein may be assessed for patency and to exclude renal malignancy. If a varicocele is seen on the right, the practitioner may choose to extend the examination to evaluate both the right main renal vein and IVC for patency.

Scrotal mass

In the presence of a scrotal mass, the aim is to determine if it is intra- or extratesticular and to characterise if possible. Every effort should be made to visualise the suspected mass. If the practitioner is unable to locate it, the patient should be asked to lead the practitioner to the area of concern so that they may scan directly over it. The practitioner should follow local guidelines for referral/alerting clinical teams of suspected testicular cancer.

Sometimes, on questioning, the patient may point out the worrying 'lump' as being in the groin rather than the scrotum, so it is prudent to remember that hernias, lymph nodes, lipomas, undescended testes and other examples of inguinal pathology may be why the patient presented.



It is essential for practitioners to question their patients during the ultrasound examination to improve detection rates, especially now that many patient–GP consultations are only conducted via the telephone.



For imaging management of incidental testicular lesions, see the BMUS document [Incidental findings on general medical ultrasound examinations](#).

Suspected testicular torsion

In clinically suspected testicular torsion, ultrasound investigation should not delay surgical exploration to offer the best chance of preserving the testis. Ultrasound cannot confidently exclude torsion, but an examination may be performed in cases of acute testicular pain. Practitioners need to be aware of the ultrasound features of torsion, and if there is any doubt, urgent urological advice should be sought.

The testes, epididymides and tunical space should be assessed. Colour Doppler of both testes should be undertaken, assessing presence and symmetry of blood flow within the testes (see BMJ Best Practice: [Testicular torsion](#)).

The absence of discernible blood flow within a testis (where flow is visible on the contralateral normal side) is highly predictive of testicular torsion. However, it should be noted that the presence of blood flow does not exclude torsion, particularly intermittent torsion. The spermatic cord should be examined to assess for the presence of twisting of vessels here (the whirlpool sign).

The ultrasound practitioner should be aware that testicular torsion can also cause epididymal swelling and hydrocoele formation, mimicking epididymo-orchitis, although the absence of intratesticular flow may be diagnostic. However, intermittent testicular torsion can demonstrate

increased intratesticular blood flow on colour Doppler examination, which may be indistinguishable from epididymo-orchitis.

The Healthcare Safety Investigation Branch report: [Management of acute onset testicular pain](#) should be read in conjunction with these Guidelines.

Microlithiasis

Testicular microlithiasis is defined as more than five hyperechoic foci in one viewable image sector ([Mittal et al., 2017](#); [Richenberg et al., 2015](#)).

Risk factors for microlithiasis include ([Richenberg et al., 2015](#)):

- Previous germ cell tumour
- Family history of germ cell tumour (1st degree relative)
- History of maldescent of the testis/cryptorchidism
- History of orchidopexy
- Testicular atrophy (<12mls volume).

Annual ultrasound up to the age of 55 years is recommended for men with microlithiasis and any of the above risk factors. Current management for microlithiasis in the asymptomatic and apparently healthy male with no relevant risk factors ([Richenberg et al., 2015](#)) is regular testicular self-examination with advice to seek early medical attention if necessary. Scrotal ultrasound and serum tumour marker testing are NOT recommended ([Mittal et al., 2017](#); [Richenberg et al., 2015](#)).

Service providers are strongly advised to develop management guidelines which include necessary follow-up, onward referral or alternative imaging in conjunction with their urological surgical colleagues and radiologists.



The report of the initial finding of microlithiasis could advise:

In the absence of risk factors, the patient should be educated regarding regular self-examination and to seek immediate medical attention if there are any palpable changes or masses detected. However, if this is a new finding, the patient can be referred to urology for management advice.

- 17_01 - [Men's Health Ultrasound: Testes - Session 1](#)
- 17_02 - [Men's Health Ultrasound: Testes - Session 2](#)

Further information can be found at:

- [European Society of Urogenital Radiology](#)
- NHS England (2016) Guidelines for the management of testicular cancer. Available at: <https://www.england.nhs.uk/mids-east/wp-content/uploads/sites/7/2018/05/guidelines-for-the-management-of-testicular-cancer.pdf>

- NICE (2021) Scrotal pain and swelling. [Revised 2022] Available at: <https://cks.nice.org.uk/topics/scrotal-pain-swelling/>

5.2.7.3 The penis

[2021]

General scanning principles

Referrals for ultrasound examination of the penis are rare, but the two main reasons are trauma or palpable lump. Occasionally, haemodynamic studies are performed for men with erectile dysfunction, but these are usually at specialist centres.

As with testicular scanning, the examination should be conducted in a room where minimal interruptions are anticipated and with the patient's privacy and dignity in mind.

Palpable penile mass

Peyronie's disease

The most common palpable mass is related to Peyronie's disease, an accumulation of fibrous plaques, most commonly on the dorsum of the penis, which causes it to bend on erection, and may be painful. Ultrasound may identify Peyronie's plaques as focal areas of hyperechoic thickening of the tunica. Doppler ultrasound following pharmacological stimulation of erection can also assess erectile dysfunction sometimes associated with this condition. Masses may also occur due to the malfunction of penile erection devices.

Malignant penile mass

Penile cancers are rare and nearly all are types of skin cancer. Squamous cell carcinoma (SCC) is the most common type and usually presents between the ages of 50 and 70 years. The majority of lesions are found on the glans. Ultrasound may demonstrate a hypoechoic vascular lesion, which should be considered highly suspicious for malignancy, but diagnosis of penile cancer is usually via clinical examination and biopsy.

Further information can be found at:

- Davidson, N. (2022). Abdominal ultrasound: how, why and when, 4th ed. (Elsevier).

5.2.7.4 The prostate gland

[2021]

General scanning principles

Most ultrasound practitioners perform only TA (or suprapubic) ultrasound when imaging the prostate gland. Undoubtedly, superior resolution is via transrectal ultrasound (TRUS) and it is important for practitioners to recognise the limitations of viewing the gland only using the TA approach. Although textural and zonal details of the prostate gland are generally indistinct, reliable measurements may still be obtained ([Feng et al., 2017](#)).

Justification and clinical history

The most common indicator for referral for prostate ultrasound is lower urinary tract symptoms (LUTS), including dysuria, nocturia and frequency. Benign prostatic hypertrophy may be the cause and practitioners are required to measure the prostate gland volume, evaluate the bladder wall and

offer pre- and post-void volumes. Local protocols differ, but residual bladder volumes of >50–100ml are considered significant.

Normal appearances

The adult prostate gland is approximately the size of a walnut. Normal measurements are taken as 3 x 4 x 2.5cm, and commonly 30ml is deemed the upper limit for normal volume. The base of the gland lies just under the bladder and is clearly defined by the bladder wall. The apex lies posterior to the symphysis pubis adjacent to muscles of the pelvic floor. Zonal anatomy is divided into:

- Peripheral zone
- Transition zone
- Central zone

Measurements

Precise measurements are required for radiotherapy planning and are best obtained using TRUS or MRI. However, transrectal assessment is not suitable for every patient, particularly those with anal disease. In addition, a recent study reported good correlation between TA and TRUS measurements ([Feng et al., 2017](#)). In cases of suspected prostatic enlargement causing bladder outflow problems, a TA measurement is accurate and adequate. Volume estimation is calculated via three measurements taken from two views of the prostate, one in midline sagittal plane and one in transverse using the formula $H \times D \times W \times 0.5$.

5.2.7.4.1 Common clinical scenarios

Benign prostatic hypertrophy

The transition zone enlarges, commonly with age, and is responsible for urethral constriction and LUTS in cases of benign prostatic hypertrophy. The degree of enlargement is not, however, a predictor for severity of symptoms.

Prostate cancer

Prostate cancer is the most common cancer in men and is more prevalent in those of Black ethnicity ([NICE, 2021](#), updated 2025). Referrals to urology arise from a raised prostate-specific antigen level and/or abnormal digital rectal examination. Diagnosis is by imaging and biopsy.

Prostate cancer arises in the peripheral zone in approximately 75–80% of cases and in the transition zone in 15% of cases. Cancers here are generally larger at the time of diagnosis due to their central location but have better outcomes when compared with those in the peripheral zone.

Around 70% of prostate cancers appear hypoechoic on ultrasound and 30% are of mixed echogenicity. Practitioners need to be aware of local protocols and pathways to avoid delay in management.

Despite advances in imaging technologies, in particular multiparametric MRI (mpMRI) and the advent of a standardised MRI reporting system Prostate Imaging-Reporting and Data System PI-RADS v2.1 ([Padhani et al., 2019](#)), imaging does not have a role in the routine diagnosis of prostate cancer. mpMRI can identify high-risk areas of abnormality within the prostate. More recent developments in fusion technology have further improved the role of mpMRI and ultrasound in guiding targeted biopsies ([Ahmed et al., 2017](#)). New ultrasound techniques using high frequency ultrasound, of up to 29MHz are emerging and early trials indicate that this technology will have a role in imaging the prostate, particularly in patient in whom MRI is contraindicated ([Dias et al., 2022](#)). However, the diagnosis and grading of prostate cancer remains a histopathological process.

The role of ultrasound within the prostate cancer pathway should be developed in conjunction with radiology and urology colleagues, particularly as new techniques, such as the use of transperineal prostate biopsy in an outpatient setting, emerge and new protocols are developed.



Only use ultrasound within an agreed urology radiology prostate cancer pathway.

Ultrasound currently has no role in the follow-up or assessment of prostate cancer disease progression, although early publications indicate that high-frequency ultrasound imaging may provide diagnostic features comparable with mpMRI ([Parker *et al.*, 2021](#)).



See additional online resources at:

- 17_03 - Men's Health Ultrasound: [TRUS of the Prostate Gland and Biopsy](#)

Further information can be found at:

- Correas, J.M., Halpern, E.J., Barr, R.G., Ghai, S., Walz, J., Bodard, S., Dariane, C., and de la Rosette, J. (2020). Advanced ultrasound in the diagnosis of prostate cancer. *World J. Urol.* 39, 661–676. Available at: <https://link.springer.com/article/10.1007/s00345-020-03193-0>
- Hertzberg, B.S., Middleton W.D. (2016). *Ultrasound: The Requisites*, 3rd ed. (Elsevier).

5.2.8 The bowel

[2020]

Justification and clinical history

Bowel symptoms are a common cause for patients presenting to their doctor and being referred for imaging. Many gastrointestinal (GI) conditions are amenable to ultrasound diagnosis, including appendicitis, diverticulitis and inflammatory bowel disease. Although it should not be used as a screening tool for vague non-specific symptoms, surveying the gastrointestinal tract should be considered in patients presenting with possible GI-related pathology, including weight loss, anaemia and change in bowel habit.

Aspects of a patient's clinical history that are important for aiding ultrasound diagnosis include:

- Duration/length of symptoms
- Location of discomfort/pain
- Trigger factors such as food or alcohol
- Change in bowel habit
- Weight loss
- Nocturnal symptoms, including specifically nocturnal diarrhoea
- Inflammatory markers; C-reactive protein (CRP), erythrocyte sedimentation rate (ESR) and faecal calprotectin

Technique

A variety of different preparation techniques are available. Some practitioners do not use any specific preparation. However the following should be noted:

- Fasting will reduce bowel gas and improve visualisation. The identification of excess fluid within the lumen in the fasting state may be a useful pointer to underlying pathology. Allowing the bladder to fill naturally will lift ileal loops from the pelvis and improve visualisation of the appendix.
- Fluid loading the patient with Gastrografin can improve visualisation of the appendix and functionally assess strictures in inflammatory bowel disease.

Initial assessment should be with a low-frequency transducer to orientate and identify the position of the colon and any initially obvious pathology. A higher-frequency transducer can then be used to specifically examine the colonic gas signature, ileocaecal valve, terminal ileum and appendix where necessary. General survey of the small bowel can then be performed using overlapping sweeps, known as 'mowing the lawn', looking for signs of pathology and mesenteric changes.

Graded compression can be used to displace overlying structures and bowel gas. This is most easily achieved with a curvilinear transducer.

Structures to examine and evaluate

GI structures that can be assessed with TA ultrasound include the terminal ileum, appendix, small bowel and colon, although in most patients the distal rectosigmoid cannot be reliably accessed. While the stomach can be assessed, this would normally require a fluid load as the stomach in the collapsed state may look thickened.



Location of the colonic gas signature is an important marker for orientation. The right and left colons are usually the most lateral in the abdomen, although the caecal position is variable. Using the stomach to locate the transverse colon in the sagittal plane can help, but the flexures may require other manoeuvres.

Normal bowel appearances

Ultrasound appearances of the GI tract vary. In general, the jejunum has more folds than the ileum. The colonic wall is generally thicker due to the presence of additional longitudinal muscle bands which can be identified. Even if the posterior wall cannot be identified, the haustral pattern is often characteristic.

Although up to five layers are described as being visible, in practice only three layers are commonly identified transabdominally:

1. Mucosa and inner muscularis – hypoechoic
2. Submucosal layer – hyperechoic
3. Muscularis propria – hypoechoic




Figure 3: Diagrammatic representation of the bowel wall layers that can be readily seen with ultrasound

TABLE 7: Areas of bowel to assess

Assess	Consider
Location	<ul style="list-style-type: none"> Which part of the GI tract is abnormal?
Wall thickening	<ul style="list-style-type: none"> Normal small bowel up to 3mm. Normal colon up to 4mm, especially sigmoid due to muscular hypertrophy.
Wall layers	<ul style="list-style-type: none"> Are the layers preserved, ill-defined or destroyed?
Bowel lumen	<ul style="list-style-type: none"> Increase in fluid content in the fasting state may be a marker for disease.
Mesentery	<ul style="list-style-type: none"> Mesentery normally appears as a series of hypo- and hyperechoic parallel layers, at the end of which is a small bowel loop. Change in normal layer structure and increase in echogenicity or fat are useful markers for disease process involving the mesentery.
Vascularity	<ul style="list-style-type: none"> In healthy bowel it is uncommon to detect vessel signals with Doppler. Increased vascularity is demonstrated in acute inflammation and is used in part of the assessment of inflammatory bowel disease.



For optimised assessment of vascularity within the bowel wall and mesentery, the pulse repetition frequency has to be set to <7cm/s. Use of slow flow Doppler algorithms may also be useful.

5.2.8.1 Common clinical scenarios

Acute appendicitis

- The normal appendix is a blind-ending tubular structure with the same mural pattern as the GI tract. It is suspended by its own mesentery (mesoappendix) arising postero-medially from the caecal pole, although it can lie in a variety of locations.
- Generally, the maximum outer diameter of a normal appendix is <6mm. However, it may be ≥6mm in the absence of inflammation, especially in children, so additional signs, particularly changes in the mesoappendiceal fat, may be needed to aid diagnosis.
- Identification of secondary inflammatory signs: significant free fluid/bowel wall oedema and inflammatory fat are useful markers for locating appendicitis, and absence of these in the presence of normal blood results is helpful in excluding appendicitis, even if the appendix is not visualised.
- If there is focal rebound tenderness, secondary inflammatory signs or abnormal blood tests and the appendix is not visualised, consider further imaging.

Sonographic signs of appendicitis:

- Wall thickening
- Loss of mural stratification – may indicate necrosis
- Distended appendiceal lumen
- Inflammatory mesenteric changes (hyperechoic swollen periappendiceal fat)
- Fluid/collection
- Hypervascularity on Doppler



- Scan the whole appendix, as changes may be focal, for example limited to the tip.
- In patients >40 years old, always scan the caecal pole to exclude tumour involving the orifice.
- An inflamed mesoappendix is often more helpful in diagnosis than the appendiceal size.

Diverticulitis

- The identification of diverticula is common in the sigmoid colon, particularly in the elderly. Normally they are simple mucosal prolapses containing gas, with no evidence of wall thickening ([Mazzei et al., 2013](#)).
- In acute diverticulitis, the diverticular wall becomes thickened and is often capped with hyperechoic inflamed fat – the ‘Dome’ sign. Patients are usually focally tender at this point.

Inflammatory bowel disease

Crohn’s disease

- Ultrasound is increasingly accepted as a valuable imaging technique for both the diagnosis and follow-up of Crohn’s disease and assessment of complications. It can match MRI in the hands of experienced operators, and in some circumstances may be superior.
- The main features of Crohn’s disease on ultrasound include wall thickening involving mucosal and submucosal layers in particular, ulceration, change in the perienteric fat, increase in vascularity and skip lesions.

- Identification of complications including phlegmon, abscesses, fistulae and obstruction can be made. Stressing of strictures with Gastrografin load is useful for assessing the degree of functional obstruction and can be done in real time with video.



Patients with Crohn's disease may have 'skip lesions', whereby a segment of diseased bowel is followed by a normal segment, followed by another segment of thickened bowel.

Colitis

Although not a primary diagnostic test, there is increasing evidence as to the value of ultrasound in diagnosis and follow-up of both Crohn's and ulcerative colitis. Ultrasound is also useful in infective and ischaemic colitides.

Malignant tumours

- Although not a primary diagnostic test, ultrasound may be useful in identification of possible tumours seen on other modalities. Identification of malignant tumours is important in patients presenting for ultrasound with symptoms such as anaemia, weight loss or change in bowel habit.
- Malignant tumours often appear as ill-defined, with destruction of wall layers. Fat may be tethered and other features such as proximal luminal distension may be noted.
- The finding of a colonic mass on ultrasound should result in subsequent staging by CT.



See additional online resources at:

- 16_13 - [Abdominal Ultrasound: Miscellaneous](#)
- 16_18 - [Abdominal Ultrasound: Paediatric bowel](#)

5.2.8.2 Bowel ultrasound reporting examples

Referral for possible appendicitis

Clinical details: Colicky lower abdominal pain, some loose stools. ?Appendicitis, ?Gastroenteritis.

Abdominal ultrasound with verbal consent. Chaperone XX present:

The tip of the appendix is thickened and inflamed with evidence of perforation and an adjacent Xcm diameter abscess containing fluid. Air oedema is noted in the adjacent caecum and terminal ileum, with increased echogenicity in the adjacent fat. Appearances are those of a perforated appendix with adjacent abscess and associated inflammatory mass.

Conclusion:

Appearances highly suspicious for perforated appendix with abscess/collection within the right pelvis.

Referral for possible appendicitis

Clinical details: short history of RIF pain, feeling generally unwell. CRP 112. ?Acute appendicitis.

Abdominal ultrasound with verbal consent. Chaperone XX present:

There is wall thickening of the terminal ileum and adjacent caecum with predominant mucosal thickening but no significant change in the perienteric fat. Increased vascularity is noted in the mucosa together with small adjacent lymph nodes. Appendix appears normal. No other significant finding.

Conclusion:

Appearances are those of infective ileocectitis. This should resolve spontaneously. If there is clinical doubt, recommend repeat scan in 3 to 4 weeks.

Referral for abdominal pain

Clinical details: Right-sided crampy abdominal pain.

Abdominal ultrasound with verbal consent. Chaperone XX present:

There is a 20cm contiguous segment of terminal ileal thickening. Preserved stratification noted in the proximal extent of disease. More acute changes with patchy transmural inflammation and acute hyperechoic mesenteric fat wrapping in keeping with active disease. Multiple local mesenteric lymphadenopathy.

There is evidence of significant prestenotic dilatation. A small amount of free fluid noted in the right iliac fossa. The appendix is not thickened. No evidence of abscess or fistulation.

Conclusion:

Active terminal ileal Crohn's disease with prestenotic dilatation suggestive of subacute obstruction.

Further information can be found at:

- Atkinson, N.S.S., Bryant, R. V., Dong, Y., Maaser, C., Kucharzik, T., Maconi, G., Asthana, A.K., Blaivas, M., Goudie, A., Gilja, O.H., *et al.* (2017). How to perform gastrointestinal ultrasound: Anatomy and normal findings. *World J. Gastroenterol.* 23, 6931–6941. Available at: <https://www.ncbi.nlm.nih.gov/pmc/articles/PMC5658311/>
- Calabrese, E., Maaser, C., Zorzi, F., Kannengiesser, K., Hanauer, S., Bruining, D., Iacucci, M., Maconi, G., Novak, K., Panaccione, R., *et al.* (2016). Bowel Ultrasonography in the Management of Crohn's Disease. A Review with Recommendations of an International Panel of Experts. *Inflamm. Bowel Dis.* 22, 1168–1183. Available at: <https://pubmed.ncbi.nlm.nih.gov/26958988/>
- EFSUMB Recommendations and Guidelines for Gastrointestinal Ultrasound. Available at: <https://efsumb.org/guidelines-recommendations-english-versions/>
- Goodsall, T.M., Nguyen, T.M., Parker, C.E., Ma, C., Andrews, J.M., Jairath, V., and Bryant, R.V. (2021). Systematic Review: Gastrointestinal Ultrasound Scoring Indices for Inflammatory Bowel Disease. *J. Crohn's Colitis* 15, 125–142. Available at: <https://academic.oup.com/ecco-jcc/article/15/1/125/5866421>
- Martínez Pérez, M., Blanc García, E., and Merino Bonilla, J. (2020). Bowel ultrasound:

examination techniques and normal and pathologic patterns. *Radiologia* 62, 517–527.

Available at: <https://pubmed.ncbi.nlm.nih.gov/33127091/>

- Sagami, S., Kobayashi, T., Miyatani, Y., Okabayashi, S., Yamazaki, H., Takada, T., Kinoshita, K., Allocca, M., Kunisaki, R., Ramaswamy, P., *et al.* (2021). Accuracy of Ultrasound for Evaluation of Colorectal Segments in Patients With Inflammatory Bowel Diseases: A Systematic Review and Meta-analysis. *Clin. Gastroenterol. Hepatol.* 19, 908–921.e6. Available at: <https://pubmed.ncbi.nlm.nih.gov/32777549/>
- Taylor, S.A., Mallett, S., Bhatnagar, G., Baldwin-Cleland, R., Bloom, S., Gupta, A., Hamlin, P.J., Hart, A.L., Higginson, A., Jacobs, I., *et al.* (2018). Diagnostic accuracy of magnetic resonance enterography and small bowel ultrasound for the extent and activity of newly diagnosed and relapsed Crohn's disease (METRIC): a multicentre trial. *Lancet Gastroenterol. Hepatol.* 3, 548–558. Available at: <http://www.thelancet.com/article/S2468125318301614/fulltext>

5.2.9 Adult 'lumps and bumps'

[2021]

General scanning principles

Ultrasound of lumps and bumps has become commonplace due to patient anxiety surrounding the discovery of a lump and the clinical management conundrums that arise from the perceived overlap of benign and malignant symptoms for the referrer.

Ultrasound examination of lumps and bumps may be tailored to a specific area depending on the clinical question.



Worrisome 'lumps and bumps' will occur in various locations throughout the body.

It is important to ensure patient dignity is maintained at all times.

Ultrasound is often the first line of imaging investigation to triage lumps into benign, equivocal or suspicious categories.

The vast majority of lumps are benign ([Mayerson *et al.*, 2014](#)), although indeterminate lesions are not uncommon. Small lesions may prevent full characterisation and occasionally lesions cannot be fully characterised due to the non-specific features of the lump. It must be remembered that ultrasound is not a histological diagnosis, and where there are equivocal features or challenges preventing full assessment, this should be documented as appropriate. Local sarcoma centre guidelines should be followed.

Ultrasound may be able to direct primary care referrals to appropriate secondary care management or elucidate clinically complex lesions from secondary care referrers.

Further help with using ultrasound to diagnose lumps and bumps can be found in the BMUS document [Guidelines for the interpretation and reporting of diagnostic ultrasound scanning in soft-tissue masses](#). [updated 2025]

It is essential that the ultrasound practitioner has an in-depth knowledge of the surrounding anatomy and organs with which the presenting lump may be associated. The location of the lump

can often be strongly associated with specific pathologies, helping to narrow the field of possible differential diagnoses.

TABLE 8: Types and origin of lumps and bumps

Types of lumps	Origins of lumps
<ul style="list-style-type: none"> • Inflammatory • Infective • Neoplastic • Benign • Malignant • Cystic • Normal, displaced tissue or increased depth of the normal fat layer • Hernia 	<ul style="list-style-type: none"> • Skin • Subcutaneous fat • Neurovascular structures • Muscle • Connective tissues • Lymph nodes • Bone • Joint

Generally, the ultrasound assessment of lumps and bumps should include:

- Verbal history from the patient regarding the lump or bump
- Location
- Shape
- Size
- Outline and margins
- Echotexture/internal characteristics
- Sonopalpation and dynamic assessment
- Comparison views (where appropriate and asymptomatic)
- Visualisation of all soft tissue layers, dermal, subcutaneous, muscular and bone to assess for interaction

Common ultrasound features of suspicious/malignant lumps and bumps include:

- Large size (>7cm)
- Heterogeneous but predominantly hypoechoic
- Vascularised
- Often well-defined but can have extra-lesion extension
- Deep to the myofascial plane
- Involvement of multiple tissue planes
- Necrotic cystic areas
- Perilesional oedema
- Calcifications (which can, however, also be common in benign findings)

It is recommended that ultrasound departments have dedicated pathways to deal with lumps and bumps, especially in the presence of suspicious or equivocal ultrasound findings (see 'Lipoma' section).

Justification and clinical history

Referrals may include, but are not limited to:

- Surgical removal planned, scan prior to surgery
- Mass >5 but <10cm and/or painful and/or growing. (Please note some sarcoma centre recommend that any lump >7cms should be directed to MRI. It is recommended that local protocols are determined with tertiary sarcoma centres)

- Lump, unexplained cause, no definitive clinical features
- ?Abnormal lymph nodes

Diffuse soft tissue swelling and obviously benign pathologies, such as subcutaneous lipoma, epidermal inclusion cysts and ganglia do not necessarily require ultrasound for diagnosis. Patients should be reassured by clinicians ([BMUS Justification of ultrasound requests](#)).

The diagnosis of a hernia is clinical, based on history, clinical examination and the presence of a groin or abdominal swelling ([British Hernia Society, 2019](#)). Requests from primary care should not be routinely accepted where the clinical presentation is likely to be a hernia. However, it is noted that this is still a frequent request often associated with the search for the cause of pain. Ultrasound should be considered in patients in whom there is diagnostic uncertainty regarding herniae, or to exclude other pathology.

Technique

Ultrasound examination of lumps and bumps can be performed with the patient in varying positions determined by the location of the lump and the preference of the ultrasound practitioner.

A variable but relatively high-frequency linear transducer, such as 6–15MHz, is often utilised to give good definition but allow for adjustment when scanning at depth. Changing to a 3.5MHz curvilinear transducer may be required in cases of an abdominal hernia for example, or where large lumps exceed the field of view of a linear transducer.

Colour or power Doppler may be used to assess lumps and bumps but must be used with caution. There is inevitably overlap between benign and malignant appearances. Although aggressive tumours tend to have increased vascularity, benign schwannoma can be hypervascular and low-grade liposarcoma relatively avascular. The ultrasound practitioner can often formulate the differential and use Doppler to reinforce the diagnosis.

New technology such as high-sensitivity/microvascular Doppler is currently redefining normal Doppler appearances, for example, septal flow in benign lipoma is more readily seen with high-sensitivity Doppler.



Pseudo-vascularity/twinkle artefact can mimic true vascularity, but may be lesion-defining where it is recognised appropriately, e.g. epidermal inclusion cyst.

As with most ultrasound pathology, lump and bumps should be scanned and imaged in two planes.

Dynamic scanning techniques are almost always essential in the evaluation of hernia, such as the Valsalva manoeuvre or tensing and relaxing in case of a muscle hernia.



Beware: Do not apply too much probe pressure whilst scanning to avoid iatrogenic reduction of a herniation or suppression of vascularity on colour Doppler.

5.2.9.1 Common clinical scenarios

Lymph nodes

Lymph node assessment throughout the body has commonality of ultrasound features.

Size (using a short axis measurement), shape and morphology are the three features that must be evaluated and applied to the clinical context. For example, enlarged, oval, vascular nodes with a preserved fatty hilum are likely inflammatory whereas rounded hypoechoic nodes with a loss of normal internal morphology may warrant further investigation.

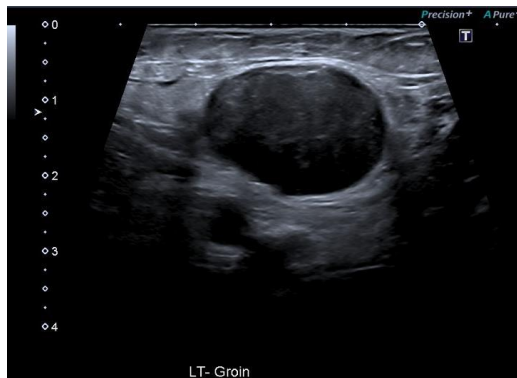


Figure 4: Abnormal lymph node in the left groin

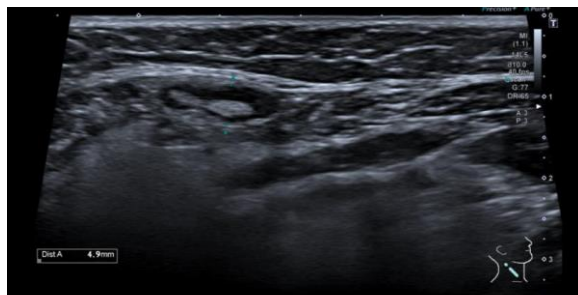


Figure 5: Normal lymph node in the right neck which can often be palpable due to superficial location

Lipomatous lesions

Lipomatous lesions range from benign (lipoma) to malignant (liposarcoma).

Fatty benign tumours are common and account for nearly half of all soft tissue masses. They are often present for many years with little growth.

On ultrasound they are usually located in the subcutaneous tissues. Features include:

- Soft/rubbery
- Relatively compressible
- Elliptical/ovoid
- Generally avascular although subtle septal vascularity may be seen
- Fibrous striations which run parallel to the skin
- 80% are <5cm ([Rydholm et al., 1983](#))
- Echogenicity is variable relative to subcutaneous fat
- Predominantly located within the subcutaneous layer, although may be interfascial or intramuscular



In a new finding of a subcutaneous mass greater than 7cm maximally or recent changes including pain and/or growth, further imaging/investigation would be required.

Ultrasound features are much more variable in the lesions termed 'deep' lipomas, i.e. intramuscular. This is due to the lower resolution of deeper structures on ultrasound and the overlap of features between benign and malignant. Further imaging/investigation should be undertaken in cases where there is a new finding of a deep lipoma ([Dangoor et al., 2016](#)).



The inclusion of a flow chart into local protocols may ensure uniformity of pathway for lipomatous lesions; an example is given below (Figure 6). Local policies will apply.

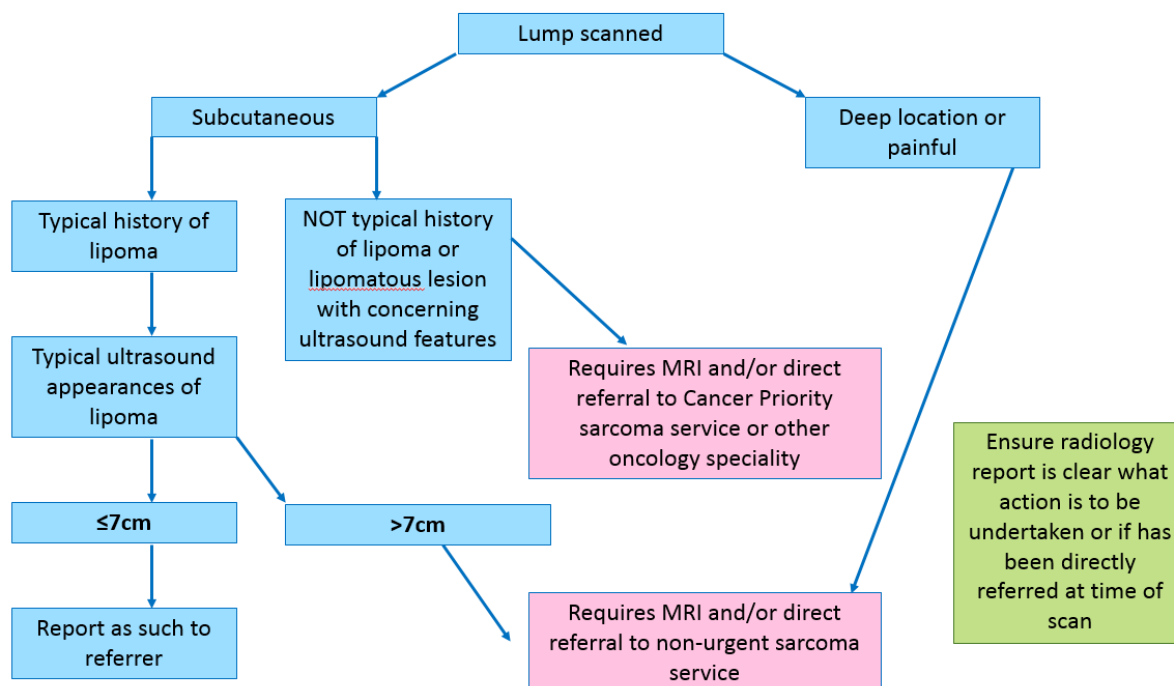


Figure 6: An example of a flow chart for a lipomatous lesions pathway (based on British Sarcoma Group, 2019 [Ultrasound screening of soft tissue masses in the trunk and extremity](#))

Fibrous lesions

These may be benign or malignant fibromas and can be diffuse or focal. On ultrasound they are typically solid but relatively hypoechoic.

A benign fibroma tends to typically occur on the plantar or palmar location.

Fibrosarcomas have typical features, often expected in suspicious/malignant masses (refer to '[general scanning principles](#)')

Nerve sheath tumours

Nerve sheath tumours are derived from Schwann cells and range from the benign neurofibromas



During ultrasound examination, sonopalpation may cause the Tinel sign (tapping or pressing of the lump elicits sensory alterations such as 'pins and needles' or electric shock type pain). An understanding of neurological pathways can assist the ultrasound practitioner in isolating which nerve might be the cause of clinical symptoms and can be confirmed by sonopalpation and any resulting Tinel sign. This can be documented in the report.

and schwannomas to malignant peripheral nerve sheath tumours (MPNSTs).

Recognition of the mass as a fusiform swelling arising from the nerve on ultrasound will suggest nerve sheath tumour such as neuroma or neurofibroma as the main differential diagnosis. Acentric locations of the lesion may be more indicative of a schwannoma.

MPNSTs have typical features often expected in suspicious/malignant masses (refer to '[general scanning principles](#)').

Vascular malformations

Vascular malformations are not uncommon. However, their diagnosis on ultrasound is fraught with pitfalls due to the variation in presentation and ultrasound features. This variation may be due to the location, type of vessel component (capillary, venous, lymphatic, arterial and hybrid subtype) and the blood flow dynamics (high and slow flow lesions) ([Samadi and Salazar., 2019](#)). Vascular malformations may be focal or diffuse. They can occur almost anywhere in the body and involve varying components including fascia, skin, bone, muscle and fat.



Visually examine the external skin surface, which may demonstrate a blue tinge to the lump.

The list below highlights the varied ultrasound appearances:

- Well-defined/diffuse, homogenous/heterogeneous, hyperechoic/hypoechoic
- Unilocular, multilocular
- Phlebolith calcifications
- Thrombus may be present
- Doppler may reveal various flow characteristics from minimal/none to highly vascular with both venous and arterial traces

MRI evaluation may be useful in equivocal masses with the likely differential diagnosis of a vascular malformation.

Cystic lesions

The most common referrals for possible cystic lesions are for '?ganglia' or '?synovial cysts'. Although ganglia and synovial cysts are used interchangeably, they are histologically different. The majority of

ganglia are smooth-walled hypoechoic or anechoic cystic structures, although it is possible for them to exhibit more complex appearances and loculations.



Try to determine whether the cystic structure (ganglion/synovial cyst) is related to the underlying joint capsule or tendon sheath. It may also be important for the referrer to know the proximity to the nearest neurovascular bundle if intervention is a consideration.

Haematoma

Ultrasound appearances of haematoma are variable depending on the time elapsed post-haematoma occurrence. The cause of a haematoma is usually trauma, but rarely, may also be due to an underlying tumour that is bleeding. Clinical history is vital as a haematoma due to injury requires significant force unless the patient is taking anticoagulation therapy when it may occur more readily. Thorough initial scanning to exclude the presence of an underlying tumour is required but if not seen, consideration should be given to performing an interval scan at 8 to 12 weeks post injury to assess for liquification, reduction in size or resolution, depending on the clinical presentation. Care should be taken not to re-scan too quickly as underlying STSs are often slow growing, so too short an interval may lead to false reassurance.

If ultrasound appearances suggest haematoma without significant injury, prompt referral for further imaging is suggested.

Bony lesions

Ultrasound referrals for lumps and bumps can sometimes be related to bony pathology.

In the case of a hard lump in the post-trauma period, an assessment for 'unresolved haematoma' may result in the diagnosis of myositis ossificans. This may be confirmed, or the extent evaluated further, on plain film x-ray if required or MRI, if sarcoma remains a differential.



If there is clinical suspicion of an infected collection, take note of how far the infection source is from the bony cortex and assess if there is any possible cortical involvement, such as periosteal reaction. This must be highlighted to the referrer to help exclude osteomyelitis.

Sister Mary Joseph nodule

A Sister Mary Joseph nodule is a rare but important appearance to recognise. It is a metastatic deposit which is suggestive of intra-abdominal or pelvic cancer and presents as a palpable lump in the umbilicus. These nodules may be clinically painful or rapidly growing.

Ultrasound appearances of a Sister Mary Joseph may include a solid, heterogeneous, hypoechoic and hypervascular lesion seen in the umbilicus.

Superficial endometriosis

Commonly referred as an investigation for 'lump ?cause or ?hernia', Caesarean scar endometriosis within the abdominal wall can appear as rounded, heterogeneous, hypoechoic lesions within surrounding hyperechoic fat in the area of the incision. In addition, spiculated margins that infiltrate into the surrounding tissue may be present. Typically, they have no internal Doppler flow ([Kocher et](#)

[al., 2017](#)). A desmoid tumour may mimic abdominal wall endometriosis, so it is important that the referrer gives a good clinical history.

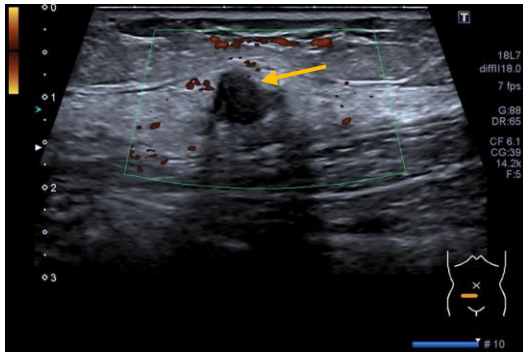


Figure 7: Caesarean scar endometriosis presenting as a palpable lump

Management advice

Where sarcoma is suspected, a referral to a specialist sarcoma service should be recommended as an urgent cancer priority.

Where there is expertise and pathways in place, the ultrasound practitioner may refer directly for alternative imaging or recommend this within the report.

Hernia

A hernia may be defined as a protrusion of tissue through a discontinuity of fascia or musculature that would usually contain it. Clinicians requesting scans for suspected hernia need to know four things:

- Location of hernia
- Size of the neck
- Whether it is reducible
- What the contents are (fat and/or bowel)

Therefore, ultrasound practitioners require a good understanding of common hernia sites and the dynamic appearance of herniae when performing these examinations.

Groin hernia

A groin hernia may be categorised into two main categories, **inguinal** or **femoral**.

An inguinal hernia may be **direct** or **indirect** in nature:

- **Indirect inguinal herniae** pass along the inguinal canal via the naturally occurring deep ring. There is no focal defect in the inguinal canal in cases of indirect inguinal hernia. On ultrasound, indirect inguinal herniae are seen originating at the level of the deep inguinal ring as omental fat and/or bowel pass up, and over the inferior epigastric vessels at the junction with the iliac vessels. Indirect inguinal herniae allow hernia content to travel in a horizontal direction along the inguinal canal.
- A **direct inguinal hernia** is so called as there is a direct defect seen within the walls of the inguinal canal through which omental fat and/or bowel can herniate. Direct inguinal herniae originate medial to the inferior epigastric vessels and often have a much more vertical direction on ultrasound. A direct inguinal hernia is the protrusion of part or the whole of an organ or tissue through a weakness in the posterior wall of the inguinal canal.



The inguinal canal runs from the deep inguinal ring, located at the level of the inferior epigastric vessel's junction to the iliac vessels, to the superficial inguinal ring, seen lateral to the pubic tubercle. Visualisation of the inguinal canal is easier in males due to the presence of the echogenic spermatic chord. In women the inguinal canal contains an extended fold of peritoneum called the canal of Nuck and the round ligament of the uterus, which may be more challenging to locate.

Femoral herniae are more common in women and present as omental fat and/or bowel passing throughout the femoral canal, which is located immediately superior to the junction between the great saphenous and common femoral veins. Where no femoral hernia is present, the Valsalva manoeuvre at this level will dilate the common femoral vein to approximately twice its normal size at rest. When a femoral hernia is present, the Valsalva manoeuvre at this level will often cause the hernia contents to compress the vein from the medial aspect. This can result in a crescent moon appearance of the common femoral vein.

Canal of Nuck hernia is the female equivalent of a hydrocele, although these may also contain omental fat and/or bowel. A hernia of the canal of Nuck occurs when fluid, omental fat, or bowel passes through the female inguinal canal along an extension of the peritoneum which leads to the labia majora.

Abdominal hernia

An **epigastric hernia** presents as a bulge between the xiphoid process and the umbilicus through a focal defect in the linea alba. It usually contains only fatty tissue



PITFALLS:

- An epigastric hernia may be misinterpreted as a lipoma by inexperienced practitioners because the defect in the abdominal wall can be difficult to appreciate.
- Divarication of the rectus abdominis muscles (diastasis recti) is a potential mimic of an epigastric hernia and is most commonly seen in overweight male patients. However, no defect will be seen in the linea alba.

A **Spigelian hernia** is relatively rare and is a defect in the abdominal wall between the lateral rectus sheath and oblique muscles (linea semilunaris).



Because Spigelian herniae are so rare, if suspected, ensure that there is no visible scar, as an incisional hernia is much more likely.

Incisional herniae are common at the site of previous surgery due to weakened abdominal wall.

Paraumbilical herniae are usually clinically obvious in presentation, can be painful and may contain bowel and fat. They are more common in women and have an increased risk of strangulation. They can also result in complications such as bowel obstruction.

Muscle hernia

A muscle hernia or myofascial defects may occur anywhere in the body and is characterised by herniation of muscle tissue through the surrounding fascia into adjacent tissues. Most commonly, muscle herniae are seen in the long muscles of the limbs, such as the tibialis anterior muscle or the long muscles of the arms. These herniae are more common in young adults and in the lower limb.

A muscle hernia will appear as a focal defect in the fascial plane between the muscle and adjacent tissues. The hernia may only be visible on flexion of the muscle, so dynamic scanning is essential to fully review any potential defects.



Due to muscle herniae being located at the level of the myofascial plane and their hypoechoic appearances, care should be taken to differentiate them from neoplastic lesions.

Extending the examination

When there is suspicion of a superficial malignant abdominal nodule, such as a Sister Mary Joseph nodule, recommend urgent abdominal and pelvic scan (either ultrasound or CT) on a 2-week wait pathway. Cross-sectional imaging under an urgent suspicion of cancer pathway is usually recommended to assist with possible staging if required.

If a superficial endometriotic deposit is suspected, for example in a Caesarean section scar, it may be useful for the ultrasound practitioner to consider recommending a TV scan, especially if endometriosis has not been previously diagnosed.



See additional online resources at:

- 19_09 - [Musculoskeletal Ultrasound: Abdominal Wall and Groin](#)

5.2.9.2 'Lumps and bumps' ultrasound reporting examples

Referral for arm lump

Clinical details: new onset of painful lump on left arm. Patient concerned.

Left arm scanned with verbal consent. Chaperone XX present:

The palpable lump on the left forearm corresponds to an elliptical, solid, superficial mass measuring Y x Y x Ycm. No significant vascularity. Ultrasound features are consistent with a small subcutaneous lipoma.

Conclusion:

Subcutaneous lipoma.

Referral for mid-abdominal lump

Clinical details: *Mid-abdominal lump. ?Cause ?hernia.*

Mid-abdominal region scanned with verbal consent. Chaperone XX present:

Scanning directly over the palpable area of concern in the mid-abdomen reveals a 17mm defect in the linea alba through which there is a reducible herniation of fat. There is no evidence of bowel passing through this defect.

Conclusion:

Epigastric hernia.

Referral for possible inguinal hernia

Clinical details: *?right inguinal hernia.*

Inguinal region scanned with verbal consent. Chaperone XX present:

There is a 10mm defect in the right inguinal canal through which omental fat herniates. These appearances are in keeping with a direct inguinal hernia. There is no evidence of bowel passing through this defect.

Conclusion:

Direct inguinal hernia.

Further information can be found at:

- Shah, A., Parameswaran, K., Robinson, P., and Rennie, W. (2020). Non-neoplastic Soft Tissue Tumors and Tumor-like Lesions. *Semin. Musculoskelet. Radiol.* 24, 645–666. Available at: <https://pubmed.ncbi.nlm.nih.gov/33307582/>
- Vibhakar, A.M., Cassels, J.A., Botchu, R., Rennie, W.J., and Shah, A. (2021). Imaging update on soft tissue sarcoma. *J. Clin. Orthop. Trauma* 22, 101568. Available at: <https://doi.org/10.1016/j.jcot.2021.101568>

5.3 Paediatric ultrasound examinations

[updated 2021]

General scanning principles

As ultrasound is painless and radiation-free, it is widely considered the first-line imaging modality for neonates and paediatrics. The Oxford Academic Health Science Network provides an overview of ultrasound for children in a YouTube video: [Having a children's ultrasound appointment in hospital – patient guide](#).

It is good practice for paediatric patients to be scanned in an appropriate environment. Every effort should be made to ensure that the ultrasound scan room is child friendly, including wall decorations and available distractions such as toys, mobiles, ceiling televisions or pictures, while still complying with infection prevention and control policies.

It is recommended that where paediatric patients are not scanned in specialist paediatric hospitals, they are not part of a mixed cohort with adult patients on a general scan list (Department of Health, 2003, [Getting the right start: National Service Framework for children](#)). Where possible, paediatric cases should be booked together on paediatric lists. It is recommended that practitioners with a

special interest in paediatric ultrasound scan these lists, where practicable and appropriate. There may be exceptions to this, for example musculoskeletal (MSK) investigations may need to be scanned on a specialist MSK list rather than a paediatric list.

The room temperature must be appropriate for the age of the child and the examination being performed.

It is important to build trust and rapport, depending on the age of the child/young person, before starting the examination or asking them to lie on the couch. Positioning of the patient for the ultrasound examination may be dependent on the co-operation of the child. For example, for a renal examination the distressed child may be more at ease sitting on an adult's knee in a 'bear hug' embrace ([Paliwalla and Park., 2014](#)).



Communication with a young person is often the key to a successful ultrasound examination. Never patronise or assume a young person will not understand. Explain and show. Talk to the patient/young person as well as the carer/mum/dad to make them feel valued ([Paliwalla and Park., 2014](#)).

The practitioner should have a methodical process which is a standardised approach to scanning the paediatric abdomen, but also be prepared to improvise where necessary to accommodate the child, as this patient demographic can often be unpredictable ([Paliwalla and Park., 2014](#)).

Requirements for neonates will be different from those for young people. If neonates are coming to the department from the ward, particularly if in an incubator, they should be out of the neonatal unit for the minimum time possible. This should be considered when arranging appointments.

Justification and clinical history

As with the adult patient, justification of the ultrasound request is essential. It is recommended that departments have clear justification guidelines for vetting of requests based on RCR guidance [Vetting \(triaging\) and cancellation of inappropriate radiology requests](#).

5.3.1 Paediatric liver and biliary tree

The liver

Justification and clinical history

Common clinical scenarios for ultrasound examination of the liver and biliary system in neonates, infants and children include:

- Jaundice
- Antenatal diagnosis of liver abnormality
- RUQ mass
- Hepatomegaly
- Abnormal LBTs
- Upper abdominal pain

Structures to examine and evaluate

It is usually advisable to perform a full abdominal survey. Where this is not possible and the request is purely hepatobiliary, as a minimum examination the liver, biliary tree, gallbladder, pancreas and spleen should be assessed.

Features to look for and include in the report:

- Liver shape, outline, homogeneity and reflectivity
- CD: normal or dilated, intrahepatic ducts (normal measurement varies with age); if the CD is dilated, assess for calculi and/or a mass/lymphadenopathy compressing the duct
- Gallbladder: shape, size, wall thickness and presence/absence of gallstones
- Portal and hepatic vein patency
- Spleen: size, shape, echotexture and position
- Pancreas: relatively larger and of lower reflectivity than an adult pancreas, duct measurement (varies with age) ([Chao *et al.*, 2000](#)).



The normal range of measurements such as liver, spleen and biliary ducts vary with age and height. It is essential that there are locally agreed biometry charts or tables for measurements with a tolerance threshold for normal.

Examples of normal range of measurements are given in the following sources:

- <https://radiologyassistant.nl/pediatrics/normal-values/normal-values-ultrasound>
- [Konus *et al.*, 1998](#)

Technique

Systematic assessment should include the liver, gallbladder, biliary system and intrahepatic vascular structures (intrahepatic and portal veins). Real-time repeated 'sweeps' in TS and LS as well as supplementary intercostal access are best for visualising the region fully. Where it is possible, supine and decubitus positions are helpful. Images to be saved are dependent on local protocols but, as a minimum, should include both lobes of the liver, the hepatic veins draining to the IVC and the portal vein at the liver hilum and the gallbladder.

Size

Use of formal liver measurements is controversial, as alterations in liver volume may not be reflected in isolated measurements. However, it may give a rough indication of enlargement if there are agreed measurement ranges locally.

Echotexture

Normal liver is uniform and minimally hyperechoic or isoechoic compared to normal renal cortex. Where abnormality is suspected, or diffuse liver disease is the clinical indication for the scan, a comparison image of the liver and right kidney should be stored. Focal liver lesions should be described in terms of their shape, size, outline, echogenicity, vascularity and location and a differential diagnosis given where possible.

Many tumours cannot be characterised with ultrasound, so cross-sectional imaging +/- biopsy is necessary to confirm the diagnosis



CT is commonly used in children under the age of 1 year as MRI contrast is not licensed for use in this age group. The [RCR, 2019](#) recommends consulting a paediatric radiologist prior to use of gadolinium-based contrast agents in neonates and children. Further discussion can be found in an article by [Shah *et al.*, 2018](#).

CEUS has been shown to be of value in paediatrics, but its use is 'off-licence' ([EFSUMB, 2017](#); [Rafailidis *et al.*, 2016](#)).

The biliary system

Technique

The gallbladder is normally situated inferior to the right lobe of the liver and varies in size and shape. The gallbladder neck usually sits in the gallbladder fossa, while the fundus is mobile and dependent upon patient position. Utilising different positioning of the patient is often useful to ensure the gallbladder has been fully assessed. As with adults, the paediatric gallbladder is best seen following a period of fasting.



A high-frequency linear transducer may provide greater resolution when the gallbladder is very superficial and in small children.

The CD normally lies anterior to the main portal vein and is best imaged at this point using the liver as an acoustic window and the beam perpendicular to the vein. The duct should then ideally be traced distally to the head of the pancreas. Duodenal gas can sometimes compromise the view but may be moved by altering patient position, applying gentle pressure with the transducer, and/or revisiting the area after a short time interval.

The measurement is from inner lumen wall to inner lumen wall, measured at the porta hepatis. The CD may be up to 1mm in a neonate and 6mm in an adolescent. Locally agreed measurement charts should be used.

Clinical scenarios

Obstructive jaundice in infants and children can be caused by obstructive calculi, choledochal malformations, pancreatic masses (at the head of pancreas), bile duct tumours (rhabdomyosarcoma is the most common type in children), obstructive enlarged lymph nodes or subhepatic masses.

Neonates that present with conjugated hyperbilirubinaemia may have a dilated CD due to inspissated bile within it (haemolysis, total parenteral nutrition, cystic fibrosis). The gallbladder may also contain inspissated bile/small calculi.

Choledochal cyst is a congenital cystic dilatation of the bile ducts. There are different types:

- Type I – dilatation of the extrahepatic CD
- Type II – diverticulum of the CD
- Type III – dilatation of the intra-duodenal CD
- Type IV – intra- and extrahepatic dilatation
- Type V – intrahepatic dilatation only

A neonate presenting with a cyst at the porta hepatis will have either a choledochal cyst or biliary atresia. A choledochal cyst can be seen to connect with the bile ducts, whereas the cyst found in some cases of biliary atresia cannot be seen to connect to the bile ducts.



The gallbladder also has an abnormal appearance in 90% of cases of biliary atresia.

Cases of biliary atresia are associated with situs inversus; the liver may have an odd configuration, often lying centrally in the epigastrium with two equal-sized lobes. The portal anatomy may be unusual and often there is polysplenia.

Spontaneous perforation of the bile duct is when perforation occurs at the junction of the cystic duct/common hepatic duct and the infant presents with jaundice and ascites.

Management advice

Jaundice

Following MDT discussion, magnetic resonance cholangiopancreatography (MRCP) should be performed if a choledochal cyst is found, to determine whether there is a common channel (the pancreatic duct opening into the lower CD rather than the duodenum, leading to pancreatitis).

If a normal scan is found in an infant with conjugated hyperbilirubinaemia, a referral to a paediatric liver specialist is recommended as soon as possible, so that biliary atresia may be confirmed or excluded and managed accordingly.

Trauma

CT is usually the first investigation in trauma, as early liver lacerations may not be visible on ultrasound. Ultrasound can be used in follow-up to measure fluid collections, but CT or CEUS is necessary to monitor for possible development of pseudoaneurysms.

Further information can be found at:

- Bedside Clinical Guidelines Partnership in association with Partners in Paediatrics (2018). [Paediatric Guidelines](#) 2018–20.
 - Updated [2022-2024 Guidelines](#) require member access to PiP

5.3.2 Paediatric urinary system

Neonates

Justification and clinical history

Examples include:

- Antenatal diagnosis of single kidney
- Antenatally diagnosed dilated renal pelvis/hydronephrosis
- Urosepsis

Structures to examine and evaluate

- Position, shape, size, outline and echotexture of the kidneys. Check for dilatation of the collecting system and normal cortical reflectivity. Neonatal kidneys may have increased cortical reflectivity up to 6 months of age and the pyramids appear relatively hypoechoic (not to be confused with cysts).
- The normal renal pelvis can measure up to 10mm in AP diameter. ([Chow et al., 2017](#) Consistency is required to ensure accurate measurement of the intrarenal pelvis ([Arnaud et al., 2020](#)).
- Cystic change within the kidney can represent different pathology. For example:
 - A 'cyst' in the upper pole of a kidney may be an obstructed upper pole moiety in a duplex kidney, associated with a ureterocele.
 - No normal renal parenchyma evident, with several cysts in the renal fossa, might represent multicystic dysplastic kidney.
- Check the urinary bladder shape, wall thickness and for any evidence of lower ureteric dilatation or ureterocele.

Bipolar length changes with age and height in paediatric patients. It is essential that there is a locally agreed chart or table for normal measurements with a tolerance threshold, for example [Han and Babcock, 1985](#).

If the renal pelvis is dilated, follow-up scans should be performed as appropriate. This may depend on local protocols and severity of dilatation.

Further information regarding antenatally detected renal pelvic dilatation can be found in the [BMUS Guidelines for postnatal ultrasound referrals for follow-up of antenatally detected renal pelvic dilatation](#) [updated 2025]

Children

Justification and clinical history

Examples include:

- Clinically proven UTIs
- Haematuria
- Unexplained paediatric hypertension

Structures to examine and evaluate

Assess both kidneys for position, shape, size, outline and echotexture, in addition to collecting system dilatation and cortical reflectivity.

The bladder shape and wall thickness should be assessed, while also checking for evidence of lower ureteric dilatation or ureterocele. If the patient is able to micturate when asked, a post-micturition bladder scan should be performed to ensure complete emptying.

Common clinical scenarios

If only one kidney is seen in the normal position and it is a normal size, there may be an ectopic kidney, often located in the pelvis. If the kidney is hypertrophied, the other kidney might have involuted (multicystic dysplastic kidney found antenatally) or be absent (unilateral renal agenesis).

Abnormal orientation of the kidneys could be linked to embryological development:

- Horseshoe kidneys is where the lower poles are more medial than the upper poles, with a bridge of tissue connecting the two lower poles across the midline.

- Crossed-fused renal ectopia is when both kidneys lie on the same side and are fused. There are different types of fusion, but they usually result in malrotation of at least one kidney.

When there is a ureterocele in the bladder there is often obstruction of the upper moiety of a duplex kidney.

Other causes of fluid collections within the kidney include hydronephrosis, ureteropelvic junction (UPJ)/PUJ obstruction or vesicoureteric junction obstruction.

Cysts are uncommon in children. If seen, they could be associated with tuberose sclerosis.

There are different types of cystic disease of the kidneys. These include the following:

- Autosomal recessive (infantile) polycystic kidney disease is an autosomal recessive disorder associated with congenital hepatic fibrosis. Kidneys are often enlarged and hyperechoic, as they contain multiple often tiny cysts, which lead to increased reflectivity.
- Autosomal dominant (adult) polycystic kidney disease (ADPKD) is an autosomal dominant condition which may occasionally be present in childhood. Appearances can be of renal cysts, which are of particular significance in children with a family history of ADPKD ([Macrae Dell., 2011](#)).

UTIs are common in young children. NICE has guidelines for the imaging of children under 16 ([NICE, 2022 \[NG224\]](#)).

The most common paediatric abdominal tumour is Wilms' tumour (nephroblastoma). This is a malignant renal lesion which is a solid, heterogeneous mass that may contain areas of necrosis or haemorrhage. Spread can sometimes be seen in the renal vein, IVC and contralateral kidney.

Extending the examination

If a suspected Wilms' tumour is detected, it is good practice to extend the examination to look for spread in the renal vein, IVC and contralateral kidney and to assess the abdomen for other signs of spread such as liver metastases. It is also important to differentiate between a renal mass and suprarenal mass, such as neuroblastoma, as the clinical presentation can be similar.

Management advice

In cases of secondary paediatric hypertension in the event of normal ultrasound findings, catheter angiography and the decision to proceed or not would be made in the context of a multidisciplinary meeting involving the paediatric nephrologist.

Further information can be found at:

- Paliwalla, M., and Park, K. (2014). A practical guide to urinary tract ultrasound in a child: Pearls and pitfalls. *Ultrasound* 22, 213–222.

5.3.3 Paediatric gastrointestinal tract

General scanning principles

Ultrasound is a valuable imaging tool for many paediatric gut disorders and is the primary method of choice for pyloric stenosis, intussusception and appendicitis. High-frequency linear transducers give fine detail and are an important tool in assessing paediatric bowel.

Normal appearances

The mucosal layers in paediatric duodenum and small bowel are not usually well-defined, because they are either collapsed or air-filled. However, when fluid-filled, some parts are recognisable and wall thickness should not be greater than 3mm.

5.3.3.1 Common clinical scenarios

Hypertrophic pyloric stenosis

This condition affects 3 in 1,000, and six times as many boys are affected than girls ([Vinycomb et al., 2019](#)). These infants normally present at between 2 and 6 weeks of age with projectile, non-bilious vomiting.

Technique

- Examine the infant after a 4-hour fast and observe the pylorus during prolonged scanning.
- Turn the infant to the right lateral decubitus position so that any residual fluid in the stomach lies in the antrum over the pylorus and displaces any gas from this area. If there is a significant amount of fluid in the stomach, there is impaired gastric emptying. This is a dynamic study and it is important to watch to see if the canal opens.
- If overlying gas impairs visibility, feed the baby some sterile water from a bottle and watch the pylorus. Alternatively, if a nasogastric tube is present, introduce 20ml of sterile water into the stomach and watch the pylorus; aspirate after the scan if pyloric stenosis is seen.
- Upper limits for normal measurements are:
 - Single muscle wall thickness (not including mucosa or pyloric canal) = 3mm
 - Canal length = 16mm
 - Transverse diameter = 11mm ([De Bruyn and Darge, 2016](#))

At least two values of three should be abnormal to form a diagnosis of pyloric stenosis ([Allan et al., 2011](#)).

Intussusception

Intussusception is an acute condition where a segment of bowel prolapses into a more caudal segment. Infants aged between 6 months and 3 years are most commonly affected. Presentation is typically abdominal pain, redcurrant jelly stools, and palpable abdominal mass ([Allan et al., 2011](#)).

An intussusception measuring more than 2.5cm in transverse dimension is likely to be ileo-colic and needs to be treated acutely. Small bowel intussusceptions are typically intermittent and usually benign. A child with a small bowel intussusception should be rescanned after 10–15 minutes and these intussusceptions will typically resolve. If in any doubt, an acute referral to paediatric surgery is warranted.

Many intussusceptions have no obvious pathology. However, if they occur outside the usual age range it is important to look for a lead point, and 10% are due to Meckel's diverticula, polyps and

duplications. In the older child, lymphoma is the most common cause. Children with cystic fibrosis and post-surgical procedure are also at increased risk.

Features to look for and include in the report

Graded compression technique is the ultrasound method of choice. A segment of bowel prolapses into a more caudal segment and it is seen as 'bowel within bowel' on cross-section. Appearances in transverse are of multiple hyper- and hypoechoic layers mimicking onion rings. Other terminology for this appearance includes the 'target' or 'doughnut' sign. The vascularity of the bowel within bowel should be examined with Doppler as there is an associated risk of ischaemia. Examine the proximal small bowel for dilatation/obstruction. Note if there is free fluid.

Appendicitis

Acute appendicitis is the most frequent cause of emergency abdominal surgery in children. Common presentation is pain, fever, nausea, sickness and anorexia. Graded compression technique is the ultrasound method of choice. See [section 5.2.8](#) for further information on appearances.



See additional online resources at:

- 16_18 - [Abdominal Ultrasound: Paediatric Bowel](#)

Further information can be found at:

- Calle-Toro, J., Kaplan, S., and Andronikou, S. (2020). Are we performing ultrasound measurements of the wall thickness in hypertrophic pyloric stenosis studies the same way? *Pediatr. Surg. Int.* 36, 399–405. Available at: <https://pubmed.ncbi.nlm.nih.gov/31758244/>
- Edwards, E.A., Pigg, N., Courtier, J., Zapala, M.A., MacKenzie, J.D., and Phelps, A.S. (2017). Intussusception: past, present and future. *Pediatr. Radiol.* 7, 1101–1108. Available at: <https://link.springer.com/article/10.1007/s00247-017-3878-x>
- Kelly, B.S., Bollard, S.M., Weir, A., O'Brien, C., Mullen, D., Kerin, M., and McCarthy, P. (2019). Improving diagnostic accuracy in clinically ambiguous paediatric appendicitis: A retrospective review of ultrasound and pathology findings with focus on the non-visualised appendix. *Br. J. Radiol.* 92, 1093. Available at: <https://www.birpublications.org/doi/10.1259/bjr.20180585>
- Plut, D., Phillips, G., Johnston, P., and Lee, E. (2020). Practical Imaging Strategies for Intussusception in Children. *Am. J. Roentgenol.* 215, 1449–1463. Available at: <https://pubmed.ncbi.nlm.nih.gov/33084362/>

5.3.4 Paediatric neck lumps

[2025]

Paediatric neck lumps can be a common finding in paediatric patients. Guidance is available in the BMUS document leading to confusion regarding referral. Help with this can be found here [BMUS Paediatric neck lump guideline](#).

5.3.5 Neonatal hip

Justification and clinical history

Breech delivery and family history of developmental hip dysplasia are the most common referral criteria. However, local practice and the [Newborn and Infant Physical Examination screening programme \(NIPE\)](#) guidelines should be taken into consideration when justifying referrals.

New screening guidance issued in 2021, updated 2025, for neonatal hips can be found at [NIPE newborn hip screening: screen positive pathway](#). Timing of ultrasound scanning is critical and may result in long-term negative consequences for the infant if missed. The new guidance recommends that any infant born after 34 weeks gestation should be offered an ultrasound examination between 4 and 6 weeks of age and, if findings are abnormal, be reviewed by an orthopaedic specialist by 6 weeks of age. If the birth date is earlier than 34 weeks gestation, the ultrasound scan should be arranged for between 38 and 40 weeks corrected gestational age with review by an orthopaedic specialist by 40 weeks corrected age. **[2021]**

Technique

It is helpful to put the child in a cradle, if available, as it keeps them in the lateral position comfortably. Scan longitudinally over the greater trochanter parallel to the cradle to obtain a coronal image of the acetabulum at its maximum depth.



Obtaining a quality image is easiest with the baby in a true lateral decubitus position.

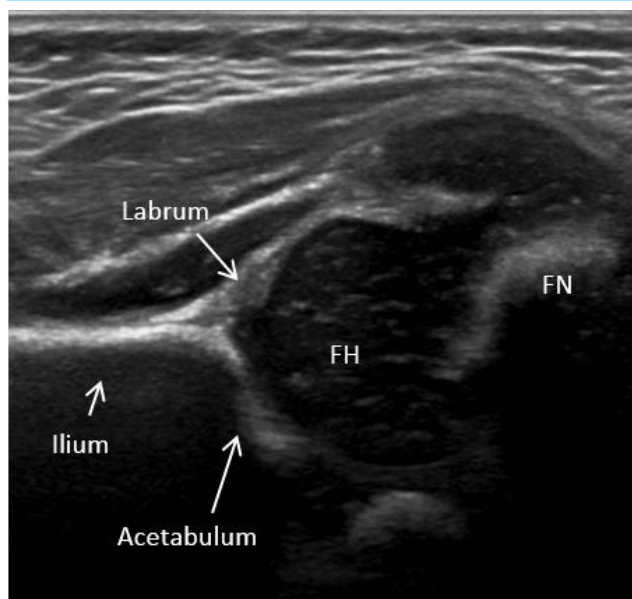


Figure 8: This section should be obtained including the straight line of the ilium, labrum, acetabulum and femoral head (FH) and neck (FN).

The α angle gives the depth of the acetabulum and correlates with maturity of the hip. The baseline goes along the straight lateral margin of the ilium. The second line goes from the inferior point of the iliac bone tangential to the bony acetabulum. An angle of $\geq 60^\circ$ is normal. A smaller angle indicates dysplasia.

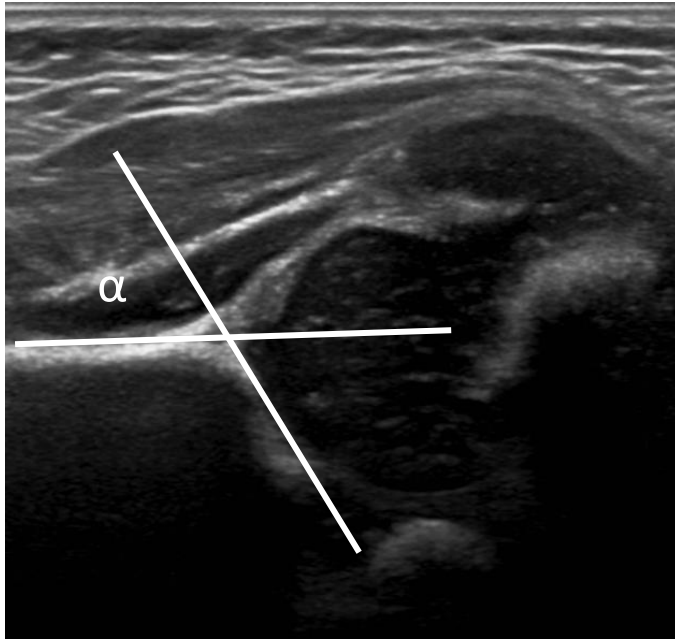

Figure 9: The α angle measurement using the Graf technique

A shallow acetabulum in an infant less than 3 months old may be physiological immaturity, but if found after 3 months of age it signifies dysplasia. However, under the new guidance, these infants should all be reviewed by an appropriate clinician following the ultrasound ([NIPE, 2021](#), updated 2025).

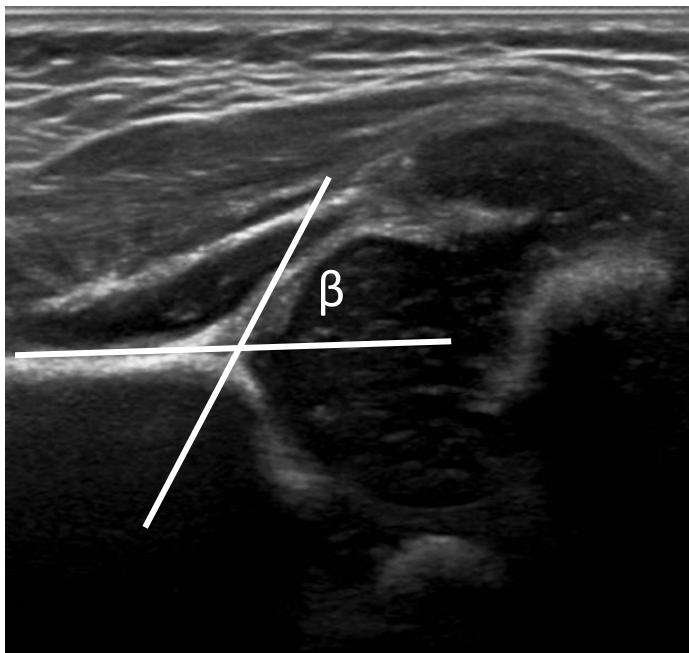


Figure 10: The β angle measurement using the Graf technique

The β angle is useful for classifying the degree of dysplasia. The β angle correlates with stability of the hip and is formed between the vertical cortex of the ilium and the triangular labral fibrocartilage. A β angle of $\leq 55^\circ$ is regarded as normal. There is considerable variability in the measurement of this angle and it is therefore not always used.

Neither angle can be measured if the hip is dislocated. It is helpful to move the hip and observe it during manipulation to see if it subluxes. If the β angle is not formally measured, a comment about stability should be made, such as 'the hip is stable' if no movement is seen, or 'the hip subluxes on stress'.



Femoral head ossification can be seen any time between 2 and 8 months.



See additional online resources at:

- 19_06 - [Musculoskeletal Ultrasound: Neonatal and Paediatric Hip](#)

Further information can be found at:

- Graf, R. (2017). Hip sonography: background; technique and common mistakes; results; debate and politics; challenges. *Hip Int.* 27, 215–219. Available at: <https://pubmed.ncbi.nlm.nih.gov/28497455/>
- Graf, R., Lercher, K., Scott, S., and Spiess, T. (2017). Essentials of infant hip sonography according to Graf (Doctors Academy Publications) Available at: <https://doctorsacademy.org/coursenw/ihu/IH%20COURSE%20MANUAL.pdf>
- Kolb, A., Benca, E., Willegger, M., Puchner, S.E., Windhager, R., and Chiari, C. (2017). Measurement considerations on examiner-dependent factors in the ultrasound assessment of developmental dysplasia of the hip. *Int. Orthop.* 41, 1245–1250. Available at: <https://link.springer.com/article/10.1007/s00264-017-3455-9>
- NHS England (2024). Newborn and infant physical examination screening: standards. Available at: <https://www.gov.uk/government/publications/newborn-and-infant-physical-examination-screening-standards>
- NHS England (2025). NIPE newborn hip screening: screen positive pathway. Available at: <https://www.gov.uk/government/publications/newborn-and-infant-physical-examination-programme-handbook/nipe-newborn-hip-screening-screen-positive-pathway>.
- Schams, M., Labruyère, R., Zuse, A., and Walensi, M. (2017). Diagnosing developmental dysplasia of the hip using the Graf ultrasound method: risk and protective factor analysis in 11,820 universally screened newborns. *Eur. J. Pediatr.* 176, 1193–1200. Available at: <https://link.springer.com/article/10.1007/s00431-017-2959-z>

5.3.6 Neonatal intracranial

General scanning principles

The ultrasound practitioner should be aware of the potential bio-effects of diagnostic ultrasound, particularly heating at the brain/skull interface, and ensure that the power output is set to the minimum consistent with obtaining high-quality diagnostic ultrasound images. Doppler should not be utilised except for clearly defined clinical reasons which provide additional diagnostic or prognostic information.

The ultrasound practitioner should be aware of common and less commonly used acoustic windows to the neonatal brain. While the anterior fontanelle is used as standard, the posterior fontanelle can be useful for examining the occipital horn of the lateral ventricles, and the mastoid suture may be helpful in examining the posterior fossa, cerebellum, aqueduct of Sylvius and 4th ventricle.

Justification and clinical history

Ultrasound of the neonatal cranium is usually performed to detect and monitor intracranial haemorrhage and congenital anomalies.

Common clinical indications include:

- Prematurity
- Follow-up of antenatally detected anomalies such as ventriculomegaly, intracranial lesions
- Birth trauma
- Neurological abnormalities

Technique

It is important to keep the neonate warm during the examination and remain mindful of the need for good hygiene and care around equipment.

A high-frequency transducer, 7.5MHz, is often utilised for premature infants, and lower frequencies may be needed for older infants.

Further details, including labelled diagrams, can be found in the article by [Dudink et al, \(2020\)](#) [State-of-the-art neonatal cerebral ultrasound: technique and reporting](#).

Structures to examine and evaluate

A suggested approach for examining the neonatal brain is as follows.

Presence of normal anatomy

The ultrasound practitioner should be aware of normal brain anatomy in the neonate, to include changes with age, presence of midline structures, ventricular appearances, appearances of basal ganglia, periventricular white matter, cerebellum and extra-axial space.

Presence of intracranial haemorrhage

An understanding of common locations of intracranial haemorrhage, how this may vary according to gestational age, and how these may present on ultrasound is essential. Grading of haemorrhage should be according to local agreement and protocol ([Dudink et al., 2020](#)).

Ventricular size

The size of the lateral, 3rd and 4th ventricles should be assessed according to local protocol. Validated measurement techniques (e.g. ventricular indices ([Boyle et al., 2015](#))) should be utilised in cases of ventriculomegaly. This can be useful for assessing change in size over time and guiding the timing of intervention.

Periventricular white matter

It is important to be aware of normal and abnormal appearances of the periventricular white matter and the limitations of ultrasound in examining this region. Follow-up should be considered in cases of periventricular flaring or suspected white matter damage.

Brain parenchyma

The ultrasound practitioner should be aware of normal sonographic appearances of the brain parenchyma and be aware of the potential appearances of acquired abnormalities.

See additional online resources at:

- 20_04 - [Head and Neck Ultrasound: Cranial](#)

Further information can be found at:

- Mohammad, K., Scott, J.N., Leijser, L.M., Zein, H., Afifi, J., Piedboeuf, B., de Vries, L.S., van Wezel-Meijler, G., Lee, S.K., and Shah, P.S. (2021). Consensus Approach for Standardizing the Screening and Classification of Preterm Brain Injury Diagnosed With Cranial Ultrasound: A Canadian Perspective. *Front. Pediatr.* 9, 157. Available at: <https://doi.org/10.3389/fped.2021.618236>

5.4 Head and neck ultrasound examinations

[updated 2021]

General scanning principles

As in all areas of ultrasound, practitioners need to be aware of the various clinical scenarios that can propagate ultrasound requests. In order to carry out a competent examination and issue a helpful report, it is essential that the ultrasound practitioner understands the question that is being asked. For example, in cases where a head and neck malignancy is suspected, a full examination of all the major lymph node territories is required in order to accurately stage and optimally manage the patient.

The examination may be tailored to a specific area of the neck (e.g. a palpable mass); depending on the findings, the examination may focus on the area in question alone, or may need to be expanded to assess the neck as a whole. For example, in a patient with a posterior triangle mass, if the finding is that of a small superficial lipoma, the examination can be contained to that area in question. The extent of the study should be recorded in the report, e.g. "I have not examined the remainder of the neck". However, if the ultrasound examination identified a necrotic lymph node which is potentially metastatic, a full assessment of the neck in its entirety is mandatory.

Justification and clinical history

Palpable head and neck lumps are a common referral. The three most common masses that present to head and neck lump clinics are lymph node, thyroid and salivary.

It is important to state that not all referral reasons specified below are justified from all referrers. There are times when some of these are specialist referrals only. Individual departments will need to negotiate referral reasons accepted by the referral groups (e.g. from primary care, GPs with speciality interests, secondary care) depending on the levels of service provision, expertise available and other available modalities.

Referrals may also include, but are not limited to the following:

- Referrals for superficial lumps such as 'epidermal inclusion cyst' and 'lipoma' can often appear on head and neck lists
- Endocrinology referrals e.g. 'parathyroid adenoma'
- Thyroid cancer surveillance
- Head and neck cancer staging
- Follow-up post-surgical procedure
- Possible abscess formation

With head and neck lumps, clinical history is important to aid in a differential diagnosis in the radiology report and should be considered where relevant. Examples include:

- Age
- Sex assigned at birth
- Smoking history
- Duration of lump/changes in size/single/multiple/location of lump/firmness and mobility of the lump
- Changes in voice
- Blood test results, e.g. TSH/T4/TPO, lymphocytosis
- Recent and previous medical history, e.g. previous cancer, site of tumour, recent dental issues

Technique

Ultrasound of the neck is often performed with the patient supine or semi-recumbent depending on the preference of the ultrasound practitioner. A high-frequency linear transducer, such as 14MHz, is often utilised with the frequency adjusted, for example to examine as much of the deep parotid gland as possible.

In the investigation of suspected parathyroid adenoma, hyperextension of the neck over a pillow is required, whenever possible, to assess for inferior parathyroid adenoma, which are often inferior to the thyroid. If parathyroid enlargement is not initially discovered with a high-frequency probe, ensure the pathology is not deeper by using a 3.5MHz curvilinear transducer.



A thyroid nodule scoring system should be standard practice when nodules are detected, as per the [British Thyroid Association \(BTA\) guidance](#) (2014).

It is recommended that only those practitioners who are competent in full neck ultrasound assessment, e.g. the 'seven sweeps' technique, should undertake head and neck/thyroid scanning. A technique such as the seven sweeps has the advantage of being a reproducible standard and proficient teaching technique, discouraging target scanning, following the path of the surgical neck levels, and reducing the possibility of missing additional findings. Table 9 highlights the anatomy that may be seen in each of the seven sweeps.

TABLE 9: Seven sweeps technique for assessing the neck

		Anatomy
Sweep 1	Submental region: chin to hyoid	Anterior bellies of the digastric, myelohyoid muscle, geniohyoid and genioglossus muscles, sublingual glands, lingual artery, submandibular duct, level Ia lymph nodes
Sweep 2	Submandibular region	Submandibular gland, myelohyoid muscle, hyoglossus muscle, submandibular duct, retromandibular vein, level Ib lymph nodes
Sweep 3	Parotid and buccal region	Parotid gland, retromandibular vein, external carotid artery, posterior belly of the digastric muscle, masseter muscle, buccinator, intra-parotid lymph nodes
Sweep 4	Jugulodigastric region and deep cervical chain: mandible to medial clavicle	Internal jugular vein, carotid artery(ies), omohyoid muscle, levels II, III and IV, sternocleidomastoid muscle
Sweep 5	Supraclavicular fossa: mid-clavicle to trapezius muscle	Subclavian vessels, scalenus muscles, brachial plexus elements, transverse group of lymph nodes level V, levator scapulae muscle
Sweep 6	Posterior triangle	Trapezius muscle, levator scapulae muscle, posterior sternocleidomastoid muscle, posterior triangle lymph nodes (level V)
Sweep 7	Anterior infrahyoid neck: hyoid to suprasternal notch	Larynx, trachea, hypopharynx, thyroid gland, pre and para tracheal lymph nodes (level VI)

Depending on the service provided in local departments, there may be a role to distinguish levels of practice. Head and neck scanning competencies could be organised into a tiered system, e.g. levels I (mainly primary care referrals), II (mainly primary care referrals and non-complex secondary care referrals) and III (referrals from all sources including complex cases). Standards of practice which may be used as a benchmark can be found in the BMUS (2021) document [Head and neck ultrasound practice standards](#).

5.4.1 Common clinical scenarios

Lymph nodes

Knowledge of the major lymph node territories and chains is essential. An understanding of the interchange between terminology used in the description of lymph node groups/chains (e.g. deep cervical/jugular chain) and the commonly used level classification system is fundamental to head and neck cancer management. Confusion in this area can be easily created, in both requesting and reporting. Knowledge of the typical criteria for the ultrasound differentiation of benign and malignant lymphadenopathy is essential. Descriptive reports that fail to classify the nodes into benign, equivocal or possibly/probably malignant are unhelpful.

Benign nodes are classically fusiform in shape, contain a hyperechoic hilum (can be difficult to appreciate, however, in some smaller lymph nodes) and possess a central hilar blood flow pattern. Malignant lymph nodes tend to be rounded and the central hilum is generally absent; they contain areas of coagulation or cystic necrosis and exhibit deranged blood flow pattern with areas of vascular sparing and peripheral vessels (which can be seen as avascular foci of cystic change or

increased reflectivity). Nodal metastases from papillary carcinoma of the thyroid are typically more hyperechoic and contain punctate micro-calcification.

Lymphoma classically presents as markedly hypoechoic nodes (even a pseudocystic appearance), rounded often with plethoric blood flow which commonly displays a benign central hilar pattern. As the architecture of lymphomatous nodes is preserved, this is mirrored in preservation of the 'benign' hyperechoic hilum sign.

It is important not to rely on size as a predictor for benignity or malignancy, but rather create an overall picture of nodal structure in the assessment of lymph nodes.

Salivary glands

The major salivary glands which can be identified and assessed on ultrasound are the submandibular gland (SMG), and the parotid and sublingual glands.

Ultrasound is the optimal initial investigation for a patient with a salivary gland mass, so the practitioner needs to be aware of the common appearances of salivary gland tumours. The vast majority of salivary gland neoplasms are benign, of which 80% will be benign pleomorphic adenomas and mainly occur in the superficial parotid (i.e. accessible to sonographic assessment). They are typically lobular and hypoechoic, often with a pseudocystic appearance. Cystic change is suggestive of Warthin's tumours, as are multiplicity and contralateral tumours.

Ultrasound can identify features of high-grade salivary gland malignancy. The key findings are an irregular, spiculated contour and presence of adjacent, regional lymphadenopathy. Low-grade salivary cancer is often indistinguishable from benign tumours; hence, tissue sampling is mandatory in the investigation of a salivary gland tumour.

Lymphoma of the salivary glands is rare, but classically occurs in the setting of Sjögren's syndrome; these patients have significantly increased risk of mucosa associated lymphoid tissue (MALT) lymphoma. The ultrasound finding of a markedly hypoechoic mass within the parotid parenchyma in this clinical setting should raise suspicion of MALT lymphoma.



As the size of the salivary gland decreases, the incidence of salivary tumours decreases but the likelihood of malignancy actually increases.

Intra-submandibular gland masses are rarer than parotid gland masses, and care must be taken to ensure that the mass is not extra-glandular indenting on the gland, i.e. level Ib or II lymphadenopathy, or a tail of parotid gland mass.

Mylohyoid boutonnière (herniation of the sublingual gland through a discontinuity in the mylohyoid muscle) can give rise to an intermittent lump in the neck or, as is more usual, an incidental asymptomatic finding. It is so common that some regard it as a normal variant of anatomy.

Thyroid gland

Practitioners should be aware of the typical features that enable a diagnosis of a benign thyroid nodule to be made and those features that indicate a potential malignancy. These have been outlined in the latest issue of the [British Thyroid Association \(BTA\) Guidelines](#) (2014), which provide a pattern-based system of risk stratification with image examples of lesion type. The BTA guidelines are widely used across the UK and enable thyroid nodules to be stratified into benign (U2), indeterminate (U3), suspicious (U4) or malignant (U5) categories. Tissue sampling with fine needle

aspiration (FNA) or core biopsy is typically indicated for those in the indeterminate to malignant categories (U3–U5). Reports should therefore outline the features displayed and indicate in which category the findings sit, allowing appropriate management. Typical descriptive terms are included in the BTA guidelines.

Benign nodules may show micro-cystic or cystic change with 'ring-down' signs of colloid, eggshell (peripheral) calcification and peripheral colour flow. They are typically hyperechoic or isoechoic in relation to the background echo texture, whereas a solid hypoechoic nodule which contains micro-calcification is highly suggestive of a thyroid carcinoma, typically a papillary carcinoma. The shape of the nodule ('taller rather than wide') is also a sign of potential malignancy, with 'tall' being defined as increased anterior posterior diameter. When a carcinoma is suspected, a search for potential lymph node metastases is required, together with a decision to proceed to FNA or core biopsy in line with local guidelines.

5.4.2 Fine needle aspiration (FNA)/core biopsy

Where appropriate, and where the expertise exists, FNA/core biopsy can be performed to extend the examination and diagnostic pathway. It may also be recommended or suggested in the report if it is not possible to perform it at the time of the examination, in accordance with local practice. If biopsy is deemed necessary, it is good practice for this to be arranged by the ultrasound practitioner, rather than leaving it for the referrer, which can lead to delays in patient management. Local protocols should be in place to cover this scenario.



Ultrasound +/- FNA or core biopsy in a single attendance is the expected standard in specialist ultrasound practice.

Management advice

Where expertise exists, and following local agreement, the head and neck specialist practitioner may make recommendations for further imaging or request this directly. For example, if the deep margin of a parotid lesion is not fully visualised, further imaging with MRI or CT is required to assess deep lobe extension and may be organised directly.

5.4.3 Head and neck ultrasound reporting examples

Referral for palpable mass (primary care referral)

Clinical details: Right upper/mid-cervical mass, increasing in size for past 3 months. Smoker. O/E hard mass in right upper cervical region? Nodal. Nil else on examination.

Cervical ultrasound performed with verbal consent. Chaperone XX present:

The palpable mass is identified as a 3.4cm diameter lymph node mass in the right upper deep cervical chain. There are signs of coagulation necrosis and possible extra capsular spread consistent with a metastatic lymph node from a potential SCC primary.

Further rounded suspicious nodes are seen in the right mid deep cervical chain. Nodes identified in the right submandibular region and lower deep cervical chain and right posterior triangle – these, however, all have benign features by ultrasound criteria.

The left side of the neck appears normal. The salivary glands and thyroid appear unremarkable. A few incidental benign nodules are seen within the left lobe of thyroid; however, no sinister features (U2).

An ultrasound-guided FNA (21g) on the right upper deep cervical lymph node has been performed, specimen obtained and sent for cytology. No immediate post-procedural complications.

An urgent ENT referral should be made in order to discuss results and any onward further management required.

Conclusion:

Probable metastatic right upper and mid deep cervical chain lymphadenopathy, FNA performed. Urgent ENT referral recommended.

Referral for ?thyroid mass

Clinical details: Patient complaining of fullness in lower neck, O/E ?small goitre.

Cervical ultrasound performed with verbal consent. Chaperone XX present:

The thyroid gland is mildly enlarged due to the presence of multiple small isoechoic nodules which are identified in both lobes of the thyroid. Several of the nodules exhibit cystic change with ring-down signs, indicative of colloid. Multicystic/spongiform change also seen. No sinister features by ultrasound criteria.

No significant associated lymphadenopathy and no retrosternal extension present.

Conclusion:

Small benign multinodular goitre. No sinister features. Radiological classification U2 – benign.

Referral for staging ultrasound examination (Maxillofacial referral)

Clinical details: Left lateral/posterior tongue primary SCC, T3. Smoker. Left Level II nodes on examination ??right II nodes also, ?Bilateral metastases.

Cervical ultrasound performed with verbal consent. Chaperone XX present:

The tongue primary tumour can be identified on ultrasound, within the posterior left tongue. It measures 1.6cm (AP) by 1.1cm (coronal) diameter but does not cross the midline. Superior/inferior diameter is difficult to assess but measures 1.9cm.

There are multiple rounded lymph nodes with signs of coagulation necrosis in the left level II region; largest measures 2.1cm in maximum diameter. There are also similar smaller nodes in the upper mid deep cervical chain (level III). Features are those of metastatic lymphadenopathy.

There are small nodes in the superior left submandibular region (level Ia & Ib) and posterior triangle (level V) which all have benign features by ultrasound criteria.

Assessment of the right neck demonstrates benign appearing nodes in the right level II. No evidence of contralateral lymph node metastases.

FNA of the largest node in the left upper deep cervical chain (level II) performed, no immediate post-procedural complications identified. Haemorrhagic and necrotic material obtained and sent for cytology.

Conclusion:

Left tongue base/mid-tongue tumour, with left upper and mid deep cervical chain (levels II & III) lymph node metastases. FNA performed on left upper deep cervical node. No contralateral lymph node metastases seen.

Further information can be found at:

- Allan, P.L.P., Baxter, G.M., and Weston, M.J. (2011). Clinical ultrasound (Churchill Livingstone).
- Grégoire, V., Ang, K., Budach, W., Grau, C., Hamoir, M., Langendijk, J.A., Lee, A., Le, Q.T., Maingon, P., Nutting, C., *et al.* (2014). Delineation of the neck node levels for head and neck tumors: A 2013 update. DAHANCA, EORTC, HKNPCSG, NCIC CTG, NCRI, RTOG, TROG consensus guidelines. *Radiother. Oncol.* 110, 172–181.

5.5 Musculoskeletal ultrasound examinations

[updated 2021]

General scanning principles

MSK ultrasound referrals, for the evaluation and treatment of joint and soft tissue diseases, have increased rapidly over recent years. The European Society of Musculoskeletal Radiology (ESSR) published a consensus statement, [Clinical indications for musculoskeletal ultrasound updated in 2017 by ESSR consensus](#).

Advantages of ultrasound include detailed, real-time, dynamic assessment of soft tissues and the ability to compare with the contralateral side. Doppler sonography has been proved to accurately assess the degree of activity in inflammatory disease.

It is important for ultrasound practitioners to learn and understand the clinical background of MSK injury and disease so that their scan and report can contribute in a meaningful way to the patient pathway. Multidisciplinary collaboration is important and gaining clinical experience from colleagues in other professions is extremely helpful.

Contra-indications for MSK scans are unlikely; however, some limitations exist and may include the following:

- Patient obesity
- Inability to see structures that lie deep to bone or intra-articular structures
- Casts, dressings, open wounds/ulcers, which can limit visualisation
- Severe oedema/swelling
- Patients who are unable to co-operate or provide a clinical history due to reduced cognitive functions, e.g. because of Alzheimer's or dementia, or through involuntary movements



The MSK examination should not be limited to a high-frequency linear transducer, especially in cases involving patients with high BMI or to examine deeper structure, such as in the anterior hip. Lower-frequency linear and curved array transducers will enhance the examination in these cases.

As age-related changes are common in the MSK system and may not be the cause of the patient's symptoms, ultrasound appearances must always be taken in relation to the clinical context and the referrer should be made aware of limitations in the report.



Comparison with the contralateral side (assuming it is asymptomatic) will help when determining the clinical significance of age-/activity-related changes and should be imaged and documented in the report.

Justification and clinical history

MSK ultrasound referrals for the evaluation and treatment of joint and soft tissue diseases have increased rapidly over recent years and, in some instances, imaging services have struggled to keep up with demand. Therefore, each request should be justified in terms of appropriateness for ultrasound and should include relevant and useful clinical history. It is well documented that a good-quality referral produces a good-quality ultrasound examination and a useful ultrasound report. A justified ultrasound request will be one that provides a relevant and useful clinical history, e.g. "painful right shoulder with restricted movement, particularly on abduction. Nocturnal pain. Non-resolving with physiotherapy. ?Underlying rotator cuff tear" (BMUS 2022 [Justification of ultrasound requests](#)).



Discussion with the patient regarding their symptoms and taking a clinical history in the ultrasound room can often prove an essential contribution to the ultrasound examination and report. This will apply to all areas of MSK ultrasound examination.

The following clinical history will be important to note, and may aid in the diagnosis or search for pathology:

- Acute or gradual onset
- Activity(ies) that led to onset of symptoms
- Type of symptom, e.g. pain, locking, swelling, snapping, stiffness
- Location of symptoms: anterior, posterior, lateral, medial or pinpoint
- History of surgery or prior treatment attempts
- If pain is a symptom: what type?

Extending the examination

[updated 2025]

Extending the examination is dependent on the expertise, remit and role of the ultrasound practitioner performing the MSK examination. For example, where there is evidence of synovitis in several metatarsophalangeal joints instead of the expected Morton's neuroma, it may be helpful to extend the examination to determine if the patient's pain is also due to synovitis. This should only be

attempted if expertise is available. If not, a note on the report to the referrer should be considered, for example “Is there any clinical evidence of an inflammatory arthritis?”

The BMUS document (2023) [Guidelines for the administration of ultrasound guided musculoskeletal injections](#) provides advice if ultrasound guided soft tissue injection is requested as part of the examination.

There is an increase of the use of ultrasound guidance for medical aesthetics. Guidance for this purpose is available in the BMUS (2023) document [Guidelines for professional diagnostic ultrasound practice in medical aesthetics](#).

Management advice

Where the ultrasound practitioner has the expertise, knowledge and scope, within their practice, further management or imaging may be recommended or requested in the report. For example:

- A referral can be made to orthopaedics, physiotherapy, occupational therapy, podiatry, as relevant.
- If ultrasound examination reveals a high degree of suspicion of a bony tumour or fracture, alternative imaging may be indicated, advised and/or requested where locally agreed protocols exist.

Common MSK pathologies detected using ultrasound

Below is a list of common general MSK pathologies that can be visualised with ultrasound. More detailed descriptions are given for some at specific points later in this text.

TABLE 10: Common MSK pathologies seen with ultrasound

Pathology	Description
Tendinopathy	A continuum of chronic, non-inflammatory tendon ‘degeneration’ which is often age related and due to recurrent microtrauma or ‘injury’. Tendinopathy is seen on ultrasound as focal or global grey-scale changes within a tendon, including loss of the normal fibrillar pattern. In the initial stages, the tendon may appear thickened and oedematous (hypoechoic), but if tearing does not occur, it can progress to a thin, hyperechoic texture over time. These changes can be subtle and difficult to interpret. Comparison with the contralateral side is vital. In some anatomical areas, such as the Achilles tendon or the common extensor tendon of the elbow, increased internal neovascularity has been found to correlate with grey-scale appearances and pain, but in relatively avascular tendons, such as the rotator cuff, detection of neovascularity is relatively uncommon, even in significantly diseased tendons.
Calcific tendinopathy	The deposition of calcium hydroxyapatite crystals within tendons, most commonly around the shoulder. The cause of this deposition is unclear, but it seems to symptomatically affect the rotator cuff tendons in particular and is more common in women than men at around 40–60 years of age. On ultrasound it appears as echogenic deposits within the tendon substance with or without posterior acoustic shadowing, reflecting differences in density over time.

Tenosynovitis	Inflammation of a tendon and its synovial sheath seen on ultrasound and thickening of the tendon sheath +/- thickening of the tendon, usually with hyperaemia detected on Doppler and usually with effusion around the tendon. It is worth noting that effusion alone may reflect a more chronic picture and is not always the cause of current symptoms. Clinical correlation with symptoms is vital. Causes of tenosynovitis include inflammatory arthritis, infections and trauma.
Tendon tears	Usually occur on the background of tendinopathy. If there is sufficient trauma to a normal tendon it may cause avulsion of the tendon from its enthesis, rather than tearing within the tendon itself. Tears may be partial or full thickness or there may be degenerative longitudinal splitting of the tendon. The common tears will be discussed in sections for the individual joint. It is important to realise that even complete tendon tears are not always symptomatic.
Synovitis	Inflammation of the synovial lining of a joint caused by several underlying pathologies such as many inflammatory arthritides and infection. On ultrasound, appearances include capsular thickening, hyperaemia on Doppler and effusion.
Bursitis	Inflammation of the synovial lining of a bursa. Bursae are present around most major joints of the body and provide a cushion between bones and tendons and/or muscles. Their function is to help to reduce friction between structures to allow free movement. Ultrasound appearances include thick-walled, sometimes hypoechoic, sometimes hyperaemic structures, usually containing fluid. The amount of fluid varies, ranging from a small trace to large fluid collections.
Enthesitis	Entheses are areas of connective tissue where tendons or ligaments meet bone. Enthesitis describes inflammation of that tissue and commonly occurs with some inflammatory arthritides. On ultrasound, the entheses can appear disrupted, often hypoechoic due to oedema and with/without colour/power Doppler signal.

5.5.1 Shoulder

Justification and clinical history

Clinical history may include, but not be limited to:

- ? Rotator cuff tear
- ? LHB rupture/dislocation
- ? Post operative cuff failure
- Swellings/lumps

Structures to examine and evaluate

The structures that should be identified and (the majority) imaged in two planes as a minimum, in a standard shoulder ultrasound scan are:

- Long head of biceps tendon (LHBT) in the bicipital groove and at the rotator interval
- Subscapularis tendon
- Infraspinatus tendon
- Supraspinatus tendon
- Any visible bursae around the shoulder; subacromial/subdeltoid, subcoracoid
- Posterior glenohumeral joint for effusion/labral cyst only
- Acromioclavicular joint

Technique

The patient may be seated on the examination couch or in a chair and depending on the practitioner preference, scanned from an anterior or posterior position.

Numerous scan protocols for the shoulder are described in the literature including that from the [ESSR](#) protocol for the shoulder. Training protocols also exist and may be useful to standardise scanning and reporting.

Dynamic assessment using ultrasound may be helpful for the following:

- LHBT: to assess its stability within the bicipital groove during external rotation
- Subscapularis tendon: to identify the myotendinous area which normally sits posteriorly to the coracoid process of the scapula
- Supraspinatus tendon: to assess for bunching of the tendon and/or overlying subacromial bursa against the acromion or coracoacromial ligament during abduction which may be a cause of 'impingement'
- Posterior joint recess: during internal/external rotation, to assess for a glenohumeral joint effusion; this will be most evident during external rotation

Rotator cuff tears

Rotator cuff tendon tears are often seen in asymptomatic individuals and are not always the cause of symptoms. It is sometimes difficult for the ultrasound practitioner to appreciate the significance of a tear based on the patient's clinical symptoms, and while it is important to evaluate and accurately describe tears, care should be taken if discussing scan findings with the patient.

Type, size and location of tears is important, and measurements should be made in two planes: anterior to posterior (transverse) and medial to lateral (longitudinal). The site of the tear measured from the rotator interval is also useful.

The supraspinatus tendon can be divided into anterior, mid and posterior portions: the anterior free or leading edge that lies adjacent to the LHBT at the rotator interval, the mid-substance of the tendon and the posterior portion that abuts the infraspinatus tendon – the distinction between the two tendons can be difficult to define.

Types of tear

Partial thickness tear: A rotator cuff tear that involves either the under-surface, mid-(intra-) substance or bursal surface of a tendon and does not allow communication between the two surfaces. The dimensions of the tear, and/or the percentage depth of the tendon that the tear involves, can be recorded.

Under-surface or articular surface tear: A partial thickness rotator cuff tear involving the articular or joint surface of the tendon. In the supraspinatus, they can be called 'rim rent' or PASTA lesions (Partial Articular Supraspinatus Tendon Avulsion).

Bursal surface tear: A partial thickness rotator cuff tear involving the bursal surface of the tendon. In the supraspinatus tendon, this is sometimes called 'scuffing' as it is caused by friction from the under-surface of the acromion.

Intrasubstance tear: A partial thickness rotator cuff tear within the substance of the tendon, sometimes called concealed interstitial delamination (CID). A cleft is present within the tendon substance, but it does not reach either the bursal or articular surfaces of the tendon.

Full thickness tear: A rotator cuff tear that extends across the whole depth of the tendon and involves both surfaces, resulting in communication between the joint and bursal compartments, regardless of the width of the tear. Some full thickness tears measure over 3cm in diameter, whereas some look like pinholes.

Complete full thickness tear: A full thickness tendon tear that extends across the whole width and depth of the tendon, usually resulting in retraction back from the insertion.

If the tear is complete, the entire width of the tendon will have torn, usually (but not always) at the insertion, and there is retraction of the proximal stump. The degree of retraction will vary but, in the supraspinatus and subscapularis tendons, can result in the proximal stump sitting under the acromion/coracoid and so not be visible with ultrasound. This is an important finding for surgeons because it is less likely that the tendon can be pulled back and repaired.

A supraspinatus tendon tear is generally given an increased level of importance compared to the



See additional resources at:

- 19_02 - [Musculoskeletal Ultrasound: Shoulder](#)

other rotator cuff tendons as it is more often symptomatic and amenable to surgery.

5.5.1.1 Shoulder ultrasound reporting examples

Referral for shoulder pain

Clinical details: Right shoulder pain, ?rotator cuff tear.

Ultrasound of the right shoulder performed with verbal consent. Chaperone XX present:

Normal appearances of the right rotator cuff tendons. No evidence of tears or calcification or any bursal thickening or effusion. The LHBT is intact and correctly located within the bicipital groove. No evidence of a glenohumeral joint effusion.

Unremarkable ACJ noted.

Conclusion:

Normal examination. No right rotator cuff tear seen.

Referral for follow-up post-physiotherapy

Clinical details: ?Rotator cuff tear. No improvement with a reasonable course of physiotherapy.

Ultrasound of the left shoulder performed with verbal consent. Chaperone XX present:

There is an irregular, full thickness tear at the anterior edge of the left supraspinatus tendon. It measures approximately 4mm in width with 5mm retraction from the insertion. The remaining tendon tissue has reasonable depth and texture.

The infraspinatus and subscapularis tendons appear intact. The LHBT is intact and correctly located within the bicipital groove. Tender ACJ on sonopalpation and features consistent with moderate OA noted.

Conclusion:

Full thickness tear of the left supraspinatus tendon. Moderate OA of the left ACJ.

Referral for restricted movement of the shoulder

Clinical details: Shoulder pain, restricted movement, ?primary frozen shoulder.

Ultrasound of the left shoulder performed with verbal consent. Chaperone XX present:

The tendons of the left rotator cuff are intact. The supraspinatus and infraspinatus tendons have good depth and texture with no evidence of a tear or intratendinous calcification.

The subscapularis tendon is difficult to see as the majority lies behind the coracoid process and due to severely restricted lateral rotation, cannot be visualised, but the visible portion appears intact.

No large GHJ or bursal effusions. The LHBT is intact and correctly located within the bicipital groove. Non-tender ACJ OA noted.

Conclusion:

Severely restricted left subacromial and lateral movement which, in the absence of GHJ OA, would support a clinical diagnosis of a 'frozen' shoulder/adhesive capsulitis.

Further information can be found at:

- Awerbuch, M.S. (2008). The clinical utility of ultrasonography for rotator cuff disease, shoulder impingement syndrome and subacromial bursitis. *Med. J. Aust.* 188, 50–53.
- Chianca, V., Albano, D., Messina, C., Midiri, F., Mauri, G., Aliprandi, A., Catapano, M., Pescatori, L.C., Monaco, C.G., Gitto, S., *et al.* (2018). Rotator cuff calcific tendinopathy: From diagnosis to treatment. *Acta Biomed.* 89, 186–196.
- Girish, G., Lobo, L.G., Jacobson, J.A., Morag, Y., Miller, B., and Jamadar, D.A. (2011). Ultrasound of the shoulder: Asymptomatic findings in men. *Am. J. Roentgenol.* 197.
- Minagawa, H., Yamamoto, N., Abe, H., Fukuda, M., Seki, N., Kikuchi, K., Kijima, H., and Itoi, E. (2013). Prevalence of symptomatic and asymptomatic rotator cuff tears in the general population: From mass-screening in one village. *J. Orthop.* 10, 8–12.
- Rutten, M.J.C.M., Jager, G.J., and Blickman, J.G. (2006). From the RSNA refresher courses: US of the rotator cuff: Pitfalls, limitations, and artifacts. *Radiographics* 26, 589–604.
- Xin Ooi, M.W., Fenning, L., Dhir, V., and Basu, S. (2021). Rotator cuff assessment on imaging.

J. Clin. Orthop. Trauma 18, 121–135.

- Zheng, F., Wang, H., Gong, H., Fan, H., Zhang, K., and Du, L. (2019). Role of ultrasound in the detection of rotator-cuff syndrome: An observational study. Med. Sci. Monit. 25, 5856–5863.

5.5.2 Elbow

Justification and clinical history

Common pathologies identified on ultrasound scanning include common extensor (tennis elbow)/flexor (golfers' elbow) tendinopathy, distal biceps tendinopathy/tears and olecranon bursitis. Joint effusion/synovitis may be detected but intra-articular pathology cannot be excluded.

More experienced practitioners may evaluate collateral ligaments for tears following injury and the course/appearances of the ulnar nerve if symptomatic.

Structures to examine and evaluate

- Common extensor tendon
- Common flexor tendon
- Distal biceps tendon
- Olecranon bursa
- Anterior and posterior joint recesses
- Cubital tunnel for ulnar nerve enlargement/flattening/subluxation

Dynamic assessment using ultrasound may be requested for the following, but depends on the skill and expertise of the ultrasound practitioner:

- ?Ulnar nerve subluxation

Technique

Numerous scan protocols for the elbow are described in the literature, including the ESSR guidelines [Musculoskeletal ultrasound technical guidelines II. Elbow](#) and Draghi *et al.*, (2007), [Ultrasound of the elbow: Examination techniques and US appearance of the normal and pathologic joint](#).

The patient is often seated for examination of the elbow, but in some cases it may be easier to scan with the patient supine.



See additional resources at:

- 19_03 - [Musculoskeletal Ultrasound: Elbow](#)

5.5.2.1 Elbow ultrasound reporting examples

Referral for restricted movement of the elbow

Clinical details: *Restricted movement of the left elbow with a normal x-ray, sometimes describes nerve pain.*

Ultrasound of the left elbow performed with verbal consent. Chaperone XX present:

Normal appearances of the common extensor/flexor/distal biceps tendons of the left elbow. No evidence of tendinopathy, tears or calcification.

No evidence of joint effusion or synovitis but ultrasound cannot exclude intra-articular pathology.

The ulnar nerve appears normal in calibre around the elbow and is stable within the cubital tunnel on dynamic scanning. No solid or cystic lesions seen in the cubital tunnel.

Conclusion:

Normal examination. No cause for symptoms seen.

Referral for tenderness of the elbow

Clinical details: tender over CEO ?tendinopathy.

Ultrasound of the left elbow performed with verbal consent. Chaperone XX present:

There is a 6mm non-shadowing hyperechoic deposit within the left XX tendon. The patient is tender in this area on sonopalpation. There is no evidence of an associated tear. The remaining tendons of the left elbow appear normal.

Conclusion:

There is a 6mm non-shadowing deposit within the left XX tendon, likely to be soft calcific tendinopathy.

Referral for possible olecranon bursitis

Clinical details: Swelling over olecranon ?bursitis.

Ultrasound of the right elbow performed with verbal consent. Chaperone XX present:

The olecranon bursa contains an effusion and the wall is hyperaemic on application of power Doppler. The patient is tender on sonopalpation in this region. Appearances are consistent with olecranon bursitis.

Conclusion:

Right olecranon bursitis.

Further information can be found at:

- De Maeseneer, M., Brigido, M.K., Antic, M., Lenchik, L., Milants, A., Vereecke, E., Jager, T., and Shahabpour, M. (2015). Ultrasound of the elbow with emphasis on detailed assessment of ligaments, tendons, and nerves. *Eur. J. Radiol.* 84, 671–681.
- Draghi, F., Danesino, G.M., de Gautard, R., and Bianchi, S. (2007). Ultrasound of the elbow: Examination techniques and US appearance of the normal and pathologic joint. *J. Ultrasound* 10, 76–84.
- Draghi, F., Gregoli, B., and Sileo, C. (2012). Sonography of the bicipitoradial bursa. A short pictorial essay. *J. Ultrasound* 15, 39–41.
- Konin, G.P., Nazarian, L.N., and Walz, D.M. (2013). US of the elbow: Indications, technique, normal anatomy and pathologic conditions. *Radiographics* 33, E125–E147.
- Omoumi, P., Gondim Teixeira, P.A., Ward, S.R., Trudell, D., and Resnick, D. (2021). Practical ultrasonographic technique to precisely identify and differentiate tendons and ligaments of the elbow at the level of the humeral epicondyles: anatomical study. *Skeletal Radiol.* 50,

1369–1377.

- Pierce, J.L., and Nacey, N.C. (2016). Elbow Ultrasound. *Curr. Radiol. Rep.* 4, 1–11.

5.5.3 *Hand and wrist*

Justification and clinical history

Common pathologies identified on ultrasound scanning include flexor/extensor tendinopathy, tenosynovitis, tears, pulley disruption and joint synovitis/effusion. Ultrasound can also be used to assess the nature and origin of swellings and the median nerve in the carpal tunnel for enlargement, oedema and/or compression.

More experienced practitioners may evaluate ligaments around the hand/wrist, although for intra-articular and ligament pathologies, other cross-sectional imaging such as MRI may be more appropriate.

Structures to examine and evaluate

- Extensor and flexor tendons
- Joints of the hand/wrist and metacarpophalangeal (MCP), proximal interphalangeal (PIP), distal interphalangeal (DIP) and carpometacarpal (CMC) joints
- Ligaments of the thumb/finger joints
- Carpal tunnel
- Guyon's canal (ulnar tunnel) for causes of nerve compression
- Tendons and sheaths – LS with colour box to show the absence of neovascularity
- Tendons in LS and TS, distal tendon insertion in LS to exclude tear/tendinopathy/tenosynovitis/calcification
- Dorsal and volar wrist joints with and without Doppler/colour box to show the absence of effusion or synovitis
- Finger ligaments in LS, in stressed and relaxed positions if appropriate

Technique

Numerous scan protocols for the hand and wrist are described in the literature, including the ESSR Guidelines [Musculoskeletal ultrasound technical guidelines III. Wrist](#) and McNally (2008), [Ultrasound of the small joints of the hands and feet: current status](#).

Diagnostic scanning of the hand/wrist is usually focused to a single area or pathology, such as the dorsum of the wrist for 'ganglion' or the joints of the hand and wrist for 'synovitis'. Other structures may be included if appropriate and symptomatic and within the clinical experience of the ultrasound practitioner.

The ultrasound practitioner may have a preference for patient positioning for the ultrasound examination of the hands and wrists, which is likely to be sitting on a chair with the hand extended onto the table. Where equipment allows, consideration could be given to positioning the patient sitting on the ultrasound examination couch with the back support upright and the patient's legs extended, with their hands on a pillow for support.

5.5.3.1 Hand and wrist ultrasound reporting examples

Referral for ultrasound of the hand and wrist. Sample report for normal appearances.

Clinical details: Pain in wrist, ?De Quervain's tenosynovitis.

Ultrasound of the right wrist/hand performed with verbal consent. Chaperone XX present:

Normal ultrasound appearances of compartment 1 of the extensor tendons. The extensor pollicis brevis and abductor pollicis longus tendons and their sheath appear normal. No evidence of De Quervain's tenosynovitis.

No evidence of MCP or IPJ synovitis.

Conclusion:

Normal appearances. No cause for patient's symptoms seen.

Referral for tendinopathy/tenosynovitis

Clinical details: Pain and swelling the right wrist, ?tendinopathy.

Ultrasound of the right wrist performed with verbal consent. Chaperone XX present:

The xx tendon(s) in compartment xx of the right wrist appear generally thickened with loss of the normal fibrillar pattern, consistent with tendinopathy. Application of Doppler reveals hyperaemia of the tendon sheath.

Conclusion:

Appearances are consistent with right tenosynovitis. No tear seen.

Referral for wrist lump

Clinical details: Lump in the left wrist.

Ultrasound of the wrist performed with verbal consent. Chaperone XX present:

The palpable lump in the dorsal aspect of the wrist corresponds to a Y x Ymm anechoic, well-circumscribed cystic structure which appears to be related to the underlying scapholunate ligament. No evidence of increased peripheral vascularity on Doppler application. Ultrasound appearances are in keeping with a ganglion cyst.

Conclusion:

Left ganglion cyst.

Further information can be found at:

- Boutry, N., Titécat, M., Demondion, X., Glaude, E., Fontaine, C., and Cotten, A. (2005). High-frequency ultrasonographic examination of the finger pulley system. *J. Ultrasound Med.* 24, 1333–1339.
- Chiavaras, M.M., Jacobson, J.A., Yablon, C.M., Brigido, M.K., and Girish, G. (2014). Pitfalls in Wrist and Hand Ultrasound. *Am. J. Roentgenol.* 203, 531–540.
- Van Holsbeeck, M., and Introcaso, J. (2015). *Musculoskeletal Ultrasound*, 3rd ed. (Jaypee Borthers Medical Publishers (P) Ltd).
- Lee, J.C., and Healy, J.C. (2005). Normal sonographic anatomy of the wrist and hand. *Radiographics* 25, 1577–1590.
- Lee, S.A., Kim, B.H., Kim, S.J., Kim, J.N., Park, S.Y., and Choi, K. (2016). Current status of ultrasonography of the finger. *Ultrasonography* 35, 110–123.
- Nacey, N.C., and Pierce, J.L. (2016). Ultrasound Imaging of the Hand and Wrist: Fundamentals and New Perspectives. *Curr. Radiol. Rep.* 4, 1–11.
- Olchow, C., Łasecki, M., and Zaleska-Dorobisz, U. (2015). Wrist ultrasound examination – scanning technique and ultrasound anatomy. Part 1: Dorsal wrist. *J. Ultrason.* 61, 172–188.
- Gitto, S., and Draghi, F. (2016). Normal sonographic anatomy of the wrist with emphasis on assessment of tendons, nerves, and ligaments. *J. Ultrasound Med.* 35, 1081–1094.

5.5.4 Adult hip

Justification and clinical history

Common pathologies identified on ultrasound scanning include joint effusion/synovitis, iliopsoas bursitis, gluteal/ischial tendinopathy/tears/bursitis, anterior/posterior, medial, lateral tendinopathy/tears.



Depending on the clinical details and clinical question posed, alternative imaging such as cross-sectional or plain film may have increased diagnostic value.

Structures to examine and evaluate

The following structures may be included, if appropriate and symptomatic, and within the clinical experience of the ultrasound practitioner:

- Anterior hip
 - Anterior joint recess
 - Iliopsoas tendon and bursa
 - Tensor fasciae latae (TFL) and sartorius
 - Femoral neurovascular bundle
 - Rectus femoris
- Medial hip
 - Adductor muscles and tendinous insertions

NOTE: This area of the hip is often best demonstrated on MRI

- Posterior and lateral hip
 - Abductors: gluteus minimus/medius and TFL
 - Gluteus maximus
 - Iliotibial band (ITB)
 - Trochanteric bursa (if visible)
 - Hamstring muscles and tendinous insertions

Careful evaluation of each area should be made, assessing for pathologies including tears, enthesopathy, tendinopathy, calcifications, bursae/bursitis, cysts and collections where appropriate.

See [section 5.2.9](#) for information about herniae.

Technique

Hip-scanning protocols are described in the literature, for example the ESSR guidelines [Musculoskeletal ultrasound technical guidelines IV. Hip](#).

Diagnostic scanning of the hip is usually focused to a single area or pathology, for example the anterior hip joint for possible effusion.

Comparison with the contralateral side (assuming it is asymptomatic) will help when determining the clinical significance of age-/activity-related changes and should be imaged and documented in the report.

The patient is most often in the supine position for examination of the hip structures. However, dynamic assessment may also be used in the standing position, for example when evaluating 'snapping hip syndrome'.

The medial hip is often best examined in external rotation. The lateral posterior hip is, however, best accessed from the decubitus position with the knee bent up towards the chest.

Both a high-frequency linear transducer and a 3.5MHz curved array transducer can be used in the examination of the hip, depending on the structure and pathology being evaluated.

It is often more dignified to ask the patient to change into a gown for this examination, or where the anterior hip is being examined, to provide a sheet or pillowcase to cover the patient as much as is reasonably practicable.

- 19_05 - [Musculoskeletal Ultrasound: Adult Hip](#)

5.5.4.1 Hip ultrasound reporting examples

Referral for hip pain

Clinical details: Pain around the greater trochanter on movement. Previously a long-distance fell walker.

Ultrasound of the left hip performed with verbal consent. Chaperone XX present:

Scanning directly over the patient's region of pain, the gluteus medius tendon appears generally thickened with loss of the normal fibrillar pattern consistent with tendinopathy. No evidence of intratendinous calcification. No tears seen. No evidence of a trochanteric bursal effusion.

Conclusion:

Left gluteus medius tendinopathy.

Referral for hip pain

Clinical details: Pain in hip, ?effusion.

Ultrasound of the right hip performed with verbal consent. Chaperone XX present:

There is an effusion in the anterior right hip joint capsule measuring Xmm in depth, compared to Xmm on the asymptomatic left side. The effusion does not appear to be complex, but infection/septic arthritis cannot be excluded.

Conclusion:

Right hip effusion.

Examples of suggested reports for normal scans

- No evidence of a joint effusion or synovitis seen arising from the anterior hip joint, although intra-articular pathology cannot be excluded with ultrasound.
- Normal appearances of the distal iliopsoas tendon with no evidence of bursitis.
- Normal appearances of the posterior hamstring origin at the ischial tuberosity.

Further information can be found at:

- Balias, R., Pedret, C., Iriarte, I., Sáiz, R., and Cerezal, L. (2019). Sonographic landmarks in hamstring muscles. *Skeletal Radiol.* 48, 1675–1683.
- Grassi, A., Quaglia, A., Canata, G.L., and Zaffagnini, S. (2016). An update on the grading of muscle injuries: A narrative review from clinical to comprehensive systems. *Joints* 4, 39–46.
- Lin, Y.T., and Wang, T.G. (2012). Ultrasonographic Examination of the Adult Hip. *J. Med. Ultrasound* 20, 201–209.
- Long, S.S., Surrey, D.E., and Nazarian, L.N. (2013). Sonography of greater trochanteric pain syndrome and the rarity of primary bursitis. *Am. J. Roentgenol.* 201, 1083–1086.
- Molini, L., Precerutti, M., Gervasio, A., Draghi, F., and Bianchi, S. (2011). Hip: Anatomy and US technique. *J. Ultrasound* 14, 99–108.
- Rowbotham, E.L., and Grainger, A.J. (2011). Ultrasound-Guided Intervention Around the Hip Joint. *Am. J. Roentgenol.* 197, W122–W127.

5.5.5 Knee

Justification and clinical history

Common pathologies identified on ultrasound scanning include joint effusion/synovitis, hamstring tendinopathy/tears, pes anserine bursitis, popliteal fossa/Baker's cyst, collateral ligament tears, and quadriceps/patellar tendinopathy/enthesopathy/tears.

Structures to examine and evaluate

Where appropriate and within the expertise of the ultrasound practitioner:

- Anterior knee assessment
 - Extensor mechanism
 - Bursae/effusions
 - Trochlea and femoral condyle cartilage
 - Joint recesses
- Medial knee assessment
 - Medial collateral ligament
 - Pes anserine complex and bursa
- Lateral knee assessment
 - Lateral collateral ligament
 - Tendon insertions including ITB
- Posterior knee assessment
 - Muscle group identification for assessment of ?Baker's cyst
 - Neurovascular structures

Technique

Knee-scanning protocols are described in the literature, for example the ESSR guidelines [Musculoskeletal ultrasound technical guidelines V. Knee](#).

Diagnostic scanning of the knee is usually focused to a single area or pathology, for example the popliteal fossa for ?Baker's cyst.

The patient may adopt various positions for scanning of the knee, depending on the pathology being assessed or the preference of the ultrasound practitioner. For example, if the patient is being assessed for a popliteal fossa structure, they may be scanned standing or prone. Anterior knee assessment is best achieved supine with the knee extended and slightly flexed with the support of a rolled-up blanket if required. Where the patient has difficulties, a decubitus position may also be employed.

Adapted technique and dynamic assessment may be employed, especially in cases of post-surgical intervention e.g. re-rupture of quadriceps tendon post-surgical repair.

Features such as panoramic/wide view are useful adjuncts to see the extent of knee pathologies.

5.5.5.1 Knee ultrasound reporting examples

Referral for Baker's cyst

Clinical details: Lump in left popliteal fossa, ?Baker's cyst.

Ultrasound of the left knee performed with verbal consent. Chaperone XX present:

There is a well-defined, simple cystic structure in the medial popliteal fossa measuring Xmm. It lies between the medial head of gastrocnemius and the semimembranosus tendon, measured at 5.6cm in maximum axial diameter. The site and appearances of this structure are consistent with a left Baker's cyst.

Conclusion:

Baker's cyst left knee.

Referral for quadriceps tendon rupture

Clinical details: Fall downstairs, unable to straight leg raise. Gap palpated in the right quadriceps tendon, ?complete rupture.

Ultrasound of the left knee performed with verbal consent. Chaperone XX present:

There is a complete tear of the left quadriceps tendon at its insertion onto the superior pole of the patellar. With the knee joint extended, the tendon has retracted proximally by Xmm. The patellar tendon is intact.

Conclusion:

Complete tear of the left quadriceps tendon.

Referral for knee pain

Clinical details: Fall. Pain and weakness on leg raise, ?tendon tear right knee.

Ultrasound of the right knee performed with verbal consent. Chaperone XX present:

Normal appearances of the right quadriceps and patellar tendons. Normal fibrillar pattern. No evidence of tendon tears, calcification or enthesitis.

Conclusion:

No cause found for symptoms demonstrated. Intra-articular pathology cannot be excluded.

Further information can be found at:

- Alves, T.I., Girish, G., Brigido, M.K., and Jacobson, J.A. (2016). US of the knee: Scanning techniques, pitfalls, and pathologic conditions. *Radiographics* 36, 1759–1775.
- Paczesny, Ł., and Kruczyński, J. (2011). Ultrasound of the Knee. *Semin. Ultrasound, CT MRI* 32, 114–124.
- Reinking, M.F. (2016). Current concepts in the treatment of patellar tendinopathy. *Int. J. Sports Phys. Ther.* 11, 854–866.
- Roberts, H.M., Moore, J.P., and Thom, J.M. (2019). The Reliability of Suprapatellar

Transverse Sonographic Assessment of Femoral Trochlear Cartilage Thickness in Healthy Adults. *J. Ultrasound Med.* 38, 935–946.

- Ward, E.E., Jacobson, J.A., Fessell, D.P., Hayes, C.W., and Van Holsbeeck, M. (2001). Sonographic detection of Baker's cysts: Comparison with MR imaging. *Am. J. Roentgenol.* 176, 373–380.

5.5.6 Foot and ankle

Justification and clinical history

Common pathologies identified on ultrasound scanning include interdigital spaces for Morton's neuroma/bursal complex, plantar fascia for fasciopathy/fasciitis, tendons for tendinopathy, enthesitis, enthesopathy, tears, calcification, joint synovitis, ligaments of the ankle for sprains or tears and tarsal tunnel for nerve compression.

Structures to examine and evaluate

- Anterior ankle joint
- Anterior tendons: anterior tibial, extensor hallucis longus and extensor digitorum longus tendons
- Medial ankle: posterior tibial, flexor digitorum longus and flexor hallucis longus tendons and neurovascular bundle
- Lateral ankle tendons: peroneus brevis and longus
- Posterior ankle: Achilles tendon and insertion, retrocalcaneal and pre-Achilles bursa, plantar fascia
- Dorsal surface of tarsal joints
- Metatarsophalangeal (MTP) joints
- Interdigital spaces
- Some ligaments can be demonstrated using ultrasound including anterior talofibular, anterior tibiofibular, calcaneofibular, deltoid



Ankle ligaments are optimally examined in LS in stressed and relaxed positions, as appropriate.

Technique

Numerous scan protocols for the foot and ankle are described in the literature, for example the ESSR guidelines [Musculoskeletal ultrasound technical guidelines VI. Ankle](#).

Diagnostic scanning of the foot/ankle is usually focused to a single area or pathology, for example the interdigital spaces for 'Morton's neuroma'.

Patient positioning is entirely dependent on the structure being examined, for example prone or decubitus for Achilles evaluation, knee flexed/foot flat for the anterior ankle.



Image the tendons and sheaths/paratendon in LS with Doppler (preferably power or microvascular) in order to demonstrate the presence or absence of neovascularity.

5.5.6.1 Foot and ankle ultrasound reporting examples

Referral for ankle swelling

Clinical details: Swelling mid-Achilles, ?tendinopathy, ?partial tear.

Ultrasound of the left ankle performed with verbal consent. Chaperone XX present:

The palpable and visible swelling corresponds to a moderate fusiform thickening (AP diameter measured at 7mm) of the left Achilles tendon with loss of the normal fibrillar pattern and a moderate degree of neovascularity within the middle third of the tendon. Normal appearances of the proximal and distal tendon. No evidence of enthesitis or bursitis.

Conclusion:

Appearances are consistent with a moderate degree of non-insertional Achilles tendinopathy. No signs of tear identified.

Referral for Morton's neuroma

Clinical details: Burning pain left foot. Feels like a pebble under the ball of foot when walking.
?Morton's neuroma.

Ultrasound of the left foot performed with verbal consent. Chaperone XX present:

There is a well-defined hypoechoic, partially compressible lesion between the left 2nd and 3rd MT heads of the left foot. The lesion measures Y x Y x Ymm and there is no evidence of internal vascularity on application of Doppler. Appearances are consistent with a neuroma/bursal complex. No lesions seen in the remaining web spaces.

Conclusion:

Morton's neuroma/bursal complex between the 2nd and 3rd metatarsal head of the left foot.

Referral for trauma

Clinical details: Trauma playing football. Clinically ruptured right Achilles. Please confirm and assess prior to surgery.

Ultrasound of the right ankle performed with verbal consent. Chaperone XX present:

There is a complete rupture of the right Achilles tendon approximately 34mm proximal to the upper border of the calcaneum.

With the ankle in neutral position, there is retraction of the proximal stump leaving a gap of approximately 24mm between tendon ends. With the ankle plantarflexed and the foot in equinus position, the tendon ends do not oppose. There is herniation of Kager's fat pad in between the tendon ends and the gap is still 14mm. There is relatively normal fibrillar pattern of the distal stump of tendon, but the proximal stump appears severely tendinopathic.

Conclusion:

Complete tear of the right Achilles tendon. Tendon ends do not oppose in plantarflexion.

Further information can be found at:

- Alves, T., Dong, Q., Jacobson, J., Yablon, C., and Gandikota, G. (2019). Normal and Injured Ankle Ligaments on Ultrasonography With Magnetic Resonance Imaging Correlation. *J. Ultrasound Med.* 38, 513–528.
- Davda, K., Malhotra, K., O'Donnell, P., Singh, D., and Cullen, N. (2017). Peroneal tendon disorders. *EFORT Open Rev.* 2, 281–292.
- Del Buono, A., Chan, O., and Maffulli, N. (2013). Achilles tendon: Functional anatomy and novel emerging models of imaging classification. *Int. Orthop.* 37, 715–721.
- Draghi, F., Gitto, S., Bortolotto, C., Draghi, A.G., and Ori Belometti, G. (2017). Imaging of plantar fascia disorders: findings on plain radiography, ultrasound and magnetic resonance imaging. *Insights Imaging* 8, 69–78.
- Gregg, J., Silberstein, M., Schneider, T., and Marks, P. (2006). Sonographic and MRI evaluation of the plantar plate: A prospective study. *Eur. Radiol.* 16, 2661–2669.
- Inthasan, C., and Mahakkanukrauh, P. (2019). Tarsal tunnel syndrome: Anatomical facts and clinical implications. *J. Anat. Soc. India* 68, 236.
- Lee, S., Oliveira, I., Li, Y., Welck, M., and Saifuddin, A. (2019). Fluid around the distal tibialis posterior tendon on ankle MRI: Prevalence and clinical relevance. *Br. J. Radiol.* 92.
- Li, H.Y., and Hua, Y.H. (2016). Achilles Tendinopathy: Current Concepts about the Basic Science and Clinical Treatments. *Biomed Res. Int.* 2016.
- McNally, E.G. (2008). Ultrasound of the small joints of the hands and feet: Current status. *Skeletal Radiol.* 37, 99–113.
- Park, J.W., Lee, S.J., Choo, H.J., Kim, S.K., Gwak, H.C., and Lee, S.M. (2017). Ultrasonography of the ankle joint. *Ultrasonography.* 36, 321–335.
- Santiago, F.R., Muñoz, P.T., Pryest, P., Martínez, A.M., and Olleta, N.P. (2018). Role of imaging methods in diagnosis and treatment of Morton's neuroma. *World J. Radiol.* 10, 91–99.
- Shalaby, M.H., Sharara, S.M., and Abdelbary, M.H. (2017). High resolution ultrasonography in ankle joint pain: Where does it stand? *Egypt. J. Radiol. Nucl. Med.* 48, 645–652.

5.6 Rheumatology ultrasound examinations

These guidelines are aimed at those ultrasound practitioners scanning patients with suspected or confirmed inflammatory arthritis who are not directly involved in a rheumatology service, for example sonographers and radiologists scanning within radiology departments. Rheumatologists often have their own protocols and guidelines when scanning their patients.

General scanning principles

The advantages of diagnostic ultrasound for rheumatology patients have been increasingly recognised over the last 20 years. These include detailed, real-time, dynamic assessment of joints and soft tissues and the use of Doppler sonography which can accurately assess the degree of activity in inflammatory disease. This has allowed clinicians to diagnose and manage many inflammatory diseases more accurately.

The pitfalls of ultrasound interpretation are widely documented, and some will be highlighted within this text.

Age-related changes are common in the musculoskeletal system and may not be the current cause of patient's symptoms. Therefore, ultrasound appearances must always be taken in the clinical context and the referrer should be made aware of any limitations in the report. Some structural change may or may not be associated with pain, and an indication of the site of current symptoms on a report may also help.



Comparison with the contralateral side (assuming it is asymptomatic) will help when determining the clinical significance of age-/activity-related changes and should be imaged and documented in the report.

Justification and clinical history

Common indications for the performance of a rheumatology ultrasound scan are:

- Joint pain and swelling. Is there any evidence of inflammatory arthritis?
- Rheumatoid arthritis (RA) on disease-modifying anti-rheumatic drugs: 'active synovitis'.
- RA in remission. Is there any evidence of subclinical synovitis?

The diagnosis of any disease is a combination of clinical history, blood tests and imaging. Referrers must be strongly encouraged to provide as much information on the ultrasound request/referral as possible.

Blood tests can help to establish the diagnosis of RA. Rheumatoid factor (RF) is recommended by [NICE \(2018, updated 2020\)](#). Anti-cyclic citrullinated peptide (anti-CCP) antibody testing can also be used if the RF is negative in those exhibiting symptoms of RA ([NICE, 2018](#), updated 2020). A positive RF or anti-CCP test does not mean that the patient categorically has RA, but can be helpful. Other features must be present, such as pain and swelling in the joints, morning stiffness in the joints for longer than 45 minutes, or involvement of many joints.

Other blood tests often used prior to diagnosis include ESR and CRP, which measure the amount of inflammation in the blood ([Orr et al., 2018](#)). As a guide, CRP greater than 5mg/L and ESR greater than 12mm/h would be considered abnormal, although laboratories may have slightly different thresholds. In some inflammatory arthritides, blood tests may be relatively normal, especially in spondyloarthropathies such as psoriatic arthritis. Ultrasound scanning in these cases can be particularly useful to clinicians.

Technique

Good scanning technique is vital in accurately assessing joints and soft tissues for evidence of inflammatory disease. Of particular importance is minimising transducer pressure on the skin surface, as too much pressure may compress small blood vessels and obliterate Doppler signal that may be present in active disease.

Rheumatology patients can often experience debilitating pain and discomfort when asked to stay in some positions during scanning. Consideration should be given to this and thought given to how the patient is positioned for the scan.

Wrist

- Begin at the wrist crease. Scan the dorsal wrist/carpal bones in LS from the medial to the lateral border and in TS, to cover the joints.
- Scan the extensor tendons in TS from the musculotendinous junction to the distal insertion and then in LS. If necessary, compare with the contralateral side.
- Scan the volar wrist/carpal joint in LS from the medial to the lateral border and in TS, to cover the joints. If necessary, compare with the contralateral side.
- Scan the flexor tendons in TS from the musculotendinous junction to the distal insertion and then in LS. If necessary, compare with the contralateral side.
- Repeat each section using power/colour Doppler imaging.

Dorsal MCP and PIP joints

- Begin in LS over the relevant joint.
- Scan the joint in LS from the medial to the lateral border and in TS, to cover the joint.
- Repeat each section using power/colour Doppler imaging.

A standard hand and wrist series should include the following minimum images for a normal rheumatology scan:

- Dorsal wrist and carpal joints in LS with and without Doppler image
- Extensor carpi ulnaris (ECU) tendon with and without Doppler image
- All MCP joints in LS with and without Doppler image
- All PIP joints in LS with and without Doppler image
- Flexor tendons with and without Doppler image

Pathology should be demonstrated and imaged in two planes.

Foot and ankle

- Begin at the anterior ankle joint. Scan the dorsal tibiotalar joint in LS from the medial to the lateral border and in TS, to cover the joint.
- Scan the anterior, medial and lateral ankle tendons in TS from the musculotendinous junction to the distal insertion and then in LS.
- Scan the dorsal MTP joints in LS from the medial to the lateral border and in TS, to cover the joint.
- Scan the plantar surface of the MTP joints in LS from the medial to the lateral border looking for erosions.
- Repeat each section using power Doppler imaging.

A standard foot/ankle series should include the following minimum images for a normal rheumatology scan:

- Dorsal ankle joint in LS with and without Doppler image
- Medial tendons with and without Doppler image
- Lateral tendons with and without Doppler image
- All MTP joints in LS with and without Doppler image

Equipment settings

As Doppler is used frequently to detect the presence of active inflammation, it is vital that the ultrasound system used is sensitive to detect low flow. Important settings include a low pulse repetition frequency, appropriate gain settings and a low level of wall filter.

Steroid and non-steroidal anti-inflammatory drug (NSAID) use

Steroids, including oral, intramuscular or infusion for the treatment of either joint disease or concurrent problems such as asthma, bronchiectasis and chronic obstructive pulmonary disease, will

temporarily reduce inflammation and hyperaemia. There is some evidence that NSAIDs have a similar effect ([Zayat et al., 2011](#)).

Steroids will affect the level of Doppler signal and may even remove ultrasound features of inflammatory arthritis such as hyperaemia, soft tissue thickening and effusion. It is therefore suggested that ultrasound examinations should be scheduled at least 6 weeks after any steroid intervention. If that is not possible, the ultrasound practitioner should add a comment in the report to ensure that the referrer is aware.

The use of NSAIDs prior to a scan may be more difficult to manage as they are widely used and required for pain relief. It may not be practical to limit their use, but the ultrasound practitioner should know if they are being taken. In these cases, areas of synovial proliferation with no Doppler signal and no obvious cause should be taken into consideration when reporting and may require rescans.

Structures to examine and evaluate

Hand and wrist

The structures that should be identified as a minimum in a hand/wrist ultrasound scan for rheumatology are:

- Wrist/carpal joints in LS and TS to interrogate the joints and overlying extensor tendons
- ECU tendon in LS and TS
- All dorsal MCP joints in LS and TS
- All dorsal PIP joints in LS and TS
- Flexor tendons in LS and TS



Small joints can be difficult to scan due to the angle of joints and tendons. A hockey stick transducer may be useful in these cases.

Foot and ankle

The structures that should be identified as a minimum in a foot/ankle ultrasound scan for rheumatology are:

- Tibiotalar joint in LS and TS to interrogate the joint
- Extensor tendons which include anterior tibial, extensor hallucis longus and extensor digitorum longus scan in LS and TS
- Medial and lateral ankle tendons which include posterior tibial, flexor digitorum longus and flexor hallucis longus tendons medially and peroneus longus and brevis laterally in LS and TS
- All dorsal MTP joints in LS, and if suspected pathology, confirm in TS if possible
- Metatarsal heads on the plantar surface looking for erosions which may be difficult to detect on the dorsal surface
- Flexor tendons evaluated in LS and TS



If querying seronegative inflammatory arthritis such as psoriatic arthritis, it may be useful to include the Achilles and plantar fascia insertions.

Anatomy should be interrogated for:

- **Joints:** synovial hypertrophy, active synovitis (using colour/power Doppler), effusion, bone erosions or degenerative change.
- **Tendons:** Tenosynovitis, effusion, tendon discontinuity/tears.

5.6.1 Common clinical scenarios

Effusion: A joint effusion is a collection of fluid within a joint or tendon sheath. It is typically anechoic and compressible, and does not display any internal Doppler signal. Small effusions are commonly seen in normal joints but if they become large, or are associated with other inflammatory appearances, they may be a sign of acute disease ([Wang et al., 2018](#)).

Synovial hypertrophy: Synovial proliferation and resulting hypertrophy is the primary event in RA that is visible on imaging.

A recognised definition of synovial hypertrophy on ultrasound is:

Abnormal hypoechoic (relative to subdermal fat, but sometimes may be isoechoic or hyperechoic) intra-articular tissue that is non-displaceable and poorly compressible ([Wakefield et al., 2005](#)).



The significance of the presence of synovial hypertrophy in joints without internal vascularity on Doppler is uncertain as it may be present in both inflammatory and non-inflammatory arthritis.

Active synovitis: Increased Doppler flow within the synovium is a recognised sign of active synovitis ([Rubin et al., 2019](#)). However, if the patient is currently undergoing treatment, in particular with steroids, the Doppler signal may be reduced or absent, so it is important to question patients about treatments and record this on the report as appropriate.

The recognised definition of synovitis on ultrasound is:

Synovial hypertrophy which may exhibit Doppler signal ([Wakefield et al., 2005](#)).

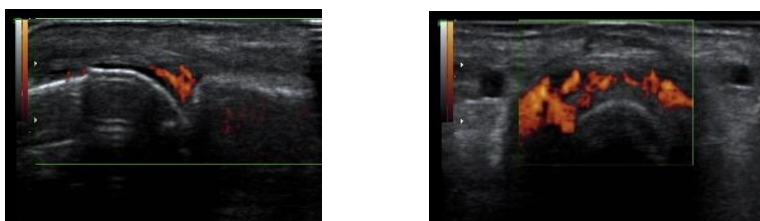


Figure 11: Active synovitis in an MCP joint

Any pathology found should be imaged in two planes. If a Doppler signal is seen within a joint in the LS, its site must be confirmed within the joint in the TS.



The degree of synovial hypertrophy and vascularity within joints or tendons may be estimated and documented either using an agreed grading system or 'mild/moderate/severe'. There are several grading systems for the degree of vascularity/grade of active synovitis – the most commonly used grades both synovial hypertrophy and active synovitis ([Hammer et al., 2011](#)). In non-research services, it may not be necessary to grade synovial hypertrophy as it is the amount of colour or power Doppler that is most reliable when determining inflammatory activity, so discussion with the particular rheumatology department is suggested.

Tenosynovitis: Tenosynovitis is inflammation of the synovial lining of the sheath that surrounds a tendon. Causes of tenosynovitis include infection, overuse or injury, but tenosynovitis can also be associated with some kinds of inflammatory arthritis.

In the normal state, the sheath of the tendon can barely be detected and is seen as a thin, hypoechoic band around the tendon. When inflamed, the sheath becomes increasingly hypoechoic and thickened, and may display internal vascularity with Doppler.

The recognised definition of tenosynovitis on ultrasound is:

Hypoechoic or anechoic thickened tissue with or without fluid within the tendon sheath, which is seen in two perpendicular planes and which may exhibit a Doppler signal ([Wakefield et al., 2005](#)).

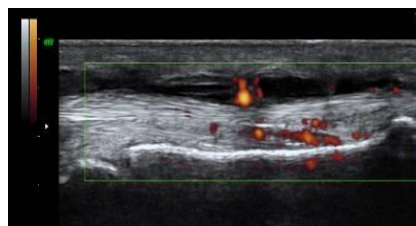
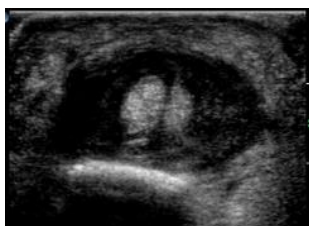

Figure 12: Tenosynovitis in a flexor tendon of the hand



Not all tendons are surrounded by a sheath and the ultrasound appearances of inflammation vary, for example the extensor tendons of the fingers, at the level of the MCP joints. Inflamed tendons without sheaths may have more diffuse peripheral oedema because inflammatory fluid is not contained. Instead of 'tenosynovitis', a description of this may be 'paratenonitis' or 'paratendinitis' ([Kaeley et al., 2020](#)).

Erosions: RA is characterised by a chronic inflammatory process that targets the synovial lining of some joints. As the disease advances, there is evidence of progressive destruction of the structural components of the joints which targets the articular cartilage and bone at the joint margins.

The recognised definition of an erosion on ultrasound is:

An intra-articular discontinuity of the bone surface that is visible in two perpendicular planes ([Wakefield et al., 2005](#)).

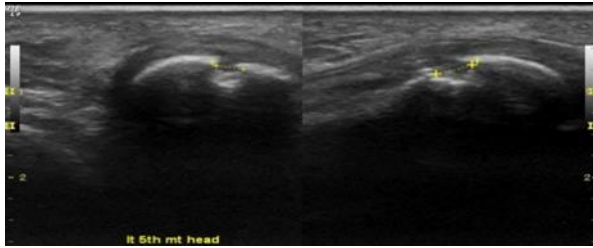


Figure 13: Erosion on metacarpal head

The aim of modern treatments is to halt soft tissue inflammation and prevent or arrest the development of adjacent bone erosions and joint damage. Historically, radiographs have been used to detect and monitor erosions, but ultrasound is now shown to detect them earlier ([Brown *et al.*, 2008](#)). However, there are areas of most joints that are difficult to access with the transducer, making erosions difficult to exclude.



Research studies suggest that detection of flow within erosions on Doppler is suggestive of active bone destruction and should be highlighted to the referrer ([Hau *et al.*, 1999](#)).

Inflammatory arthritides: The most common form of arthritis is osteoarthritis (OA), but these guidelines are specific to a group of inflammatory polyarthritides, including RA and spondyloarthropathies such as psoriatic arthritis (PsA). In these disorders, immune system dysfunction leads to inflammation within the synovial membrane of joints, tendon sheaths or bursae causing joint pain, stiffness and swelling and eventually bony damage.

Rheumatoid arthritis (RA): RA is the most common inflammatory arthritis, affecting approximately 400,000 people in the UK. RA commonly causes a symmetrical arthritis of the small joints, typically affecting wrists and MCP joints.

Spondyloarthropathies: Spondyloarthropathy is the term for a group of inflammatory arthritides that affect both the joints and tendons ([Kataria *et al.*, 2004](#)). This can predominantly affect the axial skeleton, back and pelvis, or the peripheral joints. Peripheral spondyloarthropathies include PsA.

Crystal arthropathies: Crystal arthropathies are caused by deposits of crystals within joints or soft tissues causing acute attacks of pain, redness and swelling. The two most common crystal arthropathies are gout and calcium pyrophosphate deposition (pseudogout). Gout predominantly affects the first MTP joints, knees, feet and elbows following deposits of urate crystals which sit on the surface of cartilage and produce a 'double contour sign' on ultrasound ([Checa *et al.*, 2019](#)).

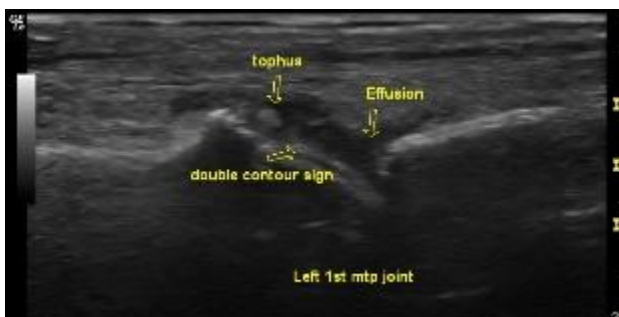

Figure 14: 'Double contour' sign on the left 1st metatarsal head

Pseudogout predominantly affects knees, wrists and ankles following deposits of calcium pyrophosphate crystals within cartilage.

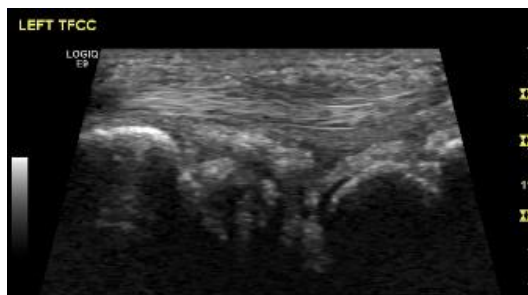


Figure 15: 'Pseudogout' or calcium pyrophosphate dihydrate deposition disease in the triangular fibrocartilage complex of the left wrist

Aspiration of synovial fluid from a symptomatic joint can help detect crystals and distinguish between the type of crystal arthropathy.

Extending the examination

Some medications used to treat inflammatory arthritis may affect liver function, and patients are frequently screened for derangement of LBTs. To exclude other causes of abnormal LBTs, such as malignancy, some centres will require an ultrasound scan of the liver as a baseline when starting patients on these drugs.

Giant cell arteritis

BMUS has published [giant cell arteritis \(GCA\)](#) guidance. The document is intended as a reference for departments or practitioners starting a GCA service in conjunction with rheumatology colleagues. It is not a training document and does not replace formal training in this area, but will act as a guide for new service development. Further information can also be found in the CSVS document [Vascular Technology Professional Performance Guidelines: Giant Cell Arteritis Duplex Ultrasound Examination](#).

5.6.2 Rheumatology ultrasound reporting examples

Normal study

Referral for hands and wrists

Clinical details: Swollen painful hands and wrists. ?Active synovitis.

Ultrasound of the hands and wrists performed with verbal consent.

No evidence of significant synovial hypertrophy or active synovitis seen in the joints of the hands and wrists. No tenosynovitis. No bony erosions seen.

Conclusion:

Normal study.

Referral for symptoms following recent intramuscular (IM) steroid injection

Clinical details: Persistent painful swollen wrists post-IM steroid injection.

Ultrasound of the hands and wrists performed with verbal consent.

There is synovial hypertrophy arising from the dorsal surfaces of both wrists but no evidence of internal Doppler signal. The patient reports an intramuscular injection of Methylprednisolone 2 weeks ago. This will reduce Doppler signal and may mask the ultrasound appearances of active synovitis. If symptoms return after 4–6 weeks and there is ongoing suspicion of inflammatory arthritis, a rescan is suggested before any further steroids are given.

Referral for assessment of activity in a symptomatic new patient or in a patient having treatment for RA

Suggested wording for the different grades of synovitis:

- There is moderately (grade 2) active synovitis arising from the right radiocarpal joint and within the right index, middle and ring finger MCP joints.
- There is mildly (grade 1) active synovitis in the right thumb MCP and little finger PIP joints.
- There is evidence of tenosynovitis of the right ECU tendon.

5.7 Obstetric ultrasound examinations

[2021]

General scanning principles

Person-centred care is at the heart of all ultrasound examinations. Obstetric ultrasound is no different, and should be performed only if there is potential benefit for the baby and parents. Regarding acoustic output and safety, scan times should be kept to a minimum. Ultrasound scans in pregnancy should only be performed by those professionals who have appropriate training, knowledge, skills and competence to deliver safe care. The SoR document [Competencies for ultrasound practice in private baby scan clinics](#) provides details of the minimum competencies required for the provision of baby scan services.

[2023, updated 2025]

Consent is essential for any examination, and in light of the [Mordel v Royal Berkshire legal case](#) in 2019, care must be taken to ensure that women/people fully understand the nature of any screening examinations and the implications of not having a screening test ([ref: section 2.5](#)).

Communication of ultrasound findings should be sensitive to the needs of the parents and their history, views, values and beliefs. All discussions should be non-judgemental and non-discriminatory.



The term women/woman has been used within this section, but it is important to remember that trans men and non-binary people can be pregnant and should be afforded the same standard of care as any other pregnant person. Where the document says 'women', it refers to women and pregnant people.

The [UK consensus guidelines and the ASCKS framework](#) for delivering unexpected news in obstetric ultrasound provide advice and support for ultrasound practitioners to communicate findings in a way that best supports values-based health and person-centred care.

ASCKS Framework
Avoid assumptions
Set up the scan
Clear, honest information
Kindness
Self-care

The 2023 independent [Pregnancy loss review](#) strongly recommends: **[2023]**

- “Staff should receive education relating to the need for sensitive, parent-centred care and encouraged to be ‘patient-led’ in their terminology.
- Training in bereavement care and delivering unexpected findings and difficult news should be mandated for all staff involved in providing these services.
- Consensus Guidelines on the Communication of Unexpected News via Ultrasound should be included within the curricula for sonography courses.
- Training should include “education on the importance of psychological well-being and self-care for staff”. Protected time for training and compliance monitoring should be incorporated into job plans.
- Translation services should be used when delivering unexpected news, as reflected in best practice guidance. Ideally face-to-face professional interpreters but where this is not possible video or telephone interpretation can be used.
- Early pregnancy assessment unit (EPAU) appointment times should be appropriately funded and sufficient to provide high quality care and communication to support parents’ physical and emotional needs.
- “Reflective supervision” and peer support are recommended to provide staff with the support they need to debrief and meet their emotional needs.
- The need for employers to recognise and support staff who have been impacted personally by baby loss, particularly when they return to working in an environment where baby loss is common, such as EPAU settings.” ([SoR](#), 2023)

The SoR document (2023) [Guidance and recommendations for running an effective, high-quality obstetric ultrasound service and supporting obstetric sonographer career development](#) provides additional advice and suggestions . **[2023]**

5.7.1 Early pregnancy ultrasound

Justification and clinical history

Early pregnancy scans are usually performed in a dedicated early pregnancy assessment unit (EPAU), to provide multidisciplinary support from diagnosis to management and aftercare ([NICE CG126](#)). Common indications for ultrasound include a positive pregnancy test and one or more of the following:

- Vaginal bleeding
- Pelvic or lower abdominal pain

- Previous history of ectopic or molar pregnancy
- Previous history of recurrent miscarriage (>3)

It can be helpful to know the approximate gestational age by LMP before starting to scan and finding out what symptoms have been experienced. This can help with communication later.

Technique

TV scans are usually offered in the EPAU setting if consent is given. The SoR (2023) [Intimate examinations and chaperone policy](#) should be considered.

Following a survey scan of the pelvis, in order to determine uterine position, to check whether there is an intrauterine pregnancy and to assess the adnexae for large masses or free fluid, a more detailed assessment is made. This should include the uterus and contents, the ovaries and adnexae. If an intrauterine pregnancy is present, the sac, embryo and surrounding area is assessed in detail and measurements taken, before discussing the findings.

Structures to examine and evaluate

TABLE 11: Structures to examine in early pregnancy

Structures	Evaluation
Uterus	<ul style="list-style-type: none"> • Shape, size, outline and echotexture • Position, e.g. anteverted, retroverted, retroflexed
Endometrial cavity	<ul style="list-style-type: none"> • Appearance of the endometrium and endometrial thickness measurement (if empty) • Presence or absence of gestation sac or intracavitary fluid collection • Location of sac within the endometrial cavity (if present), e.g. centrally located or eccentrically within the endometrium
Gestation sac (if present)	<ul style="list-style-type: none"> • Shape, size, outline and echotexture • Presence of regular trophoblastic rim, or irregular, absent trophoblastic rim around the sac • Sac contents • Presence of yolk sac. If looks enlarged, measure. Yolk sac measurements between 2mm and 6mm are suggested to have improved pregnancy outcomes(Bae and Karnitis., 2011; (Tan et al., 2012)) • Mean sac diameter (if no embryo) • Assess around the sac for presence or absence of haematoma
Embryo (if present)	<ul style="list-style-type: none"> • Number of embryos (if multiple, determine number and chorionicity/amnionicity, depending on gestational age) • Embryonic heart pulsations present or absent • Measure crown rump length (CRL) • If >10 weeks, assess fetal structures where possible (if this is within the practitioner's scope of practice)
Ovaries	<ul style="list-style-type: none"> • Shape, size, outline and echotexture of ovaries • Presence of corpus luteum or corpus luteal cyst • Check for ovarian masses. If present, measure in three planes
Adnexal regions	<ul style="list-style-type: none"> • Check for adnexal masses. If present, carefully assess, measure in three planes and look for trophoblastic rim or internal echoes that might suggest ectopic pregnancy
Rectouterine pouch	<ul style="list-style-type: none"> • Assess for presence or absence of free fluid. Measure if present and assess echotexture, e.g. anechoic or containing internal echoes

Normal appearances

The normal uterus should be homogeneous mid-grey appearance, with a smooth outline. The endometrium is likely to be thickened in the presence of an intrauterine pregnancy (>16mm) ([Tsuda et al., 2018](#)). The thickness should be measured and reported if there is no evidence of an intrauterine gestation sac.

A normal intrauterine gestation sac is round and well-circumscribed, and has a complete trophoblastic rim. It is usually eccentrically placed within the endometrial cavity, rather than central.

The yolk sac is first visualised within a gestation sac. This is a circular structure measuring <5–6mm. Larger yolk sacs have been linked to an increased chance of miscarriage ([Detti et al., 2020](#)). If an early embryo is seen within the gestation sac, the CRL should be measured. Embryonic pulsations may be present and if so, an M-mode image demonstrating these pulsations should be obtained and stored. If there is no embryo within the gestation sac, the **mean gestation sac diameter** should be calculated and reported (See elfh [Obstetric Ultrasound: Normal First Trimester](#) for measurement image).

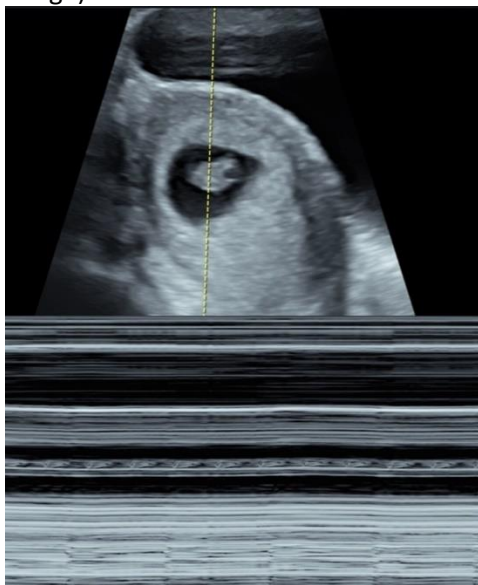

Figure 16: M-mode image showing the embryonic heart pulsations



The mean sac diameter must be calculated from three orthogonal measurements of the inner borders of the sac. Using only the largest diameter could lead to incorrect diagnosis of miscarriage and subsequent inappropriate management of the pregnancy.

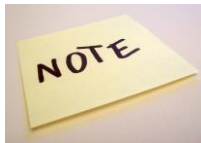Both ovaries should appear normal ([ref. section 5.1](#)). It is common to see a corpus luteal cyst in the first trimester of pregnancy. These have the appearance of a simple cyst, being anechoic with posterior acoustic enhancement. The walls are often hypervascular and show a peripheral 'ring of fire' appearance with colour Doppler. Internal echoes or wall thickening may be seen. The appearances should be reported, and follow-up checks undertaken at the next screening ultrasound examination. However, they usually resolve by about 14 weeks.

Table 12 shows the [NICE \(2019, updated 2023\)](#) recommendations in relation to assessment of 'viable intrauterine pregnancy' via transvaginal ultrasound (TVS) and transabdominal ultrasound (TAS) at the **first scan**.

TABLE 12: NICE guidance: Ultrasound appearances and management of viable intrauterine pregnancy with both TVS and TAS

Structure	Measurement	Management NICE (2019)
Empty intrauterine gestation sac	Mean sac diameter <25.0mm (TVS), no yolk sac or embryo present	<ul style="list-style-type: none"> • Rescan after a minimum of 7 days
	Mean sac diameter >25.0mm (TVS), no yolk sac or embryo present	<ul style="list-style-type: none"> • Second opinion and/or • Rescan after a minimum of 7 days
	No embryo present (TAS)	<ul style="list-style-type: none"> • Measure mean sac diameter • Rescan after a minimum of 14 days
Embryo	CRL <7.0mm, no cardiac activity (TVS)	<ul style="list-style-type: none"> • Rescan after a minimum of 7 days
	CRL >7.0mm, no cardiac activity (TVS)	<ul style="list-style-type: none"> • Second opinion and/or • Rescan after a minimum of 7 days
	No cardiac activity (TAS)	<ul style="list-style-type: none"> • Measure CRL • Rescan after a minimum of 14 days

NOTE: < = less than; > = more than



It is important to explain to parents before starting the scan that the scan may produce equivocal results that require a further scan in 7 to 14 days. This can make explanation of the findings and management much easier if a rescan is needed.

Abnormal appearances

In cases of vaginal bleeding in early pregnancy it is common to see a fluid collection outside the gestation sac. This represents a subchorionic haematoma, which should be measured and reported. Also note the location e.g. above, level or below the gestation sac.

Fibroids are often detected during early pregnancy scans ([ref. section 5.1](#)). It is usual practice to measure the largest fibroid and report the location, to assist with monitoring size throughout pregnancy. It is also important to note any fibroids that might obstruct the internal os and impact normal vaginal delivery. These should also be measured and reported.

Extending the examination

If large fibroids are detected, it may be prudent to scan the kidneys for hydronephrosis.

5.7.1.1 Common clinical scenarios

Intrauterine pregnancy of uncertain viability (IUPUV)

This is when an intrauterine pregnancy is seen, but there is no evidence of embryonic heart pulsations. [NICE guidelines \[NG126\] \(2019, updated 2023\)](#) must be followed, as highlighted in Table 12. If the embryo is present, but no heart pulsations are seen (CRL <7.0mm), this is classed as an IUPUV. Where there is no embryo present within the gestation sac, the mean sac diameter (MSD) must measure >25mm before making a diagnosis of miscarriage (see Table 12 and NICE, 2019).



Remember that a second opinion or a rescan in at least 7 days is required if this is the first scan.

Miscarriage

A miscarriage should not be diagnosed unless the NICE [\[NG126\]](#) guidelines have been followed. This may be an empty sac (MSD>25mm) or a sac containing an embryo (CRL>7.0mm) with no heart pulsations present.

Retained products of conception (RPOC) may be seen in a patient who continues to bleed after a miscarriage. There does not appear to be a consensus on the most accurate method of diagnosis for RPOC ([De Winter et al. 2017](#)). Much of the literature suggests that an endometrial thickness of <10mm is likely to be normal. When the endometrium measures >10mm and contains solid internal echoes with/without increased vascularity it may represent RPOC.

Pregnancy of unknown location (PUL)

This is the term used to report cases where there is no evidence of intra- or extrauterine pregnancy on TVS, in association with a positive pregnancy test. It could be too early to detect an intrauterine pregnancy, the patient could have had a miscarriage, or it might be an ectopic pregnancy.

Ectopic pregnancy

The most common location for an ectopic pregnancy is within the Fallopian tube. Appearances on ultrasound will vary, depending on factors such as gestational age and BMI. TVS is the gold standard for assessing the uterus, ovaries and adnexae.

Ultrasound findings may include:

- Uterine enlargement
- Thickened endometrium
- Possible centrally located fluid collection within the uterine cavity
- Adnexal mass, separate from/adjacent to the ovary
- Adnexal mass could be a solid mass, have a hyperechoic, hypervascular ring around a gestation sac, or contain a gestation sac with contents such as a yolk sac and/or embryo with/without cardiac activity

Ectopic pregnancies are also seen in other locations, including the ovary, cervix, abdominal cavity or interstitial part of the Fallopian tube ([Al-Memar et al., 2015](#)).

Caesarean section scar pregnancies are more frequently diagnosed, as Caesarean section rates increase. The [UK Early Pregnancy Surveillance Service \(UKEPSS\)](#) has been set up to study caesarean scar pregnancies. Ultrasound appearances of a caesarean scar pregnancy include empty uterine and cervical cavity, and gestation sac in the lower anterior uterine segment, at the site of a caesarean scar, with focal thinning of the myometrium anteriorly between the urinary bladder and the gestation sac. Absent sliding sign may also be helpful in differentiating a caesarean section scar pregnancy from a miscarriage.



Remember that an intrauterine pregnancy does not exclude an ectopic pregnancy. A coexisting ectopic pregnancy may be present (heterotopic pregnancy), particularly in women with a history of assisted reproductive techniques.

Hydatidiform mole (molar pregnancy)

There are two types of hydatidiform molar pregnancy: partial and complete. Histology is required to give a definitive diagnosis. Patients can present with hyperemesis and vaginal bleeding, among other symptoms ([RCOG, 2020](#)). The uterus is often enlarged, with a thickened heterogeneous endometrium, containing hyperechoic areas and small cystic spaces. Earlier in pregnancy (<8 weeks) there may just be a 'polypoid mass' within the endometrial cavity. In a partial molar pregnancy, an embryo may be visualised within a gestation sac. Placental tissue may appear thickened and contain cystic areas.

In cases of hydatidiform molar pregnancy, further assessment of the uterus may be required post-surgical removal of the molar tissue, to ensure full clearance, if heavy vaginal bleeding continues. [RCOG Green-Top Guideline No.38](#) has further information.

Early pregnancy management advice

Management advice will depend on the situation. Good communication with parents is essential and might include the need for a rescan, further investigations such as beta human chorionic gonadotrophin (β hCG) levels or referral to a gynaecology nurse or gynaecologist.

- Miscarriage and ectopic pregnancy should be managed in accordance with [NICE guidance \[NG126\], 2019, updated 2023](#).
- Molar pregnancy should be managed according to the [RCOG \(2020\) guidelines](#).
- Two serum β hCG levels may be required 48 hours apart, in cases of PUL, to determine whether rates are increasing more than 63% after two days (often normal ongoing pregnancy) or more slowly (may be a miscarriage or ectopic). It should be noted that if the β hCG level is >1,500 IU/l, an intrauterine pregnancy should be seen with TVS, if present. If no pregnancy is seen, the patient needs referral to a senior gynaecologist immediately ([NICE, 2019, updated 2023](#)).



If non-medical ultrasound practitioners are extending their role in the EPAU setting, to manage patient pathways, the governance for this new process needs to be appropriate, to ensure that the employer recognises and supports the service development and provides vicarious liability for the practitioner. All healthcare professionals involved must understand their legal and professional responsibilities for their own protection and safety of patients. This includes, but is not limited to:

- A scheme of work/written job plan to determine the scope of practice
- Agreed written protocols endorsed by senior management
- Full training and competency sign-off, along with evidence of ongoing CPD
- Governance and ongoing audit

The SoR and Association of Early Pregnancy Units guidance [A framework for advancing sonographer roles in early pregnancy](#) can be reviewed for further information and guidance. [2025]

5.7.2 First trimester screening

The [NHS FASP](#) in England, the [Pregnancy Screening Programme](#) in Scotland and [Antenatal Screening Wales](#) provide advice on the first trimester screening scan that is offered in all pregnancies.

The scan is performed between 11⁺² and 14⁺¹ weeks, when the CRL measures between 45mm and 84mm. The purpose of the scan is to determine the location of the pregnancy, the number of fetuses, chorionicity (if required) and gestational age (CRL measurement), to assess the fetus for major physical conditions such as acrania/exencephaly, and to check the uterus and adnexae for abnormalities such as fibroids or ovarian masses. The amount of amniotic fluid within the sac is also assessed subjectively.

For parents choosing to have screening for Down's and/or Edwards' and Patau's syndromes, the nuchal translucency (NT) is also measured as part of the combined screening test. This considers maternal factors along with the CRL measurement, NT measurement and blood test results for β hCG and pregnancy-associated plasma protein-A (PAPP-A). The results give a chance of the baby having one of the three syndromes. If the results show a higher chance ($>1:150$), parents can then make decisions about whether they want to undergo further diagnostic testing, after being provided with appropriate counselling and support. Non-invasive prenatal screening (NIPT) is offered to anyone with a chance result of greater than 1 in 150, which should reduce the need for invasive testing for many.

The RCOG, Royal College of Midwives and SCoR have produced a consensus statement, [Supporting women and their partners through prenatal screening for Down's syndrome, Edwards' syndrome and Patau's syndrome](#).

It is important to ensure that parents make informed decisions about the screening tests they opt into. In the case of the first trimester combined test, the optional nature of the screening and the advantages, limitations and consequences of having/not having the test must be explained. This should initially be discussed at the midwife booking appointment, but the ultrasound practitioner needs to be satisfied that this information has been understood, allowing time for questions and further discussion if needed.

5.7.3 Second trimester ultrasound

During the second trimester of pregnancy, a '20-week screening scan' should be offered between 18 and 20⁺⁶ weeks. Again, this is optional, and parents must be made aware of the purpose of screening and the advantages, limitations, and consequences of having/not having the examination. The current screening scan aims to detect 11 physical conditions ([NHS FASP, 2021](#)). It also enables measurement and plotting of fetal growth against the gestational age calculated from the first trimester scan and assessment of placental position and amniotic fluid level. If fibroids were detected at previous scans, the uterus can also be assessed to check for fibroid growth. The ovaries and adnexae should also be scanned and any previously identified ovarian masses measured, if still present.

The 11 physical conditions screened for are ([NHS FASP, 2021](#)):

- Anencephaly
- Spina bifida
- Cleft lip
- Congenital diaphragmatic hernia
- Congenital heart disease
- Exomphalos
- Gastroschisis
- Bilateral renal agenesis
- Lethal skeletal dysplasia
- Edwards' syndrome
- Patau's syndrome

During the second trimester scan, additional assessment of the placenta and cord insertion into the placenta can be undertaken, primarily to assess placental site in relation to the internal os, but also to look for signs of vasa praevia and placenta accreta spectrum. While this is not part of the NHS FASP, some centres will include it. Further details can be found in the RCOG [Green-top Guideline No.27a Placenta praevia and placenta accreta: Diagnosis and management \(2018\)](#) and [Green-top Guideline No.27b Vasa praevia: Diagnosis and management \(2018\)](#).



When assessing the placental location it is essential to see the leading edge of the placenta and the internal cervical os. Failure to see both clearly can lead to misdiagnosis of a high placental location rather than a placenta previa. [2025]

5.7.4 Third trimester ultrasound

[updated, 2023]

Third trimester scans are carried out for many reasons, including to assess growth, placental position and amniotic fluid, and to follow-up previously diagnosed anomalies. Third trimester scans must, however, always be clinically indicated or part of a recognised care pathway. There is still no evidence to support routine third trimester scanning.

To reduce perinatal mortality rates, various strategies have been implemented. The [Saving Babies' Lives Care Bundle Version 3](#) is one of these. Two of the five elements of care have an impact on ultrasound services. Element 2 aims to identify pregnancies at increased risk of fetal growth restriction (FGR), to improve outcomes. This includes initial assessment of risk factors at the booking

appointment, to prioritise those requiring uterine artery Doppler and serial ultrasound scans throughout pregnancy.

The objective of element 5 is to reduce preterm birth. TV cervical length measurement should be offered to those with a pregnancy assessed as high risk of preterm birth, including those with previous preterm birth or history of trachelectomy. It is important to be familiar with the technique and pitfalls of assessing the cervix and measuring the cervical length. There are several resources available to assist with this, these include:

- elfh module (see text box)
- ISUOG, [How to measure cervical length](#)
- [FME](#), free online course on cervical assessment

BMUS has produced guidance on third trimester ultrasound assessment, [Professional Guidance for Fetal Growth Scans Performed after 23 weeks of Gestation](#), to assist ultrasound practitioners in providing a high-quality, evidence-based service. The document provides advice on biometry, amniotic fluid, placental and Doppler assessment in the third trimester. [2023]

The SoR position statement [Position statement: Assistant practitioners and ultrasound scans for fetal growth monitoring and assessment](#) outlines the requirements for safe practice when undertaking ultrasound assessment of fetal growth. [2025]

5.7.5 Postpartum ultrasound

[2025]

Postpartum ultrasound can be employed to evaluate the uterus and endometrial cavity. Ultrasound practitioners should be conversant with the sonographic appearance of the postpartum pelvis, alongside current existing guidance. Peer reviewed literature can aid in developing a comprehensive understanding of normal and pathological findings. Ultrasound practitioners are encouraged to conduct a literature search for the most up-to-date evidence; the articles listed below provide a useful starting point.

- Üçyiğit and Johns. [The postpartum ultrasound scan](#)
 - Vardar *et al.* [Pelvic ultrasonography of the postpartum uterus in patients presenting to the emergency room with vaginal bleeding and pelvic pain](#)
- [2025]

5.7.6 Multiple pregnancy

To ensure the most appropriate pathway of care for multiple pregnancies, it is important to determine the chorionicity (number of placentas) and amnionicity (number of amniotic sacs) of the pregnancy, ideally in the first trimester between 11⁺² weeks and 14⁺¹ weeks ([NICE, 2019](#)). This includes reporting the following structures:

- Number of gestation sacs
- Number of placentas
- Presence or absence of amniotic membranes
- Thickness of membranes if present (thin or thick)
- Insertion of membrane T-sign or λ-sign (lambda)

TABLE 13: Determining amnionicity and chorionicity with ultrasound

Structure	Monochorionic monoamniotic (MCMA)	Monochorionic diamniotic (MCDA)	Dichorionic diamniotic (DCDA)
Number of gestation sacs	One	Two	Two
Number of placentae	One	One	Two
Membranes	None	Present <ul style="list-style-type: none"> • Thin membrane (2 layers) • Comprises 2 amnion 	Present <ul style="list-style-type: none"> • Thick membrane (4 layers) • Comprises 2 amnion and 2 chorion (see Figure 17)
Insertion of membrane	None	T-sign	λ-sign

Additional scans will be offered throughout the pregnancy, as multiple pregnancies are at higher risk of complications. The number and timing of scans will depend on the chorionicity and amnionicity. When scanning multiple gestations, it is important to have consistent methods of labelling each fetus, to enable accurate monitoring of growth. Ultrasound examinations will be performed to assess for growth discordance and in MCDA twins to detect signs of twin-to-twin transfusion syndrome.

Several guidelines need to be reviewed when developing local protocols for the assessment and management of multiples pregnancies. These include:

- [ISUOG Practice Guidelines](#): Role of ultrasound in twin pregnancy (2018)
- [NICE Guideline \[NG137\]](#): Twin and triplet pregnancies (2019)
- [NICE Quality standard \[QS46\]](#): Multiple pregnancy: twin and triplet pregnancies (updated 2019)
- [RCOG Green-top Guideline \[No.51\]](#): Monochorionic twin pregnancy, management (2016)

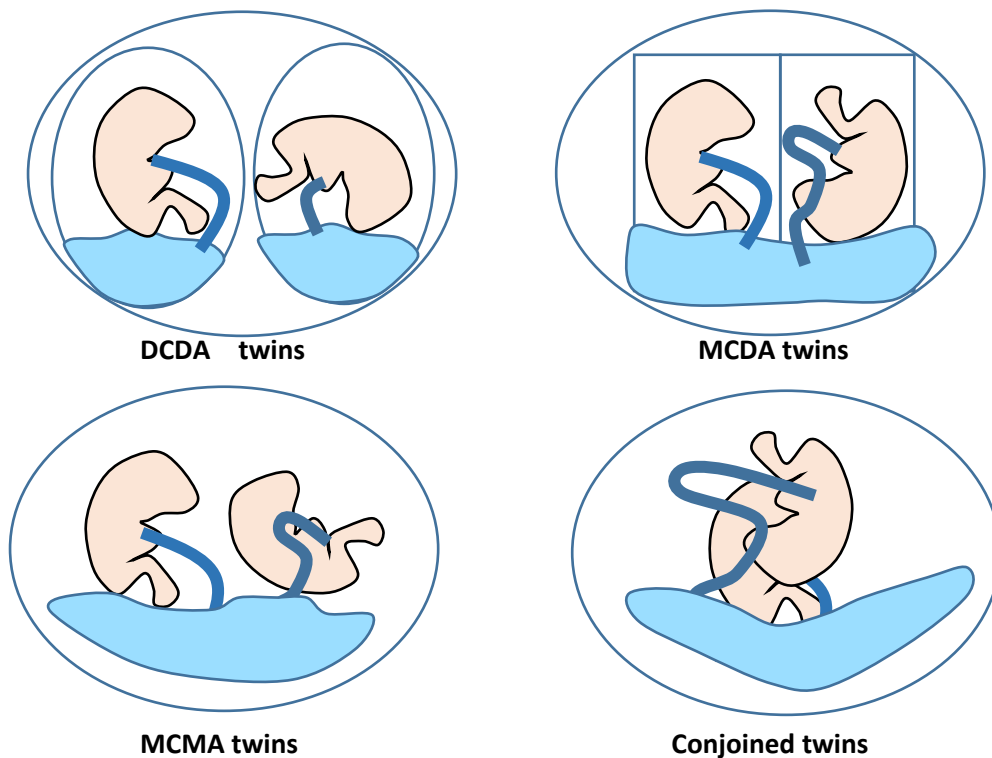


Figure 17: Diagram of the different types of twinning

- 21_01 - [Obstetric Ultrasound: Introduction](#)
 - 21_02 - [Obstetric Ultrasound: Biochemistry](#)
 - 21_03 - [Obstetric Ultrasound: Normal First Trimester](#)
 - 21_04 - [Obstetric Ultrasound: Abnormal First Trimester](#)
 - 21_05 - [Obstetric Ultrasound: Nuchal Translucency](#)
 - 21_06 - [Obstetric Ultrasound: Normal Fetal Anomaly Scan](#)
 - 21_07 - [Obstetric Ultrasound: Fetal Head and Face](#)
 - 21_08 - [Obstetric Ultrasound: Fetal Heart and Chest](#)
 - 21_09 - [Obstetric Ultrasound: Fetal Abdomen](#)
 - 21_10 - [Obstetric Ultrasound: Fetal Spine and Skeleton](#)
 - 21_11 - [Obstetric Ultrasound: Third Trimester Scanning](#)
 - 21_12 - [Obstetric Ultrasound: Applications of Doppler Ultrasound](#)
 - 21_13 - [Obstetric Ultrasound: Placental and Cervical Assessment in Pregnancy](#)
 - 21_14 - [Obstetric Ultrasound: Multiple Pregnancy](#)
 - 21_15 - [Obstetric Ultrasound: Ultrasound-guided Interventional Procedures](#)
-

5.7.7 *Obstetric ultrasound reporting examples*

Referral for early pregnancy bleeding

Clinical details: PV bleeding. LMP 6 weeks ago. ?Miscarriage.

Transvaginal ultrasound of the pelvis with verbal consent. Chaperone XX present:

The uterus appears normal.

A gestation sac with a mean sac diameter of 14mm is present within the endometrial cavity. No evidence of a yolk sac or embryo.

Both ovaries appear normal.

No free fluid seen.

Conclusion:

Pregnancy of uncertain viability.

A rescan has been arranged for 7 days and the findings have been discussed.

X has been advised to contact EPAU if symptoms worsen.

Referral for a rescan in early pregnancy bleeding

Clinical details: Rescan. LMP 8 weeks ago. Scan 1 week ago (date) showed 5mm embryo with no cardiac activity.

Transvaginal ultrasound of the pelvis with verbal consent. Chaperone XX present:

The uterus appears enlarged, measuring 110 x 60 x 43mm.

The gestation sac seen at the previous scan is irregular in outline and contains a yolk sac and 5mm embryo with no cardiac activity. Appearances are unchanged from the scan 1 week ago.

The right ovary appears normal. The left ovary contains a 37mm corpus luteal cyst, unchanged from the previous scan.

Conclusion:

Appearances suggest miscarriage. Findings were discussed and XX was seen in EPAU immediately following the scan.

Referral for first trimester scan

Clinical details: Dating scan. LMP 13 weeks ago. Combined screening **declined**.

Discussed the screening leaflet, choices available, limitations and optional nature of the combined screening. Also explained the possible implications of potential findings, including NT>3.5mm and unexpected physical conditions. Advised to discuss with the midwife if additional support is required.

Transabdominal ultrasound of the pelvis with verbal consent. Chaperone XX present:

A twin pregnancy is noted within the uterus. Single anterior placenta seen with a thin membrane and a T-sign, indicating a monochorionic diamniotic twin pregnancy.

Both fetal heart pulsations present. Normal appearances for this stage of pregnancy.

Twin on the left: CRL = 69mm = 13⁺¹ week

Twin on the right: CRL = 67mm = 13⁺⁰ weeks

The right ovary appears normal. The left ovary contains a 37mm corpus luteal cyst.

Discussed the nature of the 20 week screening scan and the implications in relation to screening choice. This has been arranged.

Conclusion:

Live MC/DA twin pregnancy.

EDD XX/XX/XXXX

Referred to antenatal clinic for discussion about antenatal care.

Further information can be found at:

- Denison, F., Aedla, N., Keag, O., Hor, K., Reynolds, R., Milne, A., and Diamond, A. (2019). Care of Women with Obesity in Pregnancy. Green-top Guideline No. 72. BJOG An Int. J. Obstet. Gynaecol. 126, e62–e106.
- Jauniaux, E., Alfirevic, Z., Bhide, A., Belfort, M., Burton, G., Collins, S., Dornan, S., Jurkovic, D., Kayem, G., Kingdom, J., *et al.* (2019). Placenta Praevia and Placenta Accreta: Diagnosis and Management. Green-top Guideline No. 27a. BJOG An Int. J. Obstet. Gynaecol. 126, e1–e48.
- Jauniaux, E., Alfirevic, Z., Bhide, A., Burton, G., Collins, S., and Silver, R. (2019). Vasa Praevia: Diagnosis and Management. Green-top Guideline No. 27b. BJOG An Int. J. Obstet. Gynaecol. 126, e49–e61.
- Management of Monochorionic Twin Pregnancy. Green-top Guideline No. 51 (2017). BJOG An Int. J. Obstet. Gynaecol. 124, e1–e45.
- Pasupathy, D., Denbow, M., and Rutherford, M. (2019). The Combined Use of Ultrasound and Fetal Magnetic Resonance Imaging for a Comprehensive Fetal Neurological Assessment in Fetal Congenital Cardiac Defects. BJOG An Int. J. Obstet. Gynaecol. 126, e142–e151.
- Royal College of Obstetricians and Gynaecologists (2013). Small-for-Gestational-Age Fetus, Investigation and Management (Green-top Guideline No. 31). Available at: <https://www.rcog.org.uk/en/guidelines-research-services/guidelines/gtg31/>.

SECTION 6: Additional procedures

6.1 Elastography

Advances in ultrasound technologies have expanded the clinical applications of ultrasound over recent years. Historically, ultrasound has been a primary imaging modality, but it is now common for ultrasound to be utilised in other techniques such as needle placement, joint injections, guided biopsies and interventional procedures and, more recently, in the diagnosis and management of patients with chronic liver diseases.

Recent advances in elastography techniques such as acoustic radiation force impulsion (ARFI) and transient elastography (TE) have expanded the use of ultrasound into disease management. They can also enable lesion characterisation and the mapping of tissue stiffness. This reproduces/replaces the palpation performed by clinicians. Elastography has been used for several years in the assessment of the liver. There is an emerging role for elastography in non-hepatic applications including, for example, thyroid, prostate and renal. This section will focus on hepatic applications. The European Federation of Societies of Ultrasound in Medicine and Biology's [EFSUMB guidelines and recommendations for the clinical practice of elastography in non-hepatic applications: Update 2018](#) (2019) provide further information on non-hepatic applications of elastography.

At present there are two main forms of elastography which are being used routinely in clinical practice.

Strain elastography (SE)

Quasi-static or strain elastography (SE) is where the tissue deformation is produced by external palpation with the ultrasound transducer. Most manufacturers overlay a speckle map on the ultrasound image, which is coded in a colour or grey-scale to show a pattern of strain, which is inversely related to the tissue stiffness and can be assessed subjectively. These images are semi-quantitative and do not directly depict the elasticity, which is derived from Young's modulus (stress/strain ratio).

Shear wave elastography (SWE)

Conventional ultrasound and shear waves are both pressure waves that are conducted through soft tissue. Unlike conventional ultrasound waves, shear waves are transverse in their directionality, they are rapidly attenuated by soft tissue and travel more slowly (between 1m/s and 10m/s). Their speed is closely related to Young's modulus of elasticity. Shear waves are created naturally from muscle movements or in cardiac activity and can be induced by ultrasound scanners which use them to measure their speed in a particular tissue or organ.

Liver fibrosis assessment

Most chronic liver diseases have alterations in the functional and structural appearance of the liver. The risk of developing cirrhosis and liver-related complications in viral and non-viral chronic liver diseases is correlated to the amount of liver fibrosis. The detection and classification of liver fibrosis is pivotal for assessing progression and when to commence patients on antiviral therapies. Liver biopsy has been the traditional approach for fibrosis assessment and disease classification, but it is invasive and has potentially severe complications in up to 1% of cases ([Neuberger et al., 2020](#)), with associated cost implications. NICE (2015, updated 2020), in its [Medical technologies guidance \[MTG27\]](#), advocates elastography in the diagnosis and monitoring of fibrosis in chronic hepatitis. The safety implications for patients should also be considered, as well as its tolerability and its ability to be undertaken in an outpatient setting. It allows monitoring of patients over time, without risks or

associated complications of biopsy. Giving the economic challenges facing healthcare today, this technique could have the potential to deliver large savings.

One difficulty with liver elastography is the different methods and multitude of ultrasound manufacturers providing a method of stiffness assessment. This results in the varying cut-off values being ultrasound scanner specific and not transferable across different makes of equipment. Consequently, it is essential that patients undergoing monitoring are assessed on equipment made by the same manufacturer to ensure continuity of readings or, where this is not the case, that this is clearly stated within the report together with any effects on the values obtained.

Transient elastography (TE)

One method of SWE is transient elastography (TE), which is performed using the Fibroscan® (Echosens, Paris, France). This is a mechanical system using a single-element ultrasound transducer that is used to apply light pressure on the patient's skin, usually intercostally, to assess the liver parenchyma. The resultant shear wave travels through liver tissue along the direction of the ultrasound beam and is used to measure its speed in a manner similar to M-mode. In patients with chronic hepatitis C, liver stiffness values are greater than 6.8–7.6kPa. The cut-off values for predicting cirrhosis range between 11.0 and 13.6kPa. Evidence suggests that TE has limitations in differentiating between mild and significant fibrosis. Other limitations include the requirement of dedicated equipment with specific probes and an intercostal scan approach. The technique is standardised and can be employed in various settings. It is currently being used mainly outside the radiology department in outpatient settings.

Acoustic radiation force impulse (ARFI)

ARFI generates shear waves by causing small displacements in the soft tissue, causing sideways pressure waves away from the ultrasound beam that allow ultrasound systems to measure speed with good spatial resolution. Many manufacturers also include an indication of the quality of the shear wave within the software capabilities, offering additional reassurance of the level of fibrosis acquired.

ARFI accuracy for the assessment of liver fibrosis has been similar to that of TE, with some more promising results in patients with non-alcoholic fatty liver disease (NAFLD) and non-alcoholic steatohepatitis (NASH), and in post-transplantation. It has the advantage of allowing a radiological assessment of the liver parenchyma and more accurate localisation of the sample site. Fatty infiltration can thus be avoided so as not to skew fibrosis scoring.

The [EFSUMB Guidelines and Recommendations on the Clinical Use of Liver Ultrasound Elastography, Update 2017 \(Long Version\)](#) (2017) recommend the use of SWE to assess the severity of patients with liver disease with viral hepatitis. The guidelines also state that SWE is promising in NAFLD and post-transplantation.

Justification and clinical history

Patient conditions requiring liver fibrosis assessment may include the following (this is not an exhaustive list):

- Alcoholic liver disease
- Hepatitis B
- NAFLD
- Increasingly, GPs are referring for liver elastography, from primary care, in patients with a high fibrosis-4 (FIB-4) score ([Sterling et al., 2006](#)) and high NAFLD score
- Some genetic diseases (e.g. cystic fibrosis, haemochromatosis)
- In specific patients post-chemotherapy

- Abnormal metabolism (e.g. obesity, dyslipidaemia)
- High-risk patients with abnormal LBTs and other relevant serum/biomarkers such as platelet ratio index, type IV collagen, hyaluronic acid
- Abnormal B-mode scan
- Assessing drug-induced liver fibrosis

Technique

The patient should ideally have fasted for at least 4 hours prior to examination and avoided alcohol for 72 hours, to avoid falsely elevated liver stiffness measurements.

Shear wave speed measurements are performed intercostally in the right liver with conventional curved arrays. The probe is aligned along an intercostal space.

To reduce inter-observer variation, SWE should be performed with the patient in the oblique position on arrested respiration, in segment IV (a) or segment VIII. This allows reproducible follow-up as these patients will need further scans.

Ten measurements should be acquired. The most effective parameter to quote is the median value in either m/sec or kPa. It is important to quote the interquartile range to maintain the quality of the measurement.

***(Insert machine name or number) examination**

The average ARFI reading in this patient is **xx m/s**. (Normal range median 1.59m/s)

An increase in ARFI reading indicates an increase in liver stiffness and associated fibrosis

Fibrosis Stage	Median	Mean	Range
F1	1.64m/s	1.59m/s	1.18–1.92m/s
F2	1.76m/s	1.68m/s	1.46–2.03m/s
F3	2.21m/s	2.07m/s	1.63–2.43m/s
F4	2.82m/s	2.92m/s	1.68–4.5m/s

Reference: Lijima (2014) [Approaches to the diagnosis of liver fibrosis](#)

The recommended depth is between 3cm and 7cm.

Management advice

While differing manufacturers have different shear wave velocities for stages of liver disease, it is noted that the following, based on NICE publication [MTG27](#), are given as examples of disease staging:

- Normal <1.2m/s
- Fibrosis ≥1.21–1.34m/s
- Cirrhosis ≥1.55–2.00m/s

The most recent ultrasound machines can display the SWE in either m/sec or kPa. Therefore, it may be helpful to consult with local hepatologists to agree the preferred unit of measurement.



Extreme caution is required when quoting shear wave velocities in ultrasound reports. It is useful to report the shear wave velocity and quote the relevant reference values for the machine used, to minimise confusion between normal and abnormal readings compared to the stage of liver disease. Practitioners are advised to refer to individual manufacturers' reference ranges when reporting shear wave studies in liver disease.

6.1.1 Elastography reporting examples

Local protocols are essential and should be agreed with all stakeholders (gastroenterologists and/or hepatologists). It is noted that some centres give values only, without interpretation, as set out below, to allow specialist consultant review in the context of blood test results and patient presentation.

Further information can be found at:

- Barr, R.G., Wilson, S.R., Rubens, D., Garcia-Tsao, G., and Ferraioli, G. (2020). Update to the Society of Radiologists in Ultrasound Liver Elastography Consensus Statement. *Radiology* 296, 263–274.
- Dietrich, C., Bamber, J., Berzigotti, A., Bota, S., Cantisani, V., Castera, L., Cosgrove, D., Ferraioli, G., Friedrich-Rust, M., Gilja, O., *et al.* (2017). EFSUMB Guidelines and Recommendations on the Clinical Use of Liver Ultrasound Elastography, Update 2017 (Long Version). *Ultraschall der Medizin* 38, e16–e47.
- Gennisson, J.L., Deffieux, T., Fink, M., and Tanter, M. (2013). Ultrasound elastography: Principles and techniques. *Diagn. Interv. Imaging* 94, 487–495.
- Jeong, W.K., Lim, H.K., Lee, H.K., Jo, J.M., and Kim, Y. (2014). Principles and clinical application of ultrasound elastography for diffuse liver disease. *Ultrasonography* 33, 149–160.

6.2 Contrast-enhanced ultrasound (CEUS)

General scanning principles

Ultrasound contrast agents are formulated into a microbubble structure which performs as a blood pool tracer when used in conjunction with contrast-specific imaging modes using a low mechanical index (MI) technique. An example is SonoVue™ (sulphur hexafluoride). SonoVue™ has been highlighted in this document specifically due to the availability of NICE guidance on its specific use. Ultrasound contrast agents are intravenously injected to demonstrate the vasculature and microvasculature of organs and potential lesions.

CEUS is primarily used for hepatic applications, as recommended by [NICE \[DG5\] \(2012\)](#). EFSUMB recommends the use of ultrasound contrast for a variety of other applications ([EFSUMB, 2017](#)).

Justification and structures to examine and evaluate

The main hepatic applications of CEUS include:

- Characterisation of focal liver lesions in non-cirrhotic cases
- Characterisation of benign lesions
- Detection of liver metastases in patients at high risk of liver metastases, e.g. those with a primary cancer who have not undergone CT staging, patients with sudden unintentional weight loss, abnormal LBTs and otherwise equivocal liver appearances on a baseline scan; patients for pre-treatment staging should ideally undergo CT
- Doppler 'rescue' to identify flow in technically difficult examinations, e.g. hepatic artery demonstration in a difficult post-transplant scan
- Lesion localisation pre-ablation and for ultrasound-guided biopsy
- Post-ablation checks
- Trauma, to identify soft organ damage, if CT cannot be performed
- Trauma follow-up looking for pseudoaneurysms and resolution of lacerations
- Patients with cirrhosis and known focal lesions should ideally be referred to MRI for characterisation and further exclusion of HCC; however, if the patient is unable to undergo MRI, CEUS may provide valuable additional information on lesion characterisation
- See Dietrich *et al.*, 2020 [Guidelines and Good Clinical Practice Recommendations for Contrast-Enhanced Ultrasound \(CEUS\) in the Liver-Update 2020 WFUMB in Cooperation with EFSUMB, AFSUMB, AIUM, and FLAUS](#).

Extrahepatic applications include:

- Characterisation of complex renal cysts ([Ascenti *et al.*, 2007](#)), e.g. with septations or containing debris and/or possible solid material; CEUS may be offered as a first-line characterisation; complex, suspicious cysts and solid masses (Bosniak 4) should be referred urgently to CT
- Vascular patency/detection of infarcts and cortical necrosis in difficult renal transplant scans
- Sentinel node/lymph node detection in patients with breast cancer
- Follow-up of endovascular aneurysm repair (EVAR) stents to establish patency and detect/characterise leaks
- Hysterosalpingo contrast sonography (HyCoSy) to assess tubal patency



It is the practitioner's responsibility to be aware of the licensed use of ultrasound contrast agents such as SonoVue™, Definity, Optison and Sonazoid. Where the contrast agent is used 'off label', local agreement to its use, and by whom within the department, should be documented. The patient's verbal consent for the use of contrast 'off label' should be sought and documented.

Technique

Administration is performed via an intravenous cannula.

Use of contrast agents by non-medical staff, usually sonographers, should come within the remit of a patient group direction (PGD) or other legal mechanism that allows the prescribing and safe administration of the drug ([ref: section 6.4](#)).



An ultrasound practitioner must be statutorily registered to follow a PGD. Voluntary registration is not sufficient.

Safety

The microbubble agents currently available are not nephrotoxic, making them a useful alternative for patients with renal compromise ([Piscaglia et al., 2006](#)).

They have a low incidence of adverse reactions, although there is a small risk of anaphylactoid reactions to CEUS (rate estimated at 1:10,000) and resuscitation facilities with emergency equipment and personnel trained in its use should be available. It is recommended that the patient be kept under close medical supervision during and for at least 30 minutes following administration of SonoVue™. A programme of annual basic life support training should be in place for staff, according to the RCR and SCoR [Standards for the provision of an ultrasound service](#).

Microbubble agents are currently not licensed in pregnancy or in children. However, in children they may be used either 'off label', i.e. outside of the manufacturer's marketing authorisation, or 'unlicensed', i.e. no UK licence, or being made up in a way that it was not intended to be used. The use of 'off label' is allowed when considered 'best clinical practice' according to the [Specialist Pharmacy Service](#) and NICE, 2017 [MPG2].

In April 2016 the US Food and Drug Administration gave approval for the use of CEUS in the USA in children with focal liver lesions. The EFSUMB guidelines (2017) [Role of Contrast Enhanced Ultrasound \(CEUS\) in Paediatric Practice: An EFSUMB Position Statement](#) assess the status of CEUS applications in children and make suggestions for further development of this technique.

Equipment

Contrast-specific software is required to perform CEUS.

A low-MI technique helps to preserve the microbubbles, enabling a longer survey time.

The facility to record a short video clip of all phases for at least 3 minutes is essential when using CEUS to characterise lesions. The temporal resolution of CEUS is superior to any other current imaging modality, and the ability to review the arterial phase, frame by frame, provides a valuable contribution to the diagnostic process, while the ability to compare portal and late phase against arterial phase is vital for assessing washout, a hallmark of malignancy.

Extending the examination

CEUS can be an extremely useful tool in combination with fusion imaging, particularly in the planning and execution of biopsy/ablation in difficult to visualise lesions, using the cross-sectional modality to guide the area of interrogation with CEUS.

Management

Figure 18 is an example of a departmental patient pathway for managing a focal liver lesion. See the BMUS document '[Managing incidental findings](#)'.

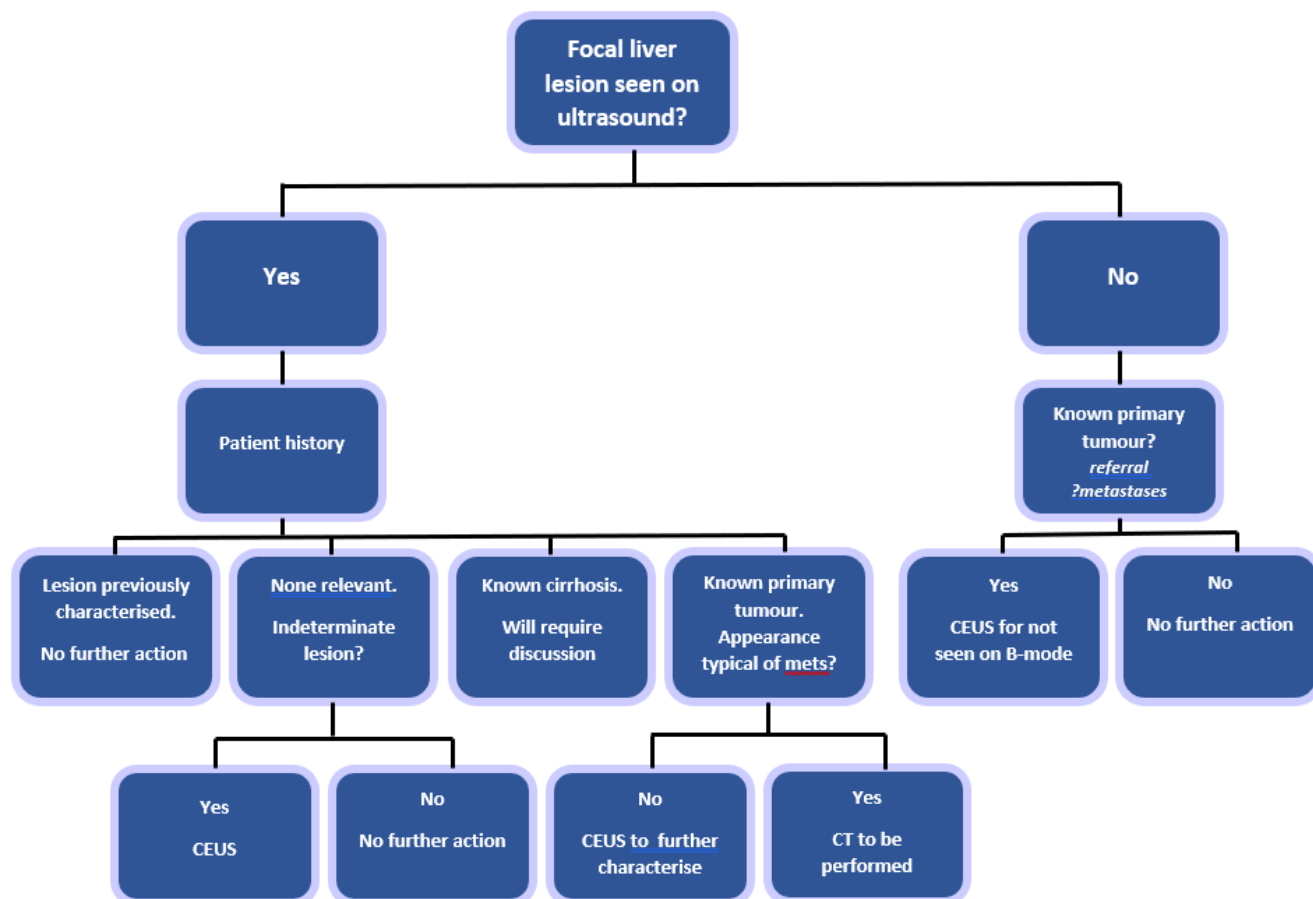


Figure 18: Ultrasound pathway for focal liver lesions. Stenberg, B. McNeill, A. and Hoare, T.; based on [NICE \[DG5\] \(2012\)](#) and [Dietrich *et al.*, 2020](#).

6.2.1 CEUS reporting examples

Benign liver lesion

B-mode findings: 2cm well-defined echogenic lesion seen in segment 6 of the liver. B-mode findings are indeterminate but likely to represent a haemangioma.

CEUS following verbal consent. 2.4ml SonoVue IV. Low-MI contrast-specific imaging.

CEUS findings: Discontinuous nodular peripheral enhancement seen in the arterial phase with subsequent centripetal filling throughout the portal and late phase. No washout seen in the late phase.

Conclusion:

Lack of washout is reassuring for a benign lesion.

The arterial enhancement pattern is consistent with a haemangioma

Malignant liver lesion

B-mode findings: 1cm ill-defined hypoechoic lesion seen in segment 3 of the cirrhotic liver. B-mode findings are suspicious for a malignant lesion.

CEUS following verbal consent. 2.4ml SonoVue IV. Low-MI contrast-specific imaging.

CEUS findings: Rapid, homogeneous hyperenhancement seen from 12 seconds post-injection relative to background liver. During the portal phase (from 75 seconds post-injection) the lesion becomes relatively hypoenhancing and progressively washes out for the duration of the late phase.

Conclusion:

Hyperenhancement with subsequent washout is highly suspicious for a malignant lesion. Given the background cirrhosis and lack of known primary elsewhere, HCC is most likely.

EVAR

B-mode findings: No evidence of leak seen within the aortic aneurysm sac on B-mode and colour Doppler ultrasound.

CEUS following verbal consent. 2.4ml SonoVue IV. Low-MI contrast-specific imaging.

CEUS findings: Following injection of contrast there is prompt filling of the aortic stent graft at 15 seconds. Microbubbles appear in the left posterolateral sac from 35 seconds. This appears to arrive from the posterolateral wall and is self-contained with no exit point identified. No communication identified with the stent graft.

Conclusion:

Appearances are consistent with a type II aortic endoleak from a left posterolateral vessel.

Further information can be found at:

- Kyung Yang, H., Burns, P.N., Jang, H.J., Kono, Y., Khalili, K., Wilson, S.R., and Kyoung Kim, T. (2019). Contrast-enhanced ultrasound approach to the diagnosis of focal liver lesions: the importance of washout. *Ultrasonography* 38, 289–301.
- Tedesco, G., Sarno, A., Rizzo, G., Grecchi, A., Testa, I., Giannotti, G., and D’Onofrio, M. (2019). Clinical use of contrast-enhanced ultrasound beyond the liver: a focus on renal, splenic, and pancreatic applications. *Ultrasonography* 38, 278–288.

6.3 Interventional and ‘extended scope’ examinations for sonographers

[2018]

As part of HEE’s [Multi-professional framework for advanced practice](#) (2025), many sonographers are extending their scope of clinical practice, in addition to undertaking work in the other advanced practice areas of audit and research, education, leadership and management. **[updated 2025]**

There are a wide range of examinations that come within the overall scope of practice of ultrasound practitioners. For those who are not medically qualified or registered with the GMC (e.g. sonographers), they are sometimes termed ‘extended scope’ examinations. They include diagnostic procedures such as biopsy, FNA, HyCoSy sonography, drainage of body cavities and therapeutic procedures such as joint injections.

Examples of the type of ultrasound examinations undertaken by sonographers and to which this section refers are as follows:

- Biopsy/FNA, e.g. breast, prostate, liver, thyroid
- Drainage, e.g. of ascites, effusions, abscess
- Therapeutic, e.g. joint injections
- Diagnosis, e.g. HyCoSy, CEUS

When implementing such extended scope services, the approval of the clinical lead, service manager and trust, health board or provider organisation must be sought.

The following will all need to be considered:

- Support from a lead medical practitioner
- Appropriate training
- PII
- Quality assurance and audit programmes
- Consent procedures and acceptance that a sonographer is the person who should obtain this
- Protocols for each individual type of procedure that the sonographer will undertake
- PGDs as necessary; some sonographers, depending on their professional background, may be supplementary or independent prescribers ([ref: section 6.4](#)); sonographers must be statutorily registered to use a PGD – voluntary registration is not sufficient

6.4 Supplying, prescribing and administering medicines

[updated 2023]

In order to deliver safe and effective healthcare that also offers a good experience for patients, providers need to ensure that they are maximising the full potential of their entire clinical workforce. The aim is to enable quality improvement, innovation and greater productivity in service delivery.

Ultrasound practitioners, depending on their professional background and registration status, have different legal mechanisms available to them when supplying, prescribing or administering medicines. It is important that ultrasound practitioners understand the law and what they can and cannot do within their professional sphere. This document provides an overview of which professionals can do what and under which legal framework.

The [Human Medicines Regulations 2012](#) and subsequent amendments set out the regime for the authorisation of medicinal products for human use. They define legal roles and responsibilities for medicines used in healthcare. The [Misuse of Drugs Act 1971](#) deals specifically with issues related to the prescribing and administration of controlled drugs.

[Specialist Pharmacy Services](#) host a range of resources to support the safe use of medicines in the NHS. Sonographers working in Northern Ireland, Scotland and Wales should consult their relevant advisory service for any additional information:

- [Northern Ireland](#)
- [Scotland](#)
- [Wales](#)

Greater flexibility of prescribing and medicines supply and administration has the potential to reduce treatment delays, improve specificity and responsiveness of prescribing and thereby reduce patients' exposure to safety risks. Safety considerations relate to training arrangements, communication of prescribing and governance arrangements as well as the safe handling and physical security of the medicines chain [Royal Pharmaceutical Society of Great Britain](#) (2018).

6.4.1 Prescribing

To be a prescriber means to have the legal authority to issue prescriptions. In practice, prescribing is a complex clinical skill. Doctors are by far the largest group of prescribers who, along with dentists, can prescribe on registration. Certain other registered professions can train to become non-medical prescribers (NMPs) once they have completed an approved programme of education delivered by a higher education institution. HEE, [Training for non-medical prescribers](#) and [HCPC, 2021](#).

The Royal Pharmaceutical Society (RPS) has created a [Prescribing Competency Framework](#) for all prescribers that has been designed to help maintain prescribing standards, inform education curricula and provide a source of recognised guidance for those involved in prescribing, regardless of their professional background.

Appropriately trained healthcare professionals can prescribe medicines as either independent or supplementary prescribers.

Independent prescribing **[updated 2025]**

Independent prescribers are practitioners responsible and accountable for the assessment of patients with previously undiagnosed or diagnosed conditions and for decisions about the clinical management required, including prescribing ([NICE, Non-medical prescribing](#)).

In addition to GMC-registered doctors, registered nurses, pharmacists, optometrists, physiotherapists, therapeutic radiographers, paramedics, and podiatrists can train to work as independent prescribers, provided they stay within their defined legal authority and clinical competence.

There is a government-led consultation proposing to permit diagnostic radiographers to train as independent prescribers. This consultation is expected to conclude in late 2025. As a result, there may be legal changes that allow diagnostic radiographers to pursue training as independent prescribers. For the latest updates on this matter, it is advisable to check current sources such as the Gov.uk and the SoR website.

Supplementary prescribing

Supplementary prescribing is a voluntary partnership between a doctor or dentist and a supplementary prescriber to prescribe within an agreed patient-specific clinical management plan (CMP) with the patient's agreement.

Registered nurses, optometrists, pharmacists, physiotherapists, podiatrists, radiographers and dietitians may become supplementary prescribers and, once qualified, may prescribe any medicine within their clinical competence and legal authority according to the CMP ([RPS, 2021](#)).

NMPs, whether they are independent or supplementary, must meet the standards set by their regulator and have the appropriate endorsement on the statutory register for their prescribing qualification. They must engage in relevant CPD for their prescribing practice. Additionally, they must have the contractual right to prescribe, typically granted by their employer. Professional body guidelines on prescribing are available and should be consulted. Radiographers should refer to published guidance, such as:

- SoR (2024) [Supply, administration and prescribing of medicines by radiographers](#)
- SoR (2023) [Improving Patients' Access to Medicines: A Guide to Implementing Diagnostic Radiographer and Therapeutic Radiographer Prescribing within the NHS in the UK \(Second Edition\)](#)

- SoR (2023) [Practice Guidance for Radiographer Independent and/or Supplementary Prescribers \(Second Edition\)](#)

Administration and supply

[Professional guidance on the administration of medicines in healthcare](#) has been co-produced by the RPS and the Royal College of Nursing and provides principles-based guidance to ensure the safe administration of medicines by healthcare professionals.

The [SoR](#) offers a certificate of competence in administering intravenous injections on successful completion of an approved education programme.

Any sonographer assessed as competent can administer or supply medicines as long as this role is recognised in local governance policies and within their scope of practice.

The legal mechanism under which they administer or supply the medicine must be appropriate to their professional background and regulatory status.

6.4.2 Legal mechanisms

Patient group directions (PGDs):

PGDs are **not** a form of prescribing.

A PGD is a written instruction to allow healthcare professionals to *supply and administer* specified medicines to pre-defined groups of patients, without a prescription.



The healthcare professional working within the PGD is responsible for assessing that the patient fits the criteria set out in the PGD.

The supply and/or administration of medicines under a PGD cannot be delegated. The whole episode of care must be undertaken by a named healthcare practitioner trained to operate under the PGD.

The following is a list of registered professionals who can use PGDs (Gov.uk, [Patient group directions: who can use them](#)):

- Chiropodists and podiatrists
- Dental hygienists
- Dental therapists
- Dietitians
- Midwives
- Nurses
- Occupational therapists
- Optometrists
- Orthoptists
- Orthotists and prosthetists
- Paramedics
- Pharmacists
- Physiotherapists
- Radiographers
- Speech and language therapists

The following cannot be supplied under a PGD:

- Unlicensed medicines
- Dressings, appliances and devices
- Radiopharmaceuticals
- Abortifacients, such as mifepristone

[NICE Patient group directions. Medicines practice guideline \[MPG2\]](#) covers good practice for developing, authorising, using and updating PGDs. It also offers advice on deciding whether a PGD is needed.

PGDs can be complex and time-consuming to generate. They must be signed by the appropriate authorities to meet legal requirements. The [Specialist Pharmacy Service](#) provides expert advice for NHS care provided in England, including a suite of Radiology PGD templates which can be adapted for other medicines commonly used. The SoR endorses the information in these templates for use throughout the UK, acknowledging any necessary adaptations for PGDs in devolved countries.

Patient Specific Directions (PSDs):

While not defined in legislation, a PSD is:

the traditional written instruction, signed by a prescriber [doctor, dentist, or non-medical prescriber - referred to as 'the prescriber'] for medicines to be supplied and/or administered to a named patient after the prescriber has assessed that individual on a one-to-one basis.

In practice a PSD is commonly referred to as a prescription by those who write them or use them as a legal basis to administer a medication because this indicates that it is written by a prescriber ([Specialist Pharmacy Service](#)).

Where a PSD exists, there is no need for a PGD.

The key aspects of a PSD are as follows:

- The prescriber is responsible for assessment of the patient and the decision to authorise the supply/administration of the medicine(s) in question.
- The prescriber has a duty of care and is professionally and legally accountable for the care they provide.
- The prescriber must be satisfied that the person to whom the administration is delegated has the qualifications, experience, knowledge and skills to provide the care or treatment involved ([Specialist Pharmacy Service, 2020](#)).
- Any competent individual authorised by the employer can follow a PSD. No variation is allowed from the instruction in the PSD, which must be in written format and accessible in the care record.

6.5 Artificial intelligence

[2025]

AI is now embedded in many ultrasound systems. Ultrasound practitioners must understand how to integrate AI into their workflow without compromising patient care or outcomes. Guidance is evolving rapidly, so ultrasound practitioners need to be conversant with the latest research and publications.

The RCR (2025) [Standards for the interpretation and reporting of imaging investigations guidance](#), 3rd edition state that “all AI-derived contributions should be reviewed, verified and approved by a named human author, who is responsible for the final report.”

Consequently, appropriate training should be provided whenever AI tools are introduced into practice.

Relevant professional body guidance includes:

- SoR (2021) [Artificial intelligence: Guidance for clinical imaging and therapeutic radiography workforce professionals](#)
- SCoR (2020) [The Society and College of Radiographers policy statement: Artificial Intelligence](#)
- SoR [AI webinar series](#) [SoR member login required]

Abbreviations and acronyms

AAA	Abdominal aortic aneurysm
ACAS	Advisory, Conciliation and Arbitration Service
ACJ	Acromioclavicular joint
ADPKD	Autosomal dominant polycystic kidney disease
AEPU	Association of Early Pregnancy Units
AHCS	Academy for Healthcare Science
AI	Artificial intelligence
AKI	Acute kidney injury
ALARA	As low as reasonably achievable
AP	Anteriorposterior
ARFI	Acoustic radiation force impulsion
ASA	Advertising Standards Authority
AXREM	Association of Healthcare Technology Providers for Imaging, Radiotherapy and Care
βhCG	Beta human chorionic gonadotrophin
BMI	Body mass index
BMUS	British Medical Ultrasound Society
BSE	British Society of Echocardiography
BSGI	British Society of Gynaecological Imaging
BSP	Breast screening programme
BTA	British Thyroid Association
CASE	Consortium for the Accreditation of Sonographic Education
CBD	Common bile duct
CCG	Clinical commissioning group
CCP	Cyclic citrullinated peptide
CD	Common duct
CEUS	Contrast-enhanced ultrasound
CID	Concealed interstitial delamination
CMC	Carpometacarpal
CMP	Clinical management plan
CoR	College of Radiographers
CPD	Continuing professional development
CQC	Care Quality Commission
CRL	Crown rump length
CRP	C-reactive protein
CSVS	College and Society for Clinical Vascular Science Great Britain and Ireland
CT	Computed tomography
DCDA	Dichorionic diamniotic
DE	Deep endometriosis
DIP	Distal interphalangeal
ECU	Extensor carpi ulnaris
EFSUMB	European Federation of Societies for Ultrasound in Medicine and Biology
ENT	Ear nose and throat
EPAU	Early pregnancy assessment unit
ESR	Erythrocyte sedimentation rate
ESSR	European Society of Musculoskeletal Radiology
ESUR	European Society of Urogenital Radiology
EVAR	Endovascular aneurysm repair
FAST	Focused assessment with sonography for trauma
FGM	Female Genital Mutilation
FGR	Fetal growth restriction

FMF	Fetal Medicine Foundation
FNA	Fine needle aspiration
FNH	Focal nodular hyperplasia
GCA	Giant cell arteritis
GDPR	General Data Protection Regulation
GHJ	Glenohumeral joint
GI	Gastrointestinal
GMC	General Medical Council
GP	General practitioner
HCC	Hepatocellular carcinoma
HCPC	Health and Care Professions Council
HEE	Health Education England
HRT	Hormone replacement therapy
HyCoSy	Hysterosalpingo contrast sonography
ICB	Integrated Care Board
IM	Intramuscular
IOTA	International Ovarian Tumour Analysis
IPMN	Intraductal papillary mucinous neoplasm
ISUOG	International Society of Ultrasound in Obstetrics and Gynaecology
ITB	Iliotibial band
IUPUV	Intrauterine pregnancy of uncertain viability
IVC	Inferior vena cava
LBT	Liver blood test (formerly called <i>liver function test, LFT</i>)
LHBT	Long head of biceps tendon
LMP	Last menstrual period
LMS	Leiomyosarcoma
LS	Longitudinal section
LUTS	Lower urinary tract symptoms
MALT	Mucosa associated lymphoid tissue
MCDA	Monochorionic diamniotic
MCMA	Monochorionic monoamniotic
MCP	Metacarpophalangeal
MDT	Multidisciplinary team
MHRA	Medicines and Healthcare Products Regulatory Agency
MI	Mechanical index
mpMRI	Multiparametric MRI
MPNST	Malignant peripheral nerve sheath tumour
MRCP	Magnetic resonance cholangiopancreatography
MRI	Magnetic resonance imaging
MSD	Mean sac diameter
MSK	Musculoskeletal
MTP	Metatarsophalangeal
NAFLD	Non-alcoholic fatty liver disease
NASH	Non-alcoholic steatohepatitis
NHS FASP	Fetal Anomaly Screening Programme
NICE	National Institute for Health and Care Excellence
NIPE	Newborn and infant physical examination
NIPT	Non-invasive prenatal screening
NMC	Nursing and Midwifery Council
NMP	Non-medical prescriber
NSAID	Non-steroidal anti-inflammatory drug

NSC	National Screening Committee
NT	Nuchal translucency
OA	Osteoarthritis
PACS	Picture archiving and communication system
PAPP-A	Pregnancy-associated plasma protein-A
PASTA	Partial articular supraspinatus tendon avulsion
PCOM	Polycystic ovarian morphology
PCOS	Polycystic ovary syndrome
PGD	Patient group direction
PII	Professional indemnity insurance
PIP	Proximal interphalangeal
PMB	Postmenopausal bleeding
PPE	Personal protective equipment
PSA	Professional Standards Authority
PsA	Psoriatic arthritis
PSD	Patient specific directions
PUJ	Pelviureteric junction
PUL	Pregnancy of unknown location
PV	Per vagina
PVRS	Public Voluntary Register of Sonographers
QSI	Quality Standard for Imaging
RA	Rheumatoid arthritis
RCOG	Royal College of Obstetricians and Gynaecologists
RCR	Royal College of Radiologists
RCT	Register of Clinical Technologists
REALM	Radiology events and learning meeting
RF	Rheumatoid factor
RIF	Right iliac fossa
RPOC	Retained products of conception
RPS	Royal Pharmaceutical Society
RUQ	Right upper quadrant
SCC	Squamous cell carcinoma
SCoR	Society and College of Radiographers
SE	Strain elastography
SMG	Submandibular gland
SoR	Society of Radiographers
SSOTM	Shape, size, outline, texture and measurements
STS	Soft tissue sarcoma
SWE	Shear wave elastography
TA	Transabdominal
TAS	Transabdominal ultrasound
TE	Transient elastography
TFL	Tensor fasciae latae
TRUS	Transrectal ultrasound
TS	Transverse section
TV	Transvaginal
TVS	Transvaginal ultrasound
UKAS	United Kingdom Association of Sonographers
UKEPSS	UK Early Pregnancy Surveillance Service
UKHSA	UK Health Security Agency (formerly Public Health England, PHE)
UPJ	Ureteropelvic junction

UTI	Urinary tract infection
WRMSD	Work-related musculoskeletal disorder

Acknowledgements

The SoR and BMUS would like to acknowledge the help and expert advice provided by the following:

December 2015 Edition

For the SCoR

- Nigel Thomson, Professional Officer (Ultrasound), SCoR
- Wendy Williams, Superintendent Sonographer, University Hospital Llandough, Cardiff; Member, Ultrasound Advisory Group, SCoR

All past and current members of its Ultrasound Advisory Group who have contributed to or commented on previously published documents available via www.sor.org

The following SCoR members provided feedback on the final draft

- Alexandra Drought, Gill Harrison, Sally Hill, Steve Savage, Margaret Taylor

For the BMUS Professional Standards Group

- Alison Hall, Consultant Sonographer, Keele University
- Gerry Johnson, Consultant Sonographer, Tameside Hospitals NHS Trust
- Jane Smith, Consultant Sonographer, United Leeds Hospital Trust
- Jean Wilson, Programme Director, Diagnostic Imaging, University of Leeds
- Dr Nick Dudley, Medical Physicist, United Lincoln Hospitals Trust
- Dr Oliver Byass, Consultant Radiologist, Hull and East Yorkshire Hospitals NHS Trust
- Pamela Parker, Ultrasound Specialty Manager, Hull and East Yorkshire Hospitals NHS Trust
- Pat Farrant, Sonographer, Kings College Hospital, London
- Dr Peter Cantin, Consultant Sonographer, Plymouth Hospitals Trust
- Dr Peter Rodgers, Consultant Radiologist, University Hospitals of Leicester
- Dr Rhodri Evans, Consultant Radiologist/Associate Professor, College of Medicine, Swansea University

Due recognition is given to the editors and contributors to previous editions of the UKAS Guidelines whose earlier work forms the foundation of this new document. UKAS merged with the SCoR in January 2009.

Thanks are also given to J.M. Bridson and G. Johnson of the University of Liverpool and Dr P. Rowlands of The Royal Liverpool and Broadgreen University Hospitals NHS Trust, Liverpool, for their previous work on the document 'Clinical Standards and framework for the assessment of initial and ongoing competence of ultrasound practitioners' (BMUS, 2011), which forms the foundation of section [4.5: Recommendations for the production of an ultrasound report](#).

Subsequent revisions, new contributors named at first contribution

December 2017 Revision

Acknowledgement and thanks to the following new contributors to the December 2017 revision:

- Catherine Kirkpatrick, Consultant Sonographer, United Lincolnshire Hospitals NHS Trust
- Dr Jonathan Burdach of Nanosonics Ltd.
- Dr Mike Smith, Senior Lecturer: Physiotherapy, Cardiff University

December 2018 Revision

Acknowledgements and thanks to the following new contributors to the December 2018 edition:

- Gill Harrison, Ultrasound Programme Director & Lead for Teaching Excellence, City, University of London, and Professional Officer for Ultrasound, SCoR
- Hazel Edwards, Sonographer, East and North Hertfordshire NHS Trust

December 2019 Revision

Acknowledgements and thanks to the following new contributors to the December 2019 edition:

- AXREM
- A new style of hyperlink is introduced that is integral with the text and the referencing within the document standardised. Editing and section to section hyperlinks have been included and the document re-ordered. Thanks are due to Gill Harrison, Associate Professor, City, University of London, and Professional Officer for Ultrasound, SCoR, for this work.

December 2020 Revision

Acknowledgements and thanks to the following new contributors to the December 2020 edition:

- Dr Nigel Grunshaw Consultant GI Radiologist, University Hospitals of Morecambe Bay NHS Trust
- Ruth Reeve, Specialist Advanced Practitioner Sonographer, Portsmouth Hospitals University NHS Trust

December 2021 Revision

Full review and edit of the 6th Edition was undertaken by:

- Catherine Kirkpatrick, Consultant Sonographer, United Lincolnshire Hospitals NHS Trust, and Development Officer for BMUS
- Gill Harrison, Professional Officer for Ultrasound, SCoR
- Hazel Edwards, Professional Officer for BMUS

Kind thanks to the following new contributors to the 2021 edition:

- Alex Lipton, , Professional Officer, Society and College of Radiographers
- Allison Harris, Sonographer, Great Ormond Street Hospital for Children NHS Foundation Trust
- Dr Amit Shah, Consultant MSK Radiologist, University Hospitals of Leicester
- Dr Andy McQueen, Head and Neck Radiologist, The Newcastle Upon Tyne Hospitals NHS Foundation Trust
- Dr Benjamin Stenberg, Consultant Sonographer, The Newcastle Upon Tyne Hospitals NHS Foundation Trust
- Colin Griffin, Consultant Sonographer, Liverpool University Hospitals NHS Foundation Trust
- Donna Holdcroft, Lecturer (Ultrasound), Keele University
- Dorothy Keane, Professional Officer, Society and College of Radiographers
- Emily Skelton, Lecturer, City, University of London
- Dr Jeanette Kraft, Consultant Paediatric Radiologist, Leeds Teaching Hospitals NHS Trust
- Morag Stout, Consultant Sonographer, Greater Glasgow and Clyde Health Board
- Penny Moores, Consultant Sonographer, James Paget University Hospitals NHS Foundation Trust, Great Yarmouth
- Shaunna Smith, Clinical Specialist Sonographer, Hull University Teaching Hospitals
- Stephen Moore, Sonographer, Glasgow Royal Infirmary, NHS Greater Glasgow and Clyde
- Sue Johnson, Professional Officer, Society and College of Radiographers
- Terry Humphrey, Consultant Paediatric Sonographer, Leeds Teaching Hospitals NHS Trust

Document history

Prior to the SoR and BMUS collaboration to produce the original version of this document, UKAS published the following documents:

- i) Guidelines for Professional Working Practice, published in December 1993
- ii) Guidelines for Professional Working Practice – Reporting, published in April 1995
- iii) Guidelines for Professional Working Standards, published in August 1996
- iv) Guidelines for Professional Working Standards – Ultrasound, published in October 2001
- v) Guidelines for Professional Working Standards – Ultrasound Practice, published in October 2008

Citation

The contents of this document can be used with acknowledgement. When referencing this document, the following format should be used:

SoR and BMUS (2025) “Guidelines for Professional Ultrasound Practice” 9th ed., Society of Radiographers and British Medical Ultrasound Society. ISBN: 978-1-911738-25-1

Disclaimer

The Society of Radiographers and the British Medical Ultrasound Society produced this guidance document as an educational aid to inform safe practice. The recommendations within these Guidelines are based on published evidence, national guidelines, established clinical imaging techniques and best professional practice.

These SoR and BMUS Guidelines are designed to inform local protocols issued by employers, but are not intended to be inflexible or prescriptive. Therefore, the choice of imaging examination and subsequent management of all patients is ultimately a local decision based on agreed schemes of work, the clinical information provided, and the ultrasound practitioner’s professional judgement. Meaningful risk assessment should be an integral part of implementation of any policy, practice or procedure locally.