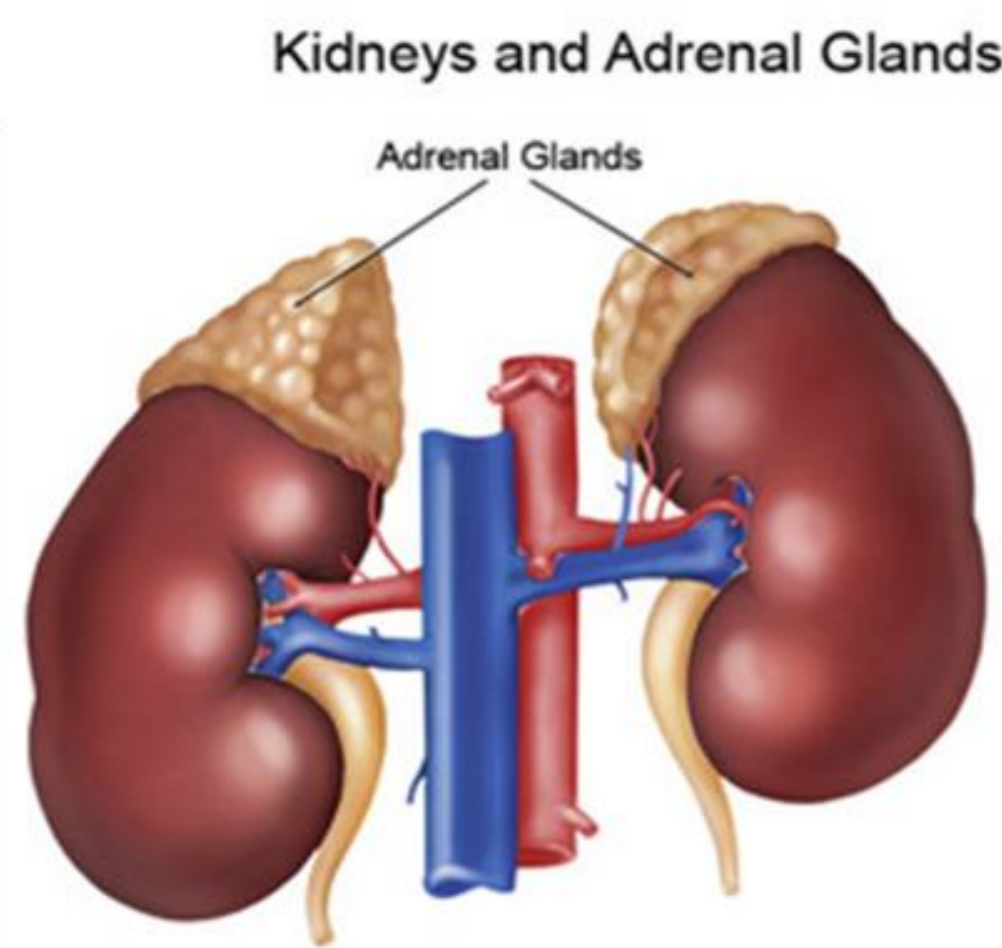


¹¹C Metomidate Imaging in Primary Aldosteronism

¹¹C Metomidate imaging is a Positron Emission Tomography (PET) scan used to assess the adrenal glands. The adrenal glands are part of the endocrine system which sit above the kidneys and excrete hormones to regulate the body's function, including blood pressure control.



www.nutritionalmuscletesting.com, 2010

¹¹C Metomidate is a positron emitting radioactive isotope, with a 20min half-life, which is absorbed by normal and abnormal adrenal tissue. The main use for ¹¹C Metomidate is to assess patients for a condition known as primary Hyperaldosteronism (PHA) or Conn's Syndrome. Conn's Syndrome patients generally present with hypertension (high blood pressure) as a result of a benign tumour (an adrenocortical adenoma) in the cortex of the adrenal gland. The adenoma secretes excess hormone known as aldosterone into the blood stream causing the body to retain salts and lose potassium. These extra salts and low potassium levels result in high blood pressure.

PHA symptoms include;

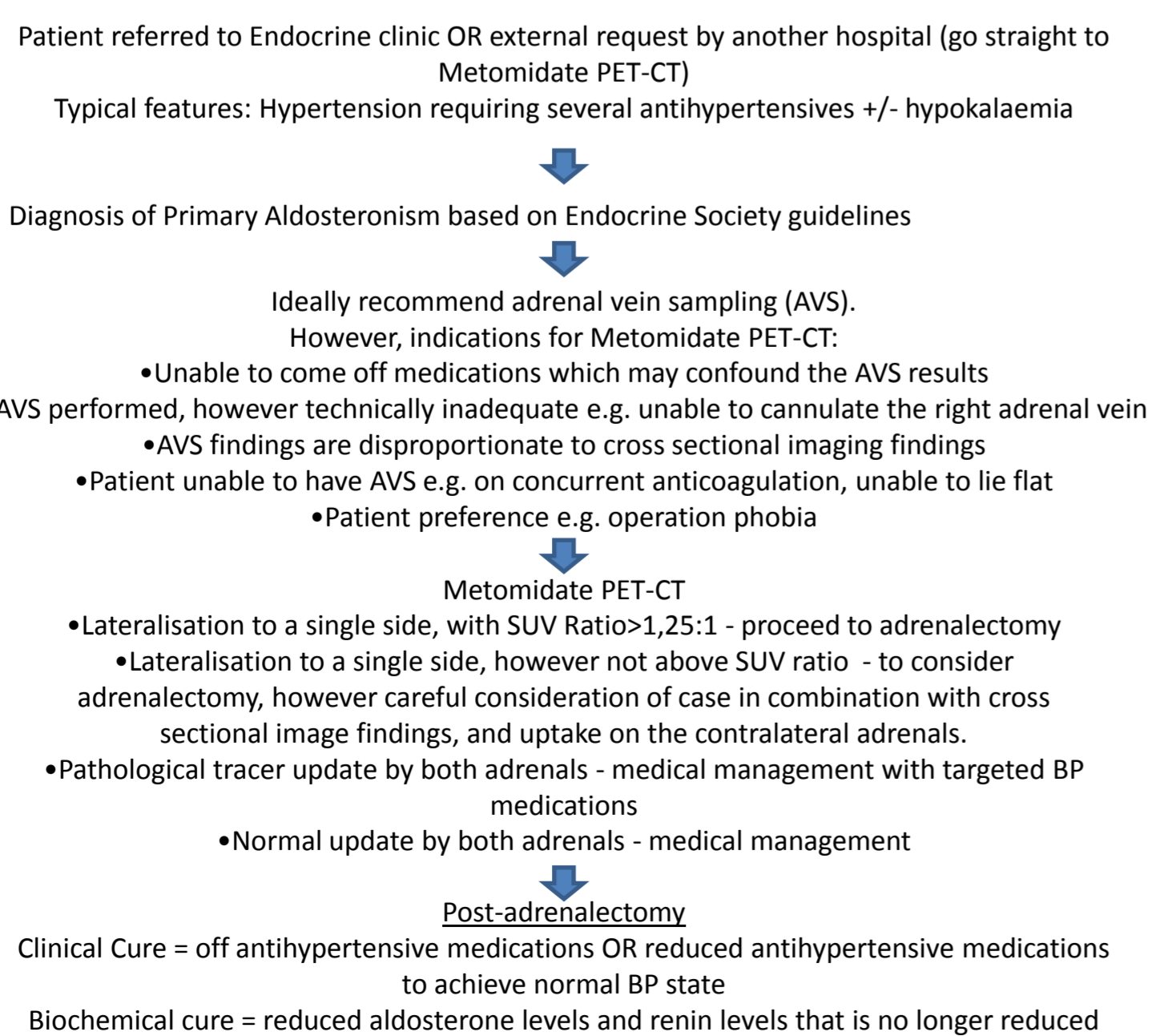
- Hypertension
- Tachycardia
- Headaches
- Muscle weakness
- Excessive thirst
- Increased frequency to urinate

If left untreated PHA can lead to heart failure and oedema of the legs and ankles. It was originally thought that PHA was responsible for around 1% of patients with hypertension, but recent data has shown that this figure is more likely 5-15%. Although PHA is difficult to diagnose, it is vital in identifying the condition as it can be curable with surgical intervention.

It is thought that 70-80% of cases of adrenocortical adenomas are the cause of PHA. Further studies have shown that bilateral idiopathic adrenal hyperplasia (IAH) also plays a significant role in the cause of primary hyperaldosteronism (Uwaifo et al, 2017).

Diagnosis

Diagnosis of PHA is generally confirmed by using a series of blood tests, diagnostic Computered Tomography (CT), adrenal venous sampling (AVS) and dexamethasone suppression testing. Currently AVS is the gold standard for diagnosing PHA, it is an invasive technique performed by a highly skilled radiologist to measure the hormone production of each adrenal gland. An adrenal gland found to be over producing aldosterone can indicate an adenoma. AVS can be inconclusive as a result of failure to access the adrenal vein, intermittent production of aldosterone or patient incompatibility. ¹¹C Metomidate imaging is a less invasive technique to help diagnosis and patient management, and has been shown as a more effective technique to AVS in identify unilateral aldosterone-producing adenomas (Powlson et al, 2014).

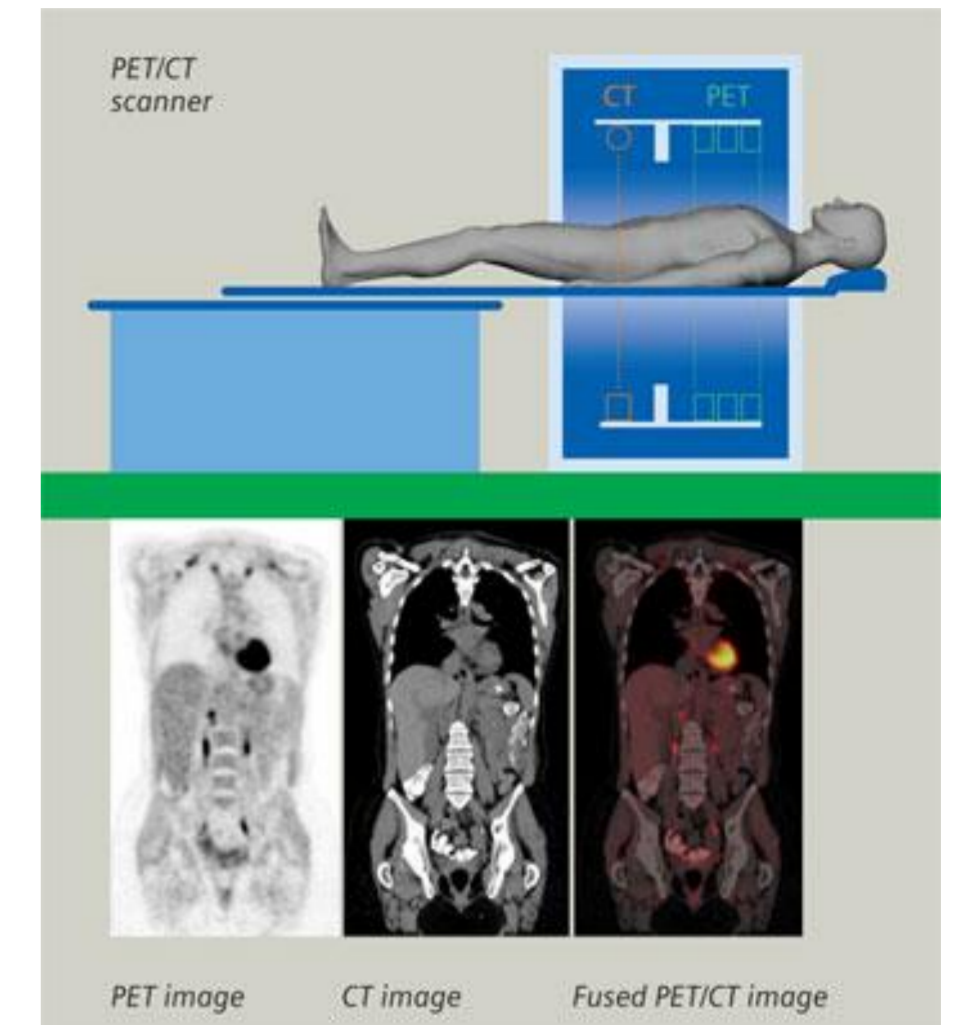


Above is the Cambridge University Hospital NHS Foundation Trust patient pathway for ¹¹C metomidate imaging. (CUH, 2020).

Patient Preparation

Patients take a steroid called Dexamethasone 3 days prior to imaging. A dosage of 0.5mg every 6 hours is given over 3 days with the last dose taken within 6 hours of the ¹¹C Metomidate imaging. The purpose of the Dexamethasone is to suppress ¹¹C Metomidate binding in normal adrenal tissue to allow any abnormal regions such as adenomas to be visualized more clearly. It also helps to improve the signal to noise ratio in the images (Burton et al, 2012).

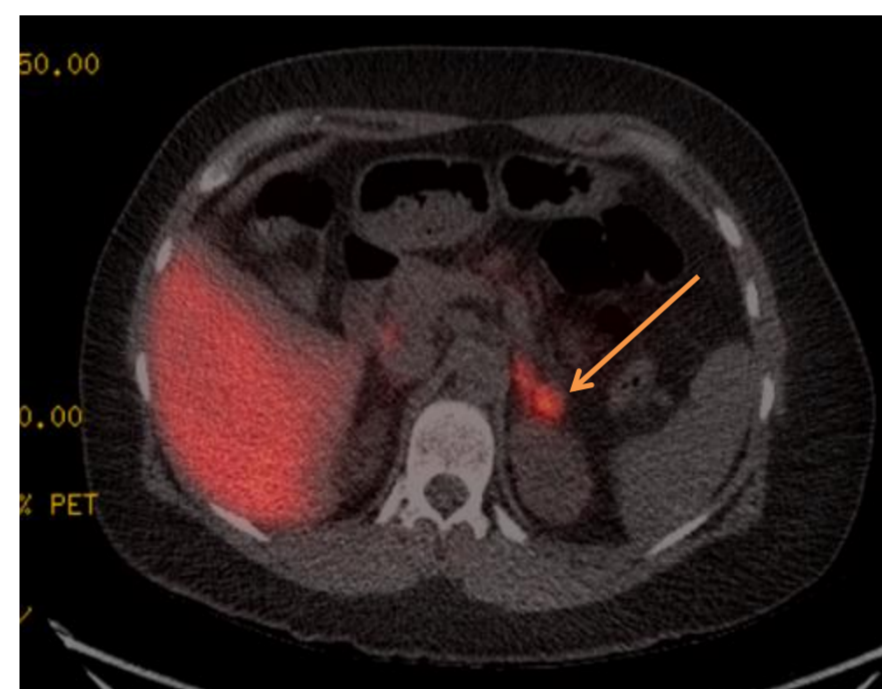
On the day of the scan patients receive an intravenous dose of ¹¹C Metomidate between 90MBq to 300MBq. After a 30min uptake time, a low dose CT scan is performed over the adrenals, followed by a PET acquisition. A 30min PET acquisition is centred over the adrenal glands and acquired whilst the patient breathes gently. Upon completion of the study, CT and PET images are fused together to aid localisation.



www.nepetimaging.com, 2001-2017

Imaging

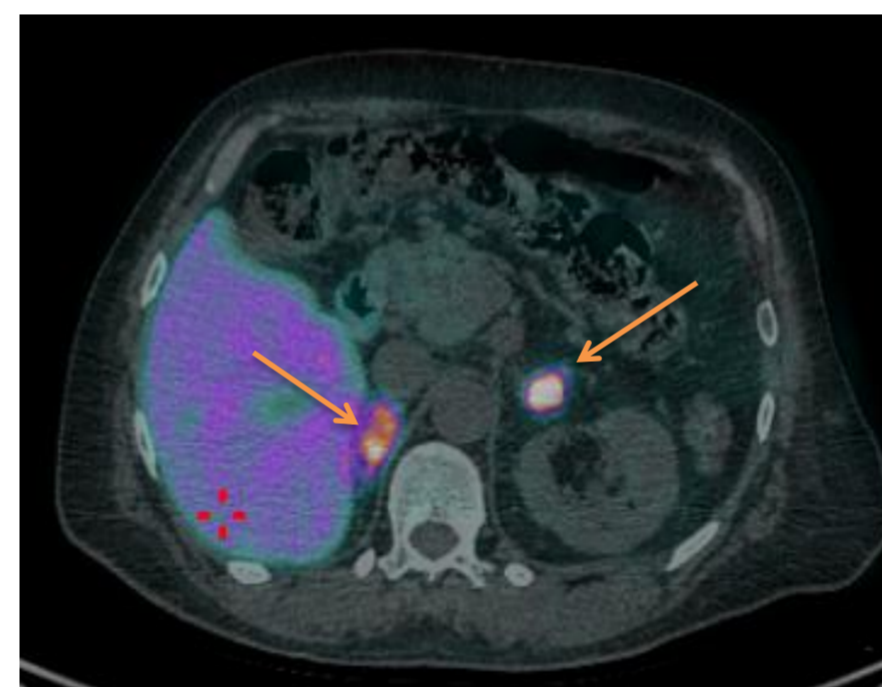
Below are some examples of positive ¹¹C Metomidate scans representing adrenal adenomas.



Case 1

Clinical Indication – Primary Aldosteronism

Diagnosis – There is increased uptake demonstrated in the left lateral limb of the left adrenal gland, representing an adenoma (identified by the orange arrow).

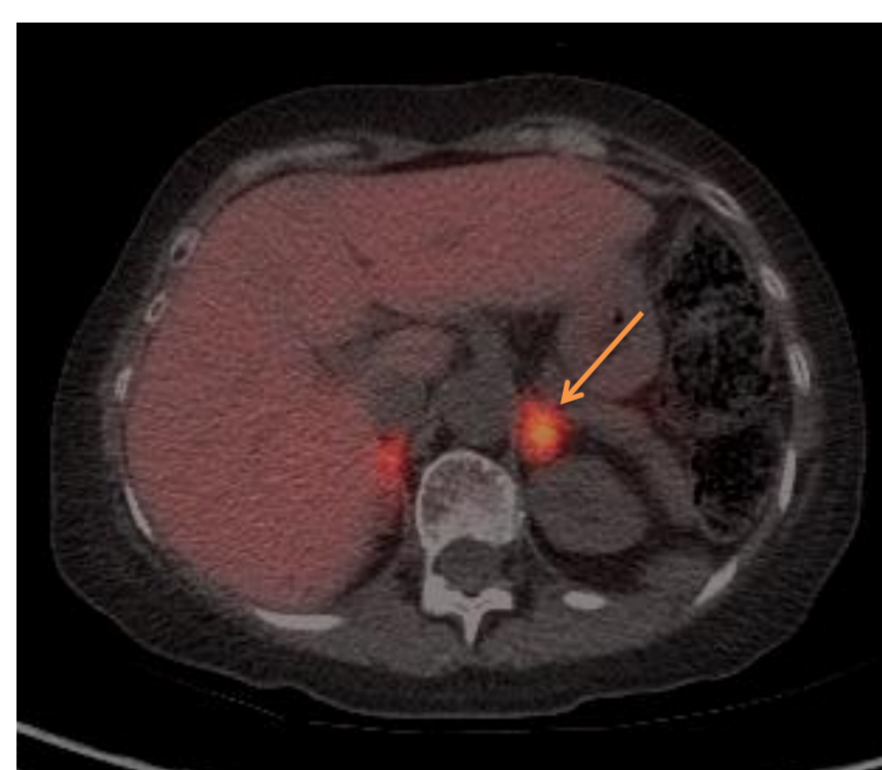


Case 2

Clinical Indication – Primary Aldosteronism

Diagnosis- Bilateral positive nodules

There are 2 intense areas of uptake seen in both the right and left adrenal glands, representing multiple nodules (identified by the orange arrows).



Case 3

Clinical Indication - Primary Aldosteronism

Diagnosis – Positive uptake seen in the left adrenal representing an adrenal adenoma (identified by the orange arrow).

Treatment

A proportion of the patients with Conn's syndrome can be cured with surgery, meaning no more requirement blood pressure medication. Other patients who do not achieve a cure following surgery could benefit from having a reduced, more stable blood pressure control or a reduction in medication.

Limitation

As ¹¹C Metomidate is a short acting tracer, this scan can only be done where there is a local cyclotron for production. As the dose of ¹¹C Metomidate tracer decreases rapidly with time, patients that arrive late may not be able to have the study done due to insufficient activity.

The production of ¹¹C Metomidate is a complex chemical process, which takes approximately 30-45min to produce, and pass quality control testing. Sometimes repeat productions may not be possible on the same day due to timings and availability.

Conclusion

Small studies have shown that ¹¹C Metomidate imaging is an useful non invasive method to diagnose and manage patients with primary aldosteronism.

References

- Thyroid, Parathyroid, Adrenal, Endocrine Surgery, The History of the Adrenal Glands, www.endocrinesurgeon.co.uk, http://www.endocrinesurgeon.co.uk/index.php/the-history-of-the-adrenal-glands [July 2017]
- Murdock, D (2010) Adrenal Glands and Stress [online] Available http://nutritionalmuscletesting.com/index.php?p=2_12 [9 August 2017]
- Burton, T, Annamalai, A, Bird, N, Gurnell, M & Brown, M. (2010) ¹¹C-metomidate Positron Emission Tomography (PET) Scanning for Conn's syndrome, Endocrine Abstracts 21 OC2.3, ISSN 1479-6848 (online)
- Uwaifo, G, Sarlis, N and Khardori, R. (2017) Primary Aldosteronism: Practical Essentials, Pathophysiology, Etiology, www.medscape.com, http://emedicine.medscape.com/article/127080-overview [July 2017]
- Powlson, A, Koulouri, O, Challis, B, Cheow, H, Koo, B, Brown, M & Gurnell, M (2014) ¹¹C-metomidate PET-CT in Primary Hyperaldosteronism: a Valuable Alternative to AVS, Endocrine Abstracts Vol 34, P365
- Senanayake, R (2020) Primary Aldosteronism Patient pathway, emailed to Thompson, K. 28/1/2020 katie.thompson@addenbrookes.nhs.uk, Cambridge University Hospital
- Burton, T, Mackenzie, I, Balan, K, Koo, B, Bird, N, Soloviev, D, Azizan, E, Aigbirho, F, Gurnell, M & Brown, M. (2012) 'Evaluation of the Sensitivity and Specificity of ¹¹C-metomidate Positron Emission Tomography (PET)-CT for Lateralizing Aldosterone Secretion by Conn's Adenoma', The Journal of Clinical Endocrinology & Metabolism, Vol 97, 01 January 2012, pp 100-109
- PET/CT Advanced Imaging (2001-2017), www.nepetimaging.com, http://www.nepetimaging.com/pet-ct.html, [July 2017]